

NEWS & TRENDS IN ORTHODONTICS

Apr. 1 Vol. 14 2009

Using the Damon System to Treat Crossbite with Root Resorption in
Pseudo CI III Patient

Dr. John Lin

The Secrets of Excellent Finishing

Tips from Dr. Tom Pitts

ABO Case Report: Anterior Open Bite

Dr. Eugene W. Roberts



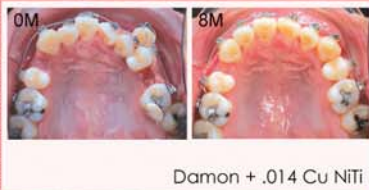From left to right: Dr. Dwight Damon, Dr. Chris Chang, Dr. Tom Pitts, Mr. Dan Even, Dr. Sabrina Huang, Ms. Megan Shao, Dr. Billy Su at the 2009 Damon Forum

快速入門矯正・高效學習法

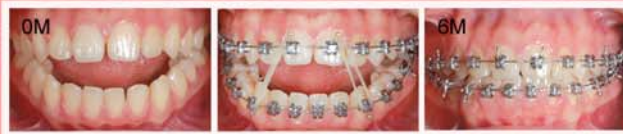學會開始做矯正需多久？

42小時讓您入門矯正。本課程採高效學習法及高效矯正簡報法 - Keynote，在舒適、輕鬆的環境下，學會簡單有效的矯正方法，教室與診間結合，讓您現學現用，立即熟悉各種習得的技巧，而不需太多課後複習。全程以 In-Office Training 方式，用病例帶動分析、診斷，治療計畫與療程技巧，每一步驟皆以圖片及影片教學，讓您很難錯過任何環節，更沒有聽不清楚或無法理解的可能。為提高課後自我學習及臨床印證之效率，另備有教學電子檔，供學員家中研習。我們的終極目標是：用最短時間、最輕鬆的方式，讓每位學員

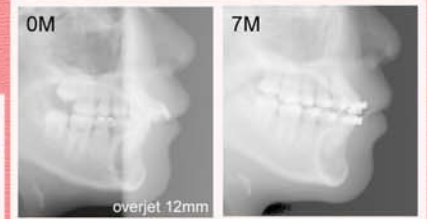熱愛矯正學・熱愛學矯正



Damon + .014 Cu NiTi



Damon + Early Light Short Elastic



Damon + Bite Turbo + Early Light Short Elastic

2009.....課程.時間

矯正基礎

近期開課

	新竹 (二)	高雄 (四)	LECTURE
1	05/19/09	05/14/09	理想入門病例 + Damon黏著
2	05/26	05/21	快速矯正療程四部曲
3	06/02	06/04	簡捷有效的錨定系統
4	06/16	06/18	不拔牙與拔牙分析
5	06/23	06/25	Damon診斷流程及微調
6	07/07	07/09	完工檢測及報告示範
7	07/14	07/16	維持及復發；病例示範
8	07/28	07/30	矯正力學及診斷分析 (1)
9	08/04	08/06	微力秘訣及診斷分析 (2)
10	08/11	08/13	病例示範及診斷分析 (3)
11	08/25	08/27	病例示範及診斷分析 (4)

LAB

Bonding (D3MX) + BT
Ceph + Photo
Damon + OrthoBoneScrew I
Damon + OrthoBoneScrew II
Finish Bending
Fixed Retainer (FR)
Presentation Demo
DDX + Case Reports I
DDX + Case Reports II
DDX + Case Reports III
DDX + Case Reports IV

矯正進階

• 快速排除臨床疑點，課程中亦訓練每位學員善用 Keynote 以病例討論為主軸，培養學員如何正確診斷及

	新竹 (二)	高雄 (四)
1	09/23/08	09/25/08
2	10/07	10/09
3	10/21	10/23
4	11/04	11/06
5	11/18	11/20
6	12/02	12/04
7	12/23	12/25
8	01/06/09	04/09/09
9	03/10	04/23
10	03/31	05/14
11	04/07	05/21

診所實習課表

(矯正基礎班)

1. Initial Consultation
2. Initial Record (Pano + Ceph + TMD + Photo + Model)
3. Final Consultation & Tx. Plan
4. Banding & Bonding (黏瓷牙、金牙、智齒、埋伏牙、舌側維持器)
5. Archwire Adjustment & Bending
6. Retie & Power Chain & Clinical Tips
7. De-banding & De-bonding
8. Retainer (Removable & Fixed)
9. OrthoBoneScrew Implantation
10. Assistant Training & Patient Instrument Selection
11. Orthodontic Material & Instrument Selection
12. Practice Management & Office Design

矯正植體

• 矯正植體的操作時機、植床跟診及實作示範。
法與實習、個案討論、臨

近期開課

新竹 (五)
4/10/09
6/12/09

NEW 精修班 (Finishing course)

• 協助每位學員了解由古典到現代之文獻，並進而變成易達到的目標。
應用於實際病例，讓精緻完工 (Excellent Finishing)

近期開課

新竹 (二)
1 05/12/09
2 06/09
3 07/21
4 08/18
5 09/08
6 10/13
7 11/10
8 12/15
9 01/12/10
10 02/09
11 03/09

課程.資訊

課程項目	時段	上課地點
矯正基礎	新竹/高雄 【課程】09:00 - 12:00 【實習】另外安排	台北 恆逸資訊中心-畢卡索廳 / 台北市復興北路99號12F (捷運南京東路站)
矯正進階	新竹【課程】09:00 - 12:00 高雄【課程】14:00 - 17:00	新竹 金牛頓藝術科技公司 / 新竹市建中一路25號2F
矯正植體 (含中、晚餐)	新竹【課程】09:00 - 12:00 【實習】13:30 - 20:00	高雄 科學工藝博物館S104教室 / 高雄市三民區九如一路720號
精修班	新竹【課程】09:00 - 12:00	
International workshop	新竹【課程】All Day	

International workshop

• Keynote & management
OrthoBoneScrew
& Damon

06/29 ~ 07/02/09

"Treat Every Case to Meet the Board's Standards"

It was Dr. Tom Pitts' farewell message in the 2009 Damon Forum. One month earlier, Dr. Roberto Justus, president of World Federal of Orthodontists, made the same statement in his keynote address at the annual conference for Taiwan Association of Orthodontists. That message was echoed by Dr. Vincent Kokich on March 6, 2009 for his three-day course in Taipei. With regards to excellent finishing, these three masters think the same: "Treat every case to meet the Board's standards!"

What makes this goal so difficult to achieve? What are the Board's standards? Back in 1993, nine orthodontic giants started to put together an Objective Grading System for orthodontists to evaluate their finishing work. After 15 years of field tests, this OGS has become the standards of the American Board of Orthodontics. The "deduction" score should be below 26 to claim a satisfactory result. To reach this score is not particularly hard for a specially selected case. However, treating every case to meet these standards is indeed a huge challenge. First, you need to know exactly how to get there. Then, you have to establish a system in your office to execute the procedures. Finally, you are required to re-evaluate every case on a regular basis. Once you go through these three steps, you have already raised your standard of care. In order to make our readers familiar with this system, we have invited Dr. Eugene W. Roberts, a true master in the ABO grading system, to edit two ABO case reports in this issue. It's a basic tutorial on the ABO case study, all in one lesson.

One should never stop learning and adapting in this ever-changing world. If you limit yourself to what you know and what you are comfortable with, you will grow increasingly frustrated with your surrounding as you age. Right now this system may be new to you, but with practice you will soon become one of those experts who are really familiar with the system. You have nothing to lose. Let's take this journey to excellence together and strive to treat every case to meet the Board's standards.

Chris HN Chang, DDS, PhD, Publisher



Contributors (from left to right) :
Yi Yang Su, Shih Jaw Tsai, Chih Yuan Wu, Hao Yi Hsiao, Michael Ho, Tom Pitts, Chris HN Chang, Yu Lin Hsu, Chuan Wei Su, Chiung Hua Huang, Ksiao Long Wang, Shu Fen Kao, Yu Lung Lee, Chien Kang Chen, Shou Xin Kuang

03 Editorial

LIVE FROM THE MASTER

- 04 Using the Damon System to Treat Crossbite with Root Resorption in Pseudo C1 III Patient

FEATURE

- 06 Dr. Tom Pitts' Secrets of Excellent Finishing
24 Orthodontic Treatment of a High-Angle Case with Gummy Smile
30 Dr. Vincent Kokich on Excellent Finishing
34 Dr. Vincent Kokich on Impacted Maxillary Canines
38 Dr. Charles Burstone on Biomechanics of TAD

ABO CASE REPORT

- 42 Impinging Overbite and Large Overjet
50 Treating Anterior Open Bite Case with Early Light Short Elastics

PERSPECTIVES

- 58 Dr. Roberto Justus on Finishing-The Standard of American Board of Orthodontics

VOICES FROM THE ORTHODONTIC WORLD

- 60 Feedback on Keynote Workshop



Consultant
Dr. Eugene W. Roberts



Contributors (from left to right) :
Dr. Hong Po Chang, Consultant
Dr. Ming Guey Tseng, Consultant
Dr. John Lin, Consultant
Dr. Frank Chang, Consultant
Dr. Johnny Liao, Consultant
Dr. Chris Chang, Publisher



Consultant
Dr. Larry White



Guest Editor
Dr. Rungsi Thavarungkul



Editors (from left to right) :
Tzu Han Huang, Associate Editor
Grace Chiu, Associate Editor
Dennis Hsiao, Chief Editor
Billy Su, Associate Editor

03

Using the Damon System to Treat Crossbite with Root Resorption in Pseudo CI III Patient

Clinically, root resorption happens when orthodontic treatment takes too long, or using heavy force, and sometimes traumatic injury, idiopathic pattern and heredity factor play important roles. Whenever it happens during orthodontic treatment, it bothers orthodontist a lot, can we treat the root resorbed malocclusion, how is the prognosis?

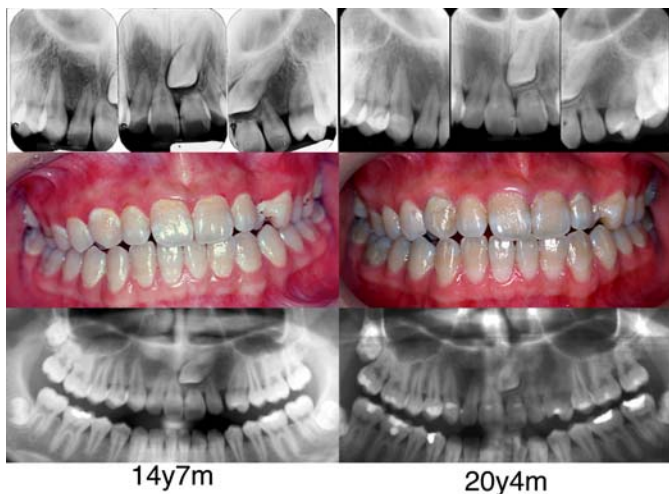
Hopefully through the discussion of the following two cases we can have some new ideas about prognosis and treatment plan of malocclusion with root resorption.

Case 1

A 14y7m female patient presented with short upper incisor roots. The roots of left upper central and lateral incisors were severely resorbed by the compression of the ectopically erupted left upper canine. Esthetically and functionally the patient felt no problem, so no any orthodontic treatment was done.

When at 20y4m (5 years and 9 months later), the patient came back for check up again, the resorbed condition of left upper central and lateral incisors roots remained the same as the first visit.

Case 1



Case 2

A 28y11m female patient had severe anterior crossbite and Class I buccal segment was diagnosed as Pseudo Class III malocclusion. She suffered mild periodontitis, and was referred to periodontist for conservative scaling and root planing treatment. After 8 months periodontal treatment, the orthodontic treatment started at age 29y7m.

At initial bonding, the .013" CuNiTi wire was engaged into the Damon brackets of all the teeth, including the severe crossbite teeth of upper incisors at age 29y7m. About 7 months later at age 30y2m, the anterior crossbite and severe crowding were all corrected with good alignment of the teeth and enough overbite and overjet without using Class III elastics and open coil spring. The anterior crossbite was purely corrected by the advancement and expansion of the upper dentition.

At age 30y9m, stripping of lower anterior teeth to reduce the black triangle were done, and powerchain under the brackets was used to close the extra spaces, which was created after stripping of the proximal surface of lower anterior teeth.

The x-ray of apical and panorex showed no further resorption of the upper incisors, even though the severe crossbite and crowded anterior teeth were corrected to almost normal anterior occlusion.

What we can learn from these cases:

1. Severe root resorption situation may be looks terrible, but if without any additional traumatic force, the severely resorbed roots can be retained in the mouth for a long time. (Left upper incisors of case 1).
2. Damon system using the very small diameter CuNiTi wire in the large lumen bracket, offers the wire a lot of space to play, which creates very light and gentle continuous force and it is possible to correct the severe anterior crossbite and severely root resorbed right upper central incisor

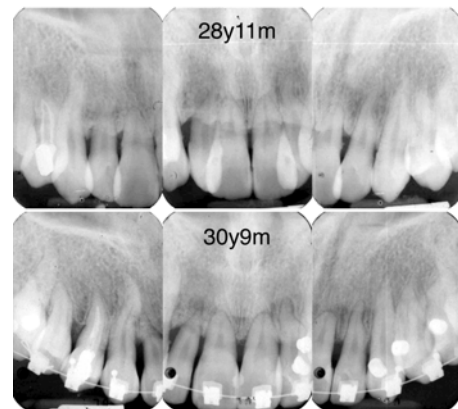


- (Case 2) without further root resorption. For conventional edgewise, the crossbite will be very difficult to correct without using heavy force and open coil spring. For sure, this kind of heavy force will make the root resorption more severe, and even cause lost of the teeth.
3. Glass ionomer build-up on the molar teeth can disocclude the anterior teeth very efficiently and help correction of the anterior crossbite.

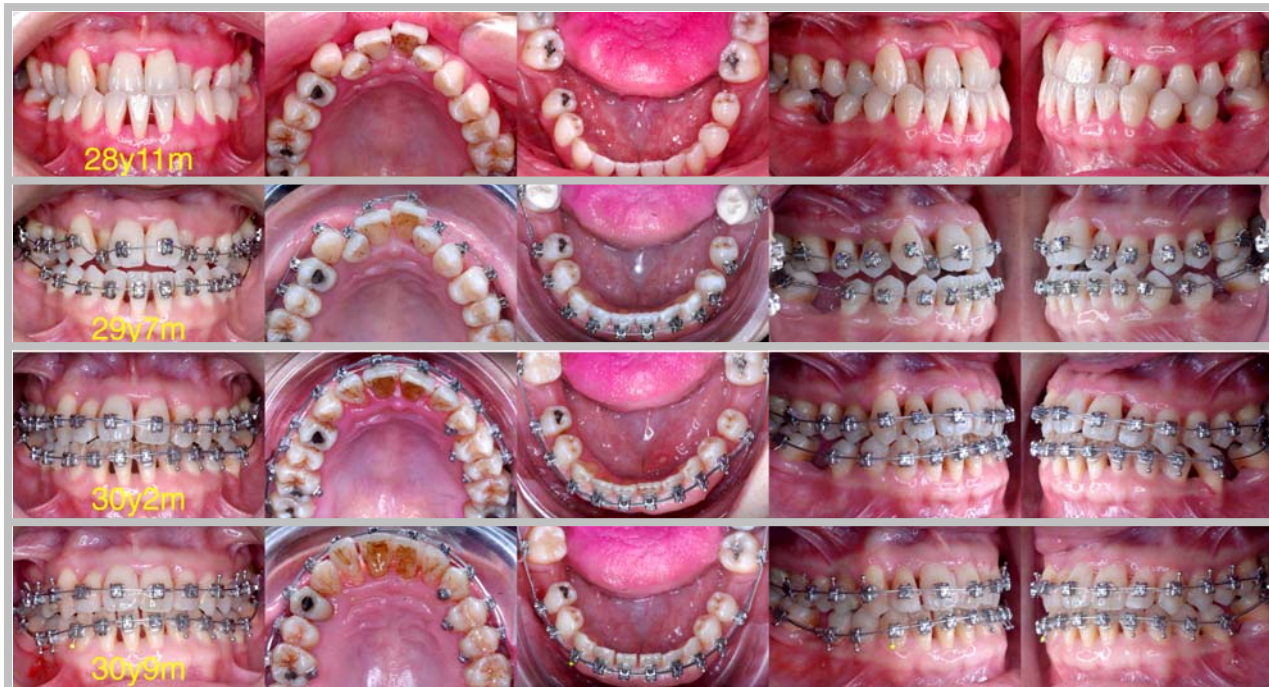Conclusions:

1. Severe root resorption of upper incisors in case 1 is due to ectopic eruption of upper canine. Severe root resorption of upper lateral incisors in case 2 is an idiopathic situation or due to traumatic injury without any treatment before. Front teeth, even with severe root resorption and extremely short roots, can still maintain in the mouth for a long time.

2. The Damon light force system is a very useful system for correcting anterior crossbite and severe crowding without using open coil spring or Class III elastics in Pseudo Class III case.
3. The Damon light force system can correct the severe root-resorbed teeth without further resorption, which is due to its very light and continuous force application.



Case 2





Dr. Tom Pitts' Secrets of Excellent Finishing

We were delighted to have Dr. Tom Pitts back to Taiwan again on November 15, 2008. In last year's Damon Forum Dr. Pitts had surprised us with many wonders. This year he has brought more secrets to share with Taiwan's audiences. Below is an executive summary of his lecture.

Contemporary orthodontic treatment has been changed. Dr. Pitts stressed "Contemporary" because we are now doing things what we cannot imagine years ago. We never thought that we would be creating spaces, creating arch width, making the beautiful smile without extractions. We really have been so fortunate to witness such innovations in orthodontics, particularly with Damon system that has evolved in the last ten years. Now with the Damon system we can do so much more !

Today, we are going to cover the followings :

- **New Esthetic Model**
- Getting The **Best Esthetics possible** from Passive Self-Ligation
- The Art of **Arch Development, Proper Torque, and Smile Arc Protection**
- A Close look at **Bracket Placement, Working Arch Wires and "Finishing"**
- Revolutionary **Early Elastics**
- **Case Reports**
- **Retention**

● **New Esthetic Model**

In Asia and America, facial standards have been changed over the last twenty years. In a study done by Dr. Turley in UCLA shows that the ideal male profile has changed significantly with time. And there was a trend of increasing lip projection, lip curl and vermillion display. That's a big thing ! Actually, in Asian Americans, there is also a more progress to a full lip than there was years ago (Fig 1).

Dr. Sarver developed a classification of appearance and esthetics, and divided into three parts : Macroesthetics — the face, Miniesthetics — the mouth, particularly the smile framework, and Microesthetics — the teeth and gingival tissue (Fig 2). He developed this classification to be able to get the highest and best facial esthetics in orthodontics combined with orthognathic surgery. Dr. Sarver had about 60% of cases underwent orthognathic surgery, but we can use this classification to assess our cases using Damon system. With this classification, we can assess how we can enhance the facial profile, how we can predictably increase the incisor display, how we can eliminate the gummy smile, and how we can increase the transverse smile with either RPE or with

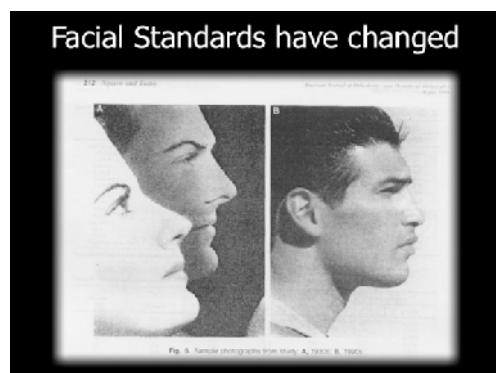


Fig 1. Facial standards have changed

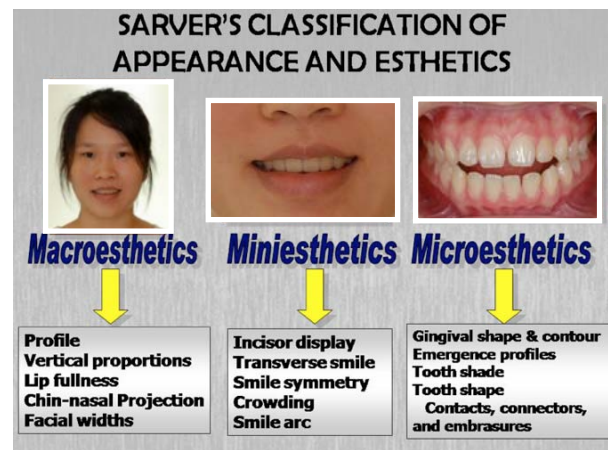


Fig 2. Sarver's classification

Dr. Sabrina Huang
 Heavenly Smile Dental Clinic
 Clinical Consultant, National Cheng Kung University Hospital
 Department of Orthodontics
 Lecturer of Beethoven Orthodontic Course



surgical assisted RPE. But now, what we can do with the transverse is amazing !! It is not just bigger widths, but also change of the arch forms and shapes. Most importantly, for many years we were guilty of flattening the smile arc rather than follow the lower lip. Now, we know how to change our bonding position to enhance the smile arc. As for Microesthetic, we can look at the gingival shape and contour, the proportionality of width and height of incisors, and look at all the details we need to finish cases.

Here is a huge paradigm shift now, not because of surgery, but the Damon system ! We not only pursue beautiful esthetic functioning occlusion, we are also looking for enhanced facial esthetics — the highest and the best !! Thus, there is more to finishing than occlusion, function, and marginal ridges, even though they are critically important !! In the past we compromised esthetics for functional occlusion. Today, we don't want to compromise either one for the other, and we don't have to. Now, let's see how to put it all together — to enhance the beauty of the smile and the face and still obtain a beautiful finished occlusion with Damon appliance.

● Best Esthetics Possible

How can we achieve “ Best Esthetics Possible ” ? What Dr. Pitts attempts to do in his clinic is to “keep the profile as full as possible”. He never wants to sacrifice the upper lip and move the upper lip back to the chin or vice versa. Lip fullness and vermillion curl are very important. That's why he loves Asian profiles in general. Because their lips are so nicely shaped, and there are a nice vermillion curl and vermillion display. Whenever he treats Asian Americans, he wants to enhance that and always can get most beautiful results. Vertical proportion is also very important. Because through vertical control, we can maintain smile arc and enamel display (Fig 3). We can even increase enamel display by changing the vertical dimension.

In the past we usually sacrificed beautiful faces by setting up Class II mechanics to ensure maximum anchorage to retract upper anterior teeth to treat Class II malocclusion. In Caucasian, increasing dento-skeletal volume could be the best face lift !! So what we are trying to do is not to compromise the nasolabial angle, but to keep it and maintain the lip curl . Don't sacrifice the face to the occlusion !! Extracting bicuspids in a Class II

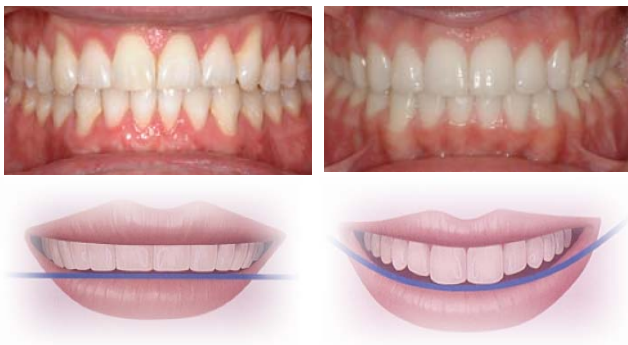

Fig 3. The smile left sided is not a good esthetic response. Because the incisors are so flat to become a “Smile line” rather than a “Smile arc” (right sided).

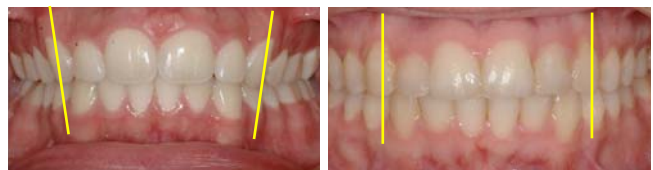

Fig 4. With the retroclined canine (about -9°), the arch width will not be able to develop. This will lead to unattractive buccal corridors (left). The ideal canine torque should be uprighted. The best position would be canine axis perpendicular to the incisal plane (right).

FH line

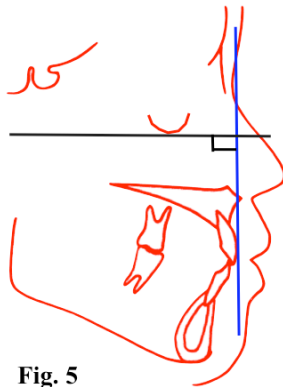


Fig. 5

malocclusion will devastate the face. Maintain or enhance incisor display, transverse smile dimension (arch form and arch width), resting lip support and smile arc is very important. One of the most important things in miniesthetics is “torquing”. Incisor torque is important to smile arc. People hate procumbent incisors. If we over-torqued the incisors, the smile arc will become flat. Canine torque is also very important. Keep canine upright will make the transition to premolar more gentle (Fig 4). **Don't over-torque the upper incisors.** If we wish to analyze the most esthetic looking incisors in the frontal view, we should use a lateral head film. According to a study done by Dr. Eastham, if we draw a line tangent to labial surface of incisor crown, it will be perpendicular to the FH plane (Fig 5). Originally, the definition of FH plane is the line

connected by Po-Or. Since “porion” is hard to define on the lateral head film, Dr. Pitts uses top of the condyle as a substitution. Remember, don't procline the upper incisors as well as canines !!

Again, speaking of Asian Americans, use this passive self-ligating brackets without extractions can achieve more full profile and good lip support. Today, the new concepts of orthodontics in Asia would be :

1. Also, a big push for **beauty with the Damon system**.
2. More **full profile** is desirable for Asian Americans today than just a few years ago.
3. **Wider arches, smile arc, enamel display** are becoming more important.
4. **Less extractions** because of arch development.
5. More **OrthoBoneScrews** used in Taiwan and Korea can also save the bicusps to ensure full profile .

On deep bite issues we can do a lot more today by increasing the lower facial height, using proper torque brackets of upper incisors, increasing the enamel display, and making smile arc consonant with the lower lip. These make a huge difference in the beauty of the cases. So, it is not just the Damon brackets but how you use it !!



● Arch Development, Proper Torque, and Smile Arc Protection

Arch development is a major factor to more impressive mid-facial beauty and non-extraction. Here, Dr. Pitts shared with us a case of bilateral lingual cross-bite (Fig 6). This patient suffered from bilateral X-bite because of low tongue position. Dr. Pitts decided to treat this patient with Damon appliance rather than RPE. He bonded every teeth and put bite turbos on to disarticulate the lingually displaced upper lateral incisors and started with .013 NiTi. In the third appointment, Dr. Pitts progressed into .016 NiTi to upper 1st molars (not 2nd molars), and went to 16x25 NiTi to the 2nd molars in the lower arch. And then, the patient disappeared for 3 years !! When the patient came back 3 years later, even without wire going through the 2nd molar, lingual X-bite on the left side was corrected including the 2nd molar. X-bite over right side was not totally corrected because the patient usually sleeps over that side. So, in order to let the system “work”, we need to change our way of thinking !! Force level is extremely important to arch development, and with very light forces, tongue seems to come to a higher posture naturally.

Dr. Hisham Badawi developed a test machine to test the force levels and force vectors of each tooth in active self-ligating / active tie-in system and passive self-ligating

system. In crowded lower anterior area, if we aligned the teeth by active self-ligating system, even with only .014 Copper NiTi, the force vectors were all forward on the anteriors. That's why we have to extract!! But with passive self-ligating system, we can see a buccal displaced force vector on 1st premolar area. That allowed us to have lateral development rather than incisor flaring with the very first wire in the Damon system (Fig. 7).

● Mastery of Damon Finishing

When talking to Damon and contemporary finishing, Dr. Pitts develops it into 4 steps.

1. Learning how to use the appliance to fit the teeth together beautifully.
2. Learning how to create results with enhanced (Highest and Best) Facial and Smile esthetics.
3. Adding efficiency to the process without diminishing the quality. Including the followings :
 - ➔ Appliance placement / custom torque
 - ➔ Letting the system work
 - ➔ Early light short elastics
 - ➔ Finishing elastics
 - ➔ Cuspal contouring
4. Learning how to retain the results.

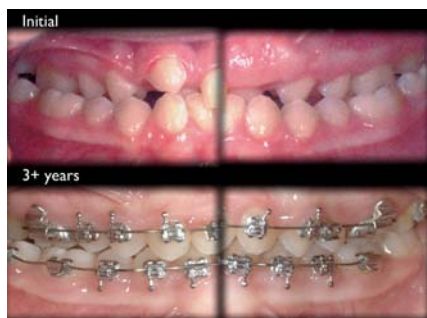


Fig 6. Note: the lingual crossbite of #15 has been corrected without archwires.

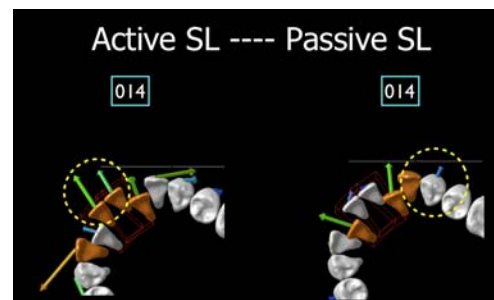

Fig 7. Dr. Hisham Badawi's force study

Excellence is a “process”. Dr. Pitts is treating cases better than just he was a couple years ago. Some orthodontists can fit the teeth together, but not maximize the esthetics. Some get the beautiful faces but their inclination, marginal ridges, and occlusion are not excellent. What we have to do is to treat patients with not only esthetic functional occlusion, but also with esthetic facial balance.

Dr. Pitts stressed that “vertical” is important to esthetics. The 2nd step in mastering the highest and best Facial and Smile Esthetics involves control of vertical dimension. We have to learn how to intrude and extrude the posterior teeth without causing harm to the smile arc. We should know how to deal with the lower facial height and the power of “disarticulation” (Bite turbos).

● Bracket Placement, Working Arch Wires and “Finishing”

Bracket position is the 1st key to finishing. The ideal position criterion involves : (Fig 8, 9)

- Smile Arc
- Mutually Protected Occlusion
- Marginal Ridges and Contacts
- Symmetry
- Transition from the Anteriors to the Buccal Segments/
Occlusion of Buccal Cusps

• Torque Control

Dr. Pitts have been direct bonding for 40 years. “ Bonding can make us or Break us ! ” Dr. Pitts evaluated many of his cases and realized that the most beautiful cases were the ones of which the occlusal edge of bracket pads reached the level of contact points. Thus, he has developed the gingival bracketing position. If you use indirect bonding, you still need to study “positioning”. The more we study bracket positioning, the better and quicker our finishing is. We also need to excel “repositioning” brackets during treatment. Here we list the steps of “Precision bonding” :

1. Incisal plane is quite important! The frontal smile photograph may not be so accurate. Before bonding, have the patient stand up and smile, look at the patient directly. Observe if there is any occlusal plane canting, arch width and shape, and most importantly the smile arc.
2. Use pencil to draw the contact point line of posterior teeth on the models. Observe the crown morphology and axis carefully. When Dr. Pitts starts bonding, he always has Pano, photos (esp. frontal smile photo) and models by the chairside.
3. Have two assistants prepare prior to bonding. Preload molar tubes with resin. Apply bonding agent on tube base (tube only), air dry, then apply resin. Covered the tubes (with resin) with metal cups to protect resin from curing by

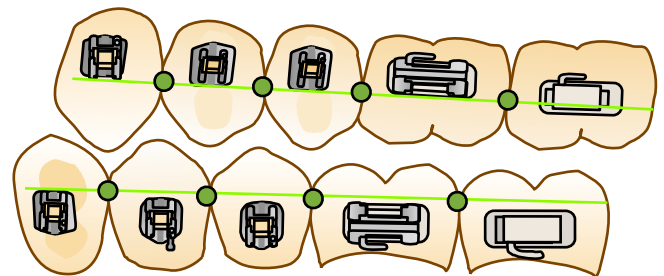
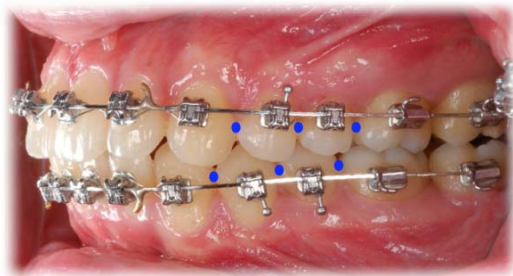


Fig 8. Bonding position of lower canine and bicuspid : occlusal pad of the brackets should be “below” the contact point line. 1st molar should be right on the contact point line with the 2nd molar a little bit “gingival” than the 1st molar. Bonding position of upper canine and bicuspid : occlusal pad of the brackets should be “right on” the contact point line. The end molar should be a little bit “occlusal” than the 1st molar.

ambient light. No antisialogogue, no cheek retractors, only use long (7 inches) cotton rolls. Use a large front surface mirror plus magnifying loupes.

4. Reshape teeth with football diamond bur, polish with white stone, then black rubber point. [Dr. Pitts reshapes 99% of Canines prior to bonding](#). This is particularly true among Asians because the Asians have many variations on their teeth, such as lingual ridges of upper incisors, uneven labial surfaces of upper lateral incisors which often need to be reshaped. Dr. Pitts does tell the patients and the parents that there is no way he can straighten their teeth and do a great job without recontouring enamel !!
5. Start with lower arch, and then go to upper arch.
6. Use rubber cup with pumice powder to clean the teeth. Once we clean the teeth up, don't let the cheeks touch the teeth again. Use long cotton roll to isolate the teeth from cheek, and half the cotton roll to isolate the tongue. Start with the R't lower 2nd molar. Bond the occlusal pad of bracket just below the contact point (buccal segment). Use large front mirror to observe the tooth long axis. End up R't side on canine then shift to L't side. When we look at the long axis of the lower incisors from side of the patient, it will appear more mesial than if seen from the labial. So, bond the [lateral incisors](#) as well as [canines](#)

[mesial](#) to the long axis. Press the bracket base firmly and curing. When you want to overcome the deep bite, bond the lower incisors relatively incisal.

7. Before we start bonding upper arch, put utility wax over labio-gingival surfaces of lower anterior brackets to protect the lower lip. Dr. Pitts puts the 2nd molar more occlusal than the 1st molar. Use a small mirror to observe the buccal groove from occlusal view. Bond 1st molar and premolars with occlusal edges of bracket pads right on the contact point. Use a large mirror with loupes to observe the central grooves and long axis of premolars (Fig 10). With the incisors, [put the mesial surface of bracket to parallel the mesial surface of the incisor](#). As for central incisors, not only have to make sure they are on the same height, we also have to make sure that they are in the same distance to the crown mesial side. Canines also have to be on the same height to prevent cant of the occlusal plane. [Keep as symmetrical as possible!!](#) Finally, add bite turbos on palatal side of the centrals (or posteriors) and do some occlusal adjustment. Then insert the wire.

Let's talk about Working wire principles :

- Every working wire has [adjustments](#) at the very first appointment they are inserted including 1st, 2nd, and 3rd orders.

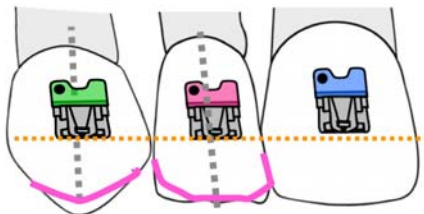


Fig 9. Bonding position

- Use football diamond bur to recontour the unworn cuspid tips or irregular attrition
- Place upper anteriors followed by Smile arc. Canine and lateral incisors will be at the same height, and place the central incisors a little bit gingivally.
- Place lateral incisors and canines “mesial” to crown long axis.

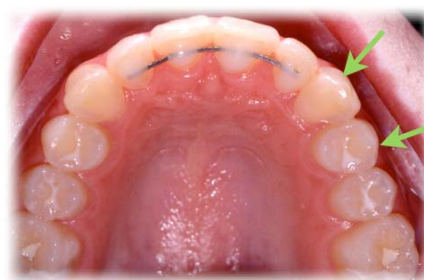

Fig 10. Common bonding errors of upper arch :

- Too distal on canines
- Too mesial on 1st premolar (Particularly the left side)

- Use stainless steel or TMA.
- Every working wire has Posts or Loops distal to the laterals on either steel or TMA wires . With the posts / loops, you'll never lose your way. You can always know which side of the arch wire is up and easy to coordinate and gain symmetry.
- They must be perfectly symmetrical and coordinated. Coordination means that curvature of Maxillary and Mandibular 3-3 is in the same. If we need more posterior width, we can expand the SS wires posteriorly.

As for when to use what working wires ? Dr. Pitts uses 19X25 SS on upper and 16X25 SS on lower mostly. In open bite or Class III cases, he uses 19X25 TMA or 17X25 TMA. In Class II or extraction cases, always use SS as working wire. Again, don't over torque the upper anteriors. Dr. Pitts does adjust his working wires before first insertion. (Why wasting 10 to 11 weeks?) To prevent opening unwanted spaces during arch development, use K modules or .008 ligature wire to tie back.

● Early Light Short Elastics

The advantages of early light short elastics are as following : (Fig. 10A-10H)

- Controlling vertical dimension in either deep bite or open bite cases in early stage of treatment.
- Controlling AP correction in either Class II or Class III cases in early stage of treatment by using 2 oz early light short elastics. Keep it short to reduce the side effect of horizontal pull.
- Influencing higher tongue posture.
- Enhancing increased arch width earlier with light cross elastics. And with such a gentle force, we don't get too much tipping.

- Increased efficiency.
- Doesn't hurt the patient because of the light force.

By simply combining early light short elastics and bite turbos, we can selectively intrude or extrude certain teeth to control the vertical dimension without harming the smile arc. Such results will never come out with reversed curve wires. That's why Dr. Pitts never uses a reversed curve wire on upper, because he doesn't have to.

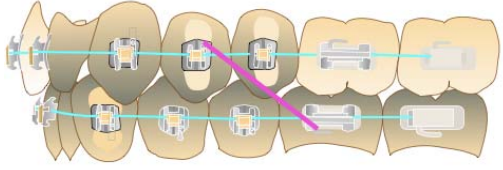
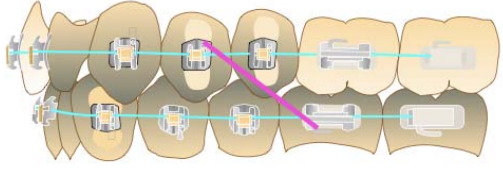
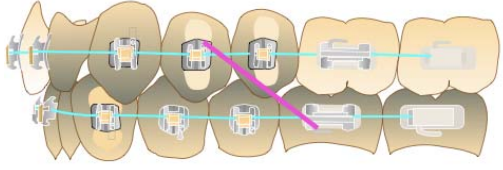
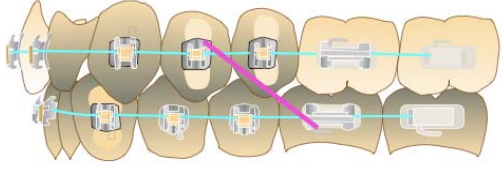
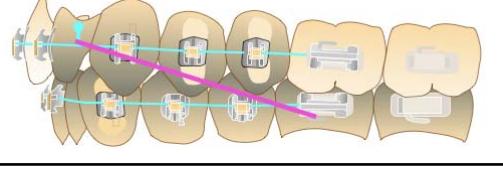
Always consider vertical and AP problems simultaneously!! In deep bite cases, add bite turbos anteriorly and use elastics to extrude the posteriors. In open bite cases, add bite turbos posteriorly and use elastics to erupt the anteriors. To make the early elastics more efficient, always think about "disarticulation"!

Remember, in deep bite or Class II cases, "Keep the elastics distally" to facilitate posterior extrusion. As for open bite or Class III cases, "Keep the elastics anteriorly" to facilitate anterior extrusion. And to maintain the treatment results, we have to "overcorrect" the Open bite cases into a little bit deep bite. For deep bite cases, we have to "overcorrect" the bite shallower. For Class II cases, we have to "overcorrect" to an edge-to-edge position, and Class III cases to deeper bite and a little bit Class II relationship.

Patients usually get disarticulated buccal segments in contact in 8 weeks when wearing initial elastics (Quail) . The most difficult time will be the initial two weeks. They will need to maintain a diet of soft foods until touching back teeth. They must eat more slowly and cut up the foods into small bites. We have to let patients know that if they wear rubber bands "Full time" (24 hours), it will save them up to 12 months of treatment time or more and get a more beautiful result. And because the rubber bands will break fairly easily, they must take plenty and carry them everywhere they go.



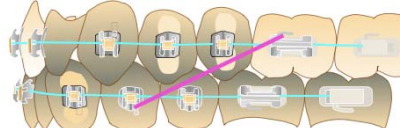
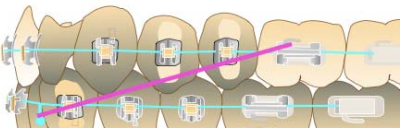
Dr. Tom Pitts' Protocol of Elastics and Bite Turbos

Fig 10A

Wire	Elastics	Direction	Duration	Bite Turbo
Class I Deep Bite or Class II, End-on, Non-Extraction				
.014 NiTi★ (.013 PRN)	Quail 3/16 2 oz.	Shorty CL II U4-L6 	Full Time	U Anterior
.018 NiTi (PRN)	Quail 3/16 2 oz.	Shorty CL II U4-L6 	Full Time	U Anterior
.014 x .025 NiTi	Kangaroo 3/16 4.5 oz.	Shorty CL II U4-L6 	Full Time	U Anterior
.018 x .025 NiTi	Kangaroo 3/16 4.5 oz.	Shorty CL II U4-L6 	Full Time until Overcorrected then Nights	--
.019 x .025 SS	Kangaroo 3/16 4.5 oz. or Impala 3/16 6 oz.	Full CL II U hook to L6 	Full Time until Overcorrected then Nights	--

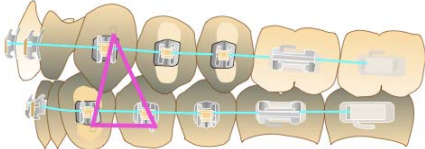
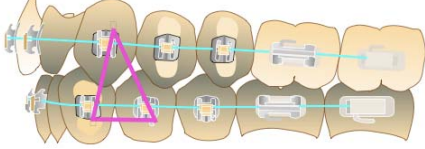
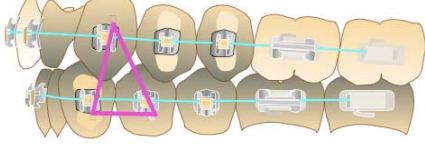
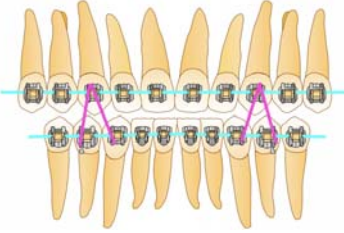
★ Keep it short to reduce the horizontal vector ! Patients will be uncomfortable for couple days because the posteriors are out of occlusion. Try soft diet and cut food into pieces until the posteriors are in contact.

Fig 10B

Wire	Elastics	Direction	Duration	Bite Turbo
Class III Deep Bite				
.014 NiTi	Quail 3/16 2 oz.	Shorty CL III L3-U5 or Full CL III L4-U6 	Full Time	L Anterior 1's
.014 x .025 NiTi	Kangaroo 3/16 4.5 oz.	Shorty CL III L3-U5 or Full CL III L4-U6 	Full Time	L Anterior 1's
.018 x .025 NiTi	Kangaroo 3/16 4.5 oz.	Shorty CL III L3-U5 or Full CL III L4-U6 	Full Time until Overcorrected then Nights	--
.019 x .025 SS★	Kangaroo 3/16 4.5 oz. or Impala 3/16 6 oz.	Full CI III L hook to U6 	Full Time until Overcorrected then Nights	--

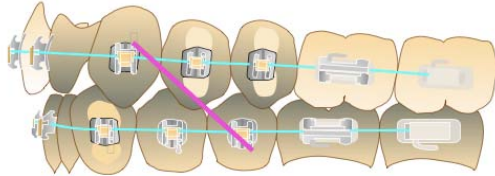
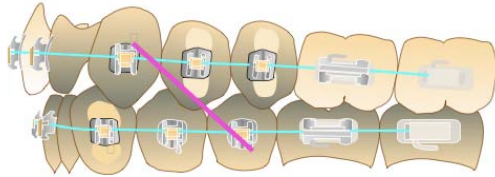
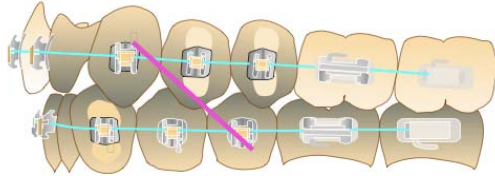
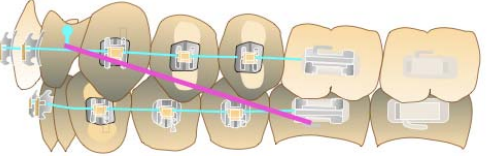
★ Cut wire distal to the U6s if still CI III

Fig 10C

Wire	Elastics	Direction	Duration	Bite Turbo
Class I Open Bite, Non-Extraction				
.014 NiTi★ (.013 PRN)	Parrot 5/16 2 oz.	Triangle U3-L3 or L4 	Full Time	L Molar
.018 NiTi	Parrot 5/16 2 oz.	Triangle U3-L3 or L4 	Full Time	L Molar
.014 x .025 NiTi or .018 x .025 NiTi	Zebra 5/16 4.5 oz.	Triangle U3-L3 or L4 	Full Time	--
U : .019 x .025 SS / TMA L : .016 x .025 SS	Moose 5/16 6 Oz.	Tent L4-U3-L3 	Full Time	--

★ Begin squeeze exercise at the first day. Put fingers on post. fiber of temporalis muscle area to feel the muscle contraction whenever bites on. 50 times as a cycle, do 6 cycles a day to accelerate molar intrusion.

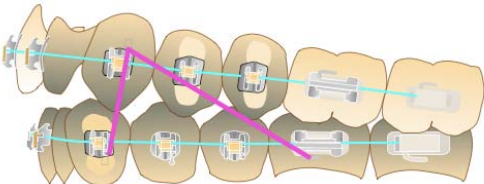
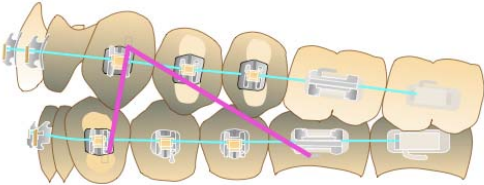
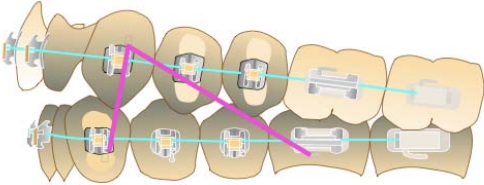
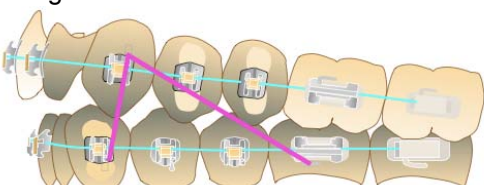
Fig 10D

Wire	Elastics	Direction	Duration	Bite Turbo
Class II Open Bite, Average Severity				
.014 NiTi	Quail 3/16 2 oz.	Shorty CL II U3-L5 	Full Time	Posterior
.014 x .025 NiTi or .016 x .025 NiTi	Kangaroo 3/16 4.5 oz.	Shorty CL II U3-L5 	Full Time	Posterior
.018 x .025 NiTi	Kangaroo 3/16 4.5 oz.	Shorty CL II U3-L5 	Full Time	--
U : .019 x .025 SS L : .016 x .025 SS ★	Kangaroo 3/16 4.5 oz. or Impala 3/16 6 oz.	Full CL II U hook-L6 	Full Time until Overcorrected then Nights	--

★ Cut wire distal to the L6s if still CL II

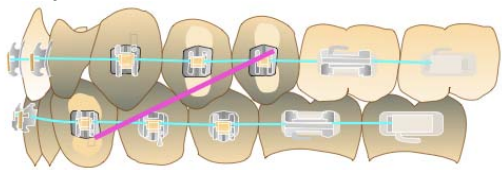
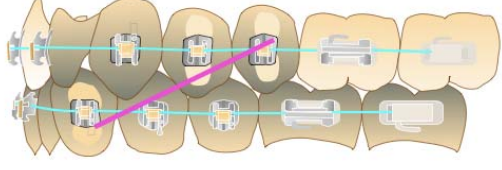
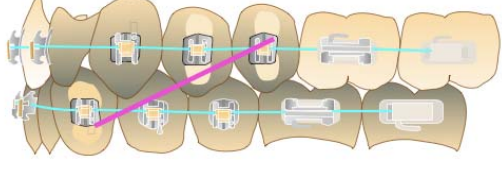
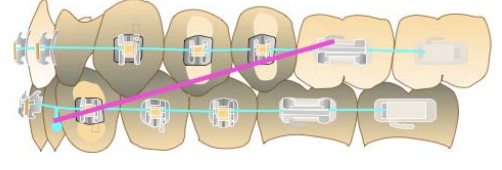
★ 10% of time finish in .019 x .025 SS

Fig 10E

Wire	Elastics	Direction	Duration	Bite Turbo
Class II Open Bite, Severe				
.014 NiTi	Parrot 5/16 2 oz.	Triangle L6-U3-L4 	Full Time	Posterior
.014 x .025 NiTi or .016 x .025 NiTi	Dolphin 5/16 3 oz.	Triangle L6-U3-L4 	Full Time	Posterior
.018 x .025 NiTi	Dolphin 5/16 3 oz.	Triangle L6-U3-L4 	Full Time	--
U : .019 x .025 SS L : .016 x .025 SS ★	Zebra 5/16 4.5 oz.	Triangle L6-U3-L4 	Full Time (Double at night PRN) until Overcorrected then Nights	--

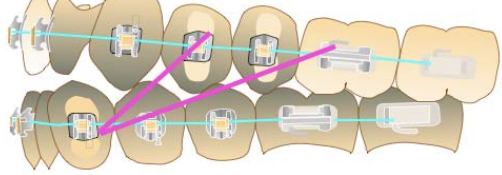
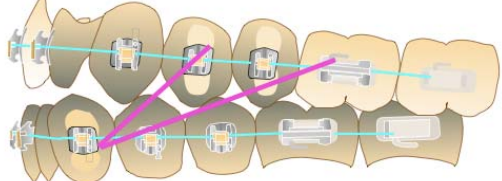
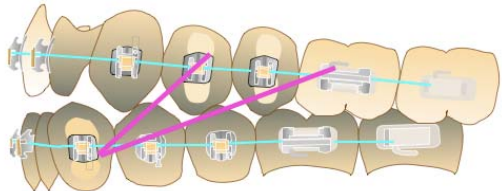
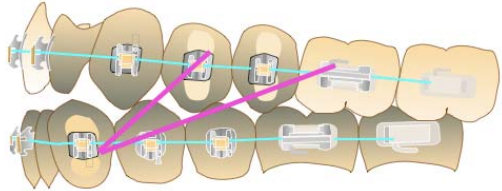
- ★ Cut wire distal to the L6s if still CL II
- ★ 10% of time finish in .019 x .025 SS

Fig 10F

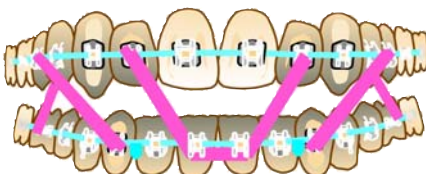
Wire	Elastics	Direction	Duration	Bite Turbo
Class III Open Bite, Average Severity				
.014 NiTi	Quail 3/16 2 oz.	Shorty CL III L3-U5 	Full Time	Posterior
.014 x .025 NiTi or .016 x .025 NiTi	Kangaroo 3/16 4.5 oz.	Shorty CL III L3-U5 	Full Time	Posterior
.018 x .025 NiTi	Kangaroo 3/16 4.5 oz.	Shorty CL III L3-U5 	Full Time	--
U : .019 x .025 SS / TMA L : .016 x .025 SS ★	Impala 3/16 6 oz.	Full CL III L hook-U6 	Full Time until Overcorrected then Nights	--

★ Cut SS wire distal to the U6s if still CL III

Fig 10G





Wire	Elastics	Direction	Duration	Bite Turbo
Class III Open Bite, Severe				
.014 NiTi	Parrot 5/16 2 oz.	Triangle U6-L3-U4 	Full Time	Posterior
.014 x .025 NiTi or .016 x .025 NiTi	Dolphin 5/16 3 oz.	Triangle U6-L3-U4 	Full Time	Posterior
.018 x .025 NiTi	Zebra 5/16 4.5 oz.	Triangle U6-L3-U4 	Full Time	--
U : .019 x .025 SS L : .016 x .025 SS ★	Zebra 5/16 4.5 oz. or Moose 5/16 6 oz.	Triangle U6-L3-U4 	Full Time (Double at night PRN) until Overcorrected then Nights	--

★ Cut SS wire distal to the U6s if still CL III



As for Class III Severe Open bite with post. crossbite cases, we can use cross bite elastics, Class III elastics plus Ant. up & down elastic. Started with Quail, then switch to Dolphin. When progress to .018 x .025 NiTi, switch the elastic to Zebra.

Fig 10H

Wire	Elastics	Direction	Duration	Bite Turbo
Cross Bite				
.014 NiTi ★	Parrot 5/16 2 oz.	Posterior Cross Bite U5/6 Lingual-L5/6 Buccal 	Full Time	Depends on whether open or deep bite. Usually posterior
.018 NiTi	Dolphin 5/16 3 oz.	Posterior Cross Bite U5/6 Lingual-L5/6 Buccal 	Full Time	Depends on whether open or deep bite. Usually posterior
.014 x .025 NiTi or .016 x .025 NiTi	Dolphin 5/16 3 oz. or Zebra 5/16 4.5 oz.	Posterior Cross Bite U5/6 Lingual-L5/6 Buccal 	Full Time until overcorrected then Nights	--
U : .019 x .025 SS • L : .016 x .025 SS ★	Zebra 5/16 4.5 oz. or Moose 5/16 6 oz.	Posterior Cross Bite U5/6 Lingual-L5/6 Buccal 	Full Time until overcorrected then Nights	--

★ Bond Kaplan hooks on palatal surfaces of upper 2nd premolar & 1st molar. Add bite turbos on lower molar cusps to disarticulate if needed.

★ Cut SS wire distal to the point where the buccal occlusion is ideal. CL I & II, cut the upper wire. CL III, cut the lower wire.

● Extraction mechanics

Remember, “ Only Extract for the face , not for the space ” ! Dr. Pitts rarely treats patients with extractions unless the profile is unattractive. The very first reason Dr. Pitts will extract is “Bimaxillary protrusion with Lip incompetence”. And the second reason is “Crowding with protrusion and very wide arches”. But this is very rare. Because when patients have crowding with protrusion, usually the arches are fairly narrow. Dr. Pitts trains patients with lip incompetence to practice “lip seal exercise” to keep the mouth close even when they are treated with extractions.

Remember the more we widen the arches with the proper torque on the incisors, the less we need to consider extraction. Try to treat patients with flat lips non-extracted. Dr. Pitts always treats these patients 10 to 12 months before he makes a decision whether extract or not.

When treating extraction cases, be aware to use **High torque (+7°)** on cuspids to keep the root away from the buccal plate. If you have difficulty in closing spaces, add an additional 20° lingual root torque from canine posteriorly to keep the roots away from the buccal plates to facilitate space closure.

In extraction cases, first level and align teeth including second molars. Once we progress to 14x25 NiTi (or 18x25 NiTi) and the spaces between cuspids to cuspids are consolidated, lace 3-3 with .008 ligature wire. Use Stainless steel wire to close spaces to prevented unwanted dumping of anteriors. Mostly the 19 X 25 SS with wire passes through only to the 1st molars.

Attach posts or loops distal to the laterals. Dr. Pitts uses medium NiTi coil spring (activate about 9 mm or

about 4 ~ 6 ozs) from distal wire of the 1st molar to the archwire hooks (not directly to the canines) so force is more evenly distributed over the whole arch wire. He bends the end of coil to a 90 degree angle before hooking the spring on the end of the wire. Space closure with coil springs provides more consistent long term pressure than with elastomeric modules, chain elastics, or Class I elastics. He activates coils every 11 weeks so he doesn't have to see patients very often. He closes upper and lower spaces simultaneously. With proper activation, one should expect about 1.2 mm closure per month (Fig 11).

If midline is off, we can only activate one side of which space was not totally closed in combination with unilateral Class I or Class III elastics. If the space is not closed one sided, Dr. Pitts will have patients chew small pieces of gum on the affected side or add lingual root torque on buccal segment. So the spaces will close more quickly. Never go back to the 2nd molars when closing spaces because it will slow down the closure. With the low friction passive self-ligating brackets provided, we don't have to worry about “anchorage”. The more we widen the arches, the more the anterior teeth will distalize !! Keep arch wide

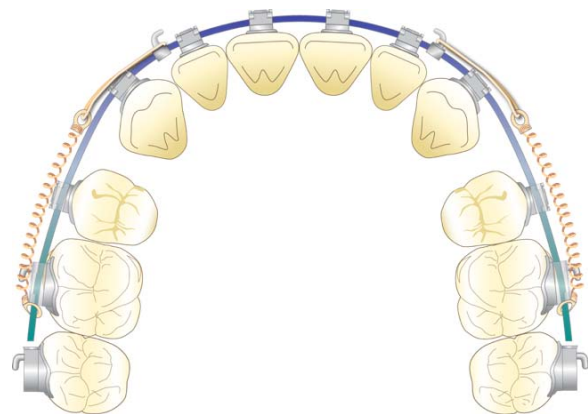

Fig 11. With proper activation, one should expect about 1.2 mm closure per month.

on extraction cases can also prevent unattractive buccal corridor.

Once we close the space, ligate the adjacent teeth to the extraction site with .010 ligature wire figure eight, and go back to 18 X 25 NiTi to 2nd molars for 8 to 10 weeks leveling and alignment. Then go to 16 X 25 SS or TMA on lower, 19 X 25 SS or 16 X 25 SS on upper for detailing and finishing. Using 19 X 25 SS for major mechanics!! It is an excellent wire to maintain integrity of arch during AP correction and space closure. It's also an ideal tool for maintaining the anterior vertical.

Dr. Pitts will tell the patients that extraction treatment will cost 6 to 8 months longer than non-extraction. Usually it takes 18 months for non-extraction treatment, and 24 months for extraction one.

● Retention

In order to maintain good results, we have to check CR position each visit and this must be recorded in every visit during treatment. Be sure not to have Dual bite or CO - CR sliding after completion of the treatment to sustain the results. Always strive for a “centric relation” !! One reason to use early light short elastics is to correct A-P discrepancy during early stage of treatment. This helps the neuromuscular system to adapt well and balance earlier. During the finishing stage, we not only use finishing elastics, but also have to do occlusal adjustment to remove any interferences. 99% of Dr. Pitts' occlusal adjustments were on “lingual” cusps. Once there is premature contact on the lingual side, the buccal occlusion will not fit well even with finishing elastics. It is important to fit every tooth together in finishing stage. If we asked Dr. Pitts that *when dose he lets teeth “settle”* ? The answer would be “Never” !! Never let the teeth settle after the braces are off !!

Always “over-treat” the Class II's (to an edge-to-edge position), Class III's, deep bites and open bites!! Particularly in deep bite cases, they tend to relapse to deep bite. Dr. Pitts started using lingual fixed retainer on upper arch just a few years ago. This is because he observed that out of those beautifully finished cases that wore only removable retainers, 50% of their lateral incisors moved gingivally. This is not very esthetic. Thus, Dr. Pitts decided to bond upper 2-2 with fixed retainer. Usually, Dr. Pitts finished his cases in shallow bites, except for the Class III and anterior openbite cases which need to be overcorrected. So, there is always enough space for the upper fixed retainer. He uses Ortho Flex Tech for an upper fixed retainer, and .027 TMA or .0175 / .0195 twisted wire for lower 3-3 combined with clear retainer (.040 inch clear sheet). Patients have to wear upper and lower clear retainers full time for 4 weeks after debonding, and then switch to night time only. The upper fixed retainer should be placed for more than 3 years, and the lowers' should be placed for a life time. Patients should also wear clear retainers for a life time.

We can make the removable thermoplastic retainers to either horseshoe shape for the maxillary arch to resemble the mandibular arch, or to increase their palatal coverage for extra strength to minimize lateral relapse. Usually, Dr. Pitts prefers the horseshoe shape, but with the narrow arch, in order to keep the arch wide, the retainer should have sufficient palatal coverage.

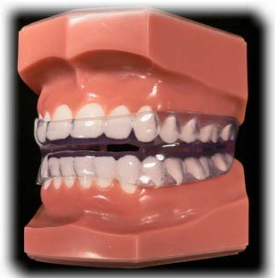Dr. Pitts prefers the muscle training splint (Damon splint) mostly (Fig 12). However, he doesn't go to the splint right after debonding. He would instruct the patients to wear clear retainers for 3 months and then take final records for the splint. Dr. Pitts has started to use this splint since 1977. At first it was for the patients with TMD problems. Dr. Pitts used this splint to move the mandible forward to release the

condyle while Dr. Damon used this splint mainly for open bites. Now the indications of Damon splints are : 1. Herbst retention , 2. Severe posterior crossbite , 3. Lat. tongue thruster , 4. CLII's corrected with elastics or Herbst with springs , 5. Class III malocclusion , 6. Deep overbite cases , 7. Anterior open bite , 8. Any patient with severe muscle dysfunction , 9. Tongue trainer , 10. TMJ - bruxing / clenching , 11. Sleep Apnea. The splint is made of materials which have a soft inner liner with a hard outer liner. Dr. Pitts would block out the models first because he doesn't want the splint to have much retention. For Class II patients, make the bite in edge-to-edge position, open the anterior for about 5 ~ 6 mm. In apnea patients, we can make the bite more forward and more open. For Class III patients, take the bite to centric relation and make it forward about 1 mm.

Finally, what does greatness mean to you ? It should be

more than just "straightening teeth"!! We have been fortunate have benefited from the advancement of orthodontic tools. Having armed with the Damon Light Force System and the knowledge of precise bonding, proper torque selection, how and where to add bite turbos, and the applications of early light short elastics, we can maximize the power of the Damon system. ecause of Damon orthodontics has become more fun and easier than ever and our treatment far more effective and efficient !!

Fig 12. Muscle training splint (Damon splint)



Q & A (Dr. Sabrina Huang and Dr. Pitts)

Q1. In Phoenix Damon forum 2008, Dr. Thomas suggested that whenever we need "Transverse" development, use "High torque" brackets on canine. How is your opinion on this ?

Ans : Dr. Pitts only use "High torque canine bracket" in two situations :

1. Retroclined canine. They will upright a bit on there own as the arch develops, so we don't want to over-torque
2. Always, Always, Always use high torque on extraction cases to keep the canine root away from Buccal plate.

Q2. I was wondering why you always use 2nd molar accent tube to bond the 1st molars ? Is that just because of it's easier to bond with the small pad tube ? Is it going to change the 1st molar torque ?

Ans : They are actually 1st molar tubes with proper torque. This is what I order. The only difference is that the U7's have a 10 degree offset or rotation and the U6's have a 12 degree offset.

LL6/ #342-5131/-27 torq/0 ang LL7/ #342-5117/-10 torq/0 ang LR6/#342-4131/-27 torq/0 ang LR7/#342-4117/ -10 torq/0 ang

UL6/ #342-5115/-10 torq/0 ang UL7/#342-0445/ -27 torq/0 ang UR6/#342-4115/-10 torq/0 ang UR7/#342-0545/-27 torq/0 ang

The U7's are actually old A Company Lower molar tubes that I found 20 years ago. Now of course they do make the -27 in Titanium and steel with the proper offset. I just keep reordering my old stuff because it works well for me. I use the lower left molar on the upper right and vice-versa on the other side.

Q3. The small tip light cure machine you used seems easy to handle with, where can I get that ?

Ans : The laser curing light is not a great investment. It is very expensive and the fiber optic tube breaks easily and the replacement is over \$1000

Orthodontic Treatment of a High-Angle Case with Gummy Smile

Introduction

The importance of vertical control in high-angle patients has been well discussed. Because the molars of high angle cases tend to become mesial tipped and extruded during the course of orthodontic treatment, the mandibles rotate backward and worsen the facial profile. In addition, treating high-angle class II patients with deep overbite problems by the intrusion archwire systems such as a utility arch or an intrusion arch could potentially create a force to extrude the molars. Therefore, it is recommended that extraoral appliances like the high-pull headgear should be used for better vertical control. It is undoubted that the patients' cooperation would be critical to the final achievement.

Recently, what has revolutionized orthodontic

anchorage is orthodontic mini-implant. These devices not only provide maximal and stable anchorage in various type of tooth movement¹⁻⁹ but also work without the need of patients' cooperation. This case demonstrates the successful use of orthodontic miniscrews as anchorage to retract and intrude incisors and control the posterior teeth vertically in a patient who exhibited a deep overbite, Class II malocclusion with a high mandibular plane angle and a gummy smile.

Case report

This 29-year-old female patient had lip protrusion, gummy smile, mentalis strain and chin retrognathism (Fig 1). Intraoral examination revealed a bilateral class II canine and molar relationship, and a 5.0 mm overjet and 4.5 mm overbite (Fig 1). The patient had severe skeletal discrepancies with an 9.5° ANB angle and a high mandibular plane angle

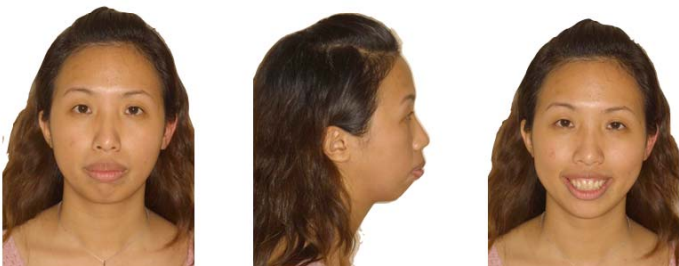

Fig 1. Pretreatment facial and intraoral photographs. Gummy smile was noted.

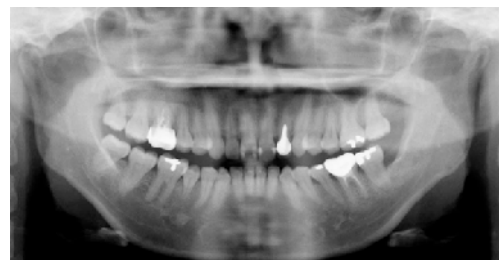

Fig 2. Pretreatment panoramic radiograph

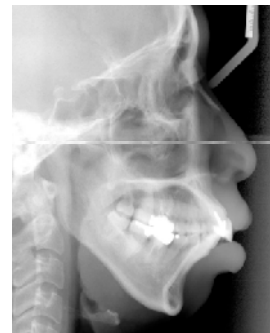

Fig 3. Pretreatment lateral cephalometric radiograph.

Dr. Pei-Chen Hu
Beauty Forever Orthodontic Clinic



Dr. Johnny Joung-Lin Liao
Beauty Forever Orthodontic Clinic



(Table 1). In addition, the arch length discrepancies in maxillary and mandibular arches were zero and 6 mm. The treatment plans were to extract the maxillary first and mandibular second premolars, and use miniscrew implants as the anchorage control in posterior teeth region. Moreover, the miniscrew implants were implanted in the alveolar bone below the anterior nasal spine of the maxilla and below the root apices of mandibular central incisors for upper and lower incisors intrusion.

■ Treatment progress

The orthodontic appliances (Alexander miniwrick: 0.022 inch slot in posterior teeth and 0.018 inch slot in six anterior teeth) were placed for leveling with 0.016-inch Nitinol archwire. One week after initial leveling, miniscrew implants (2 mm in diameter, 10 mm in length, Bio-Ray A-1, J type) were placed bilaterally in the alveolar bone between the maxillary and mandibular first molars and second molars (Fig 4). Two months later, these miniscrew implants which used for anterior teeth intrusion were placed below the anterior nasal spine and below the lower anterior teeth root apices (Fig 5). Furthermore, an orthodontic ligature wire was tied in the head

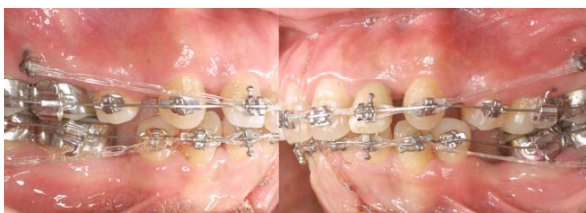

Fig 4. Bilateral miniscrew implants in the alveolar bone

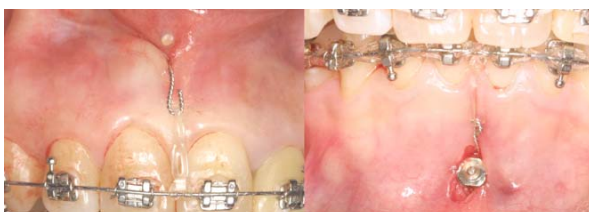

Fig 5. Anterior miniscrew implants in the alveolar bone

of the miniscrew implants. During treatment appointments, a light elastic chain was tied from the ligature wire to the main archwire and renewed throughout treatment. A 0.017x0.025 SS archwire was inserted and an elastic chain was applied between anterior teeth and miniscrew implants to retract anterior teeth (Fig 6).

■ Treatment results

The treatment was finished after 25 months with class I canine and molar relationship. The posttreatment facial photographs showed improvement of the facial profile and the gummy smile in a posed smile (Fig 7). There was no abnormal root resorption noted in the posttreatment panoramic radiograph (Fig 8). The cephalometric superimposition revealed that the maxillary anterior teeth were retracted 8 mm with 3.1 mm intrusion and the mandibular anterior teeth were retracted and intruded. Meanwhile, the maxillary posterior teeth showed uprighting, intruding and a slight distal movement, and the mandibular posterior teeth were uprighted. Accordingly, this was followed by closure of the mandibular plane angle and an increase in the SNB angle (Fig 10). Therefore, the facial profile was much more harmonious by resolving the hyperactive muscle strain of the circumoral and mentalis musculature after retraction of the anterior teeth and vertical control of the mandibular posterior teeth during space closure. The deep overbite and the gummy smile could be corrected efficiently by the miniscrew anchorage.

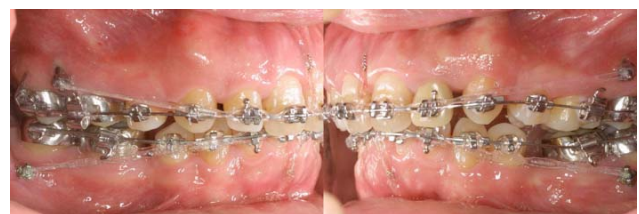

Fig 6. The elastic thread was applied between anterior teeth and miniscrew implants to retract anterior teeth.

Discussion

While treating high-angle cases, proper vertical control of posterior dentoalveolar height could either enhance mandible forward rotation or maintain mandibular plane angle. It is suggested that the control of posterior tooth eruption would be the most manageable factor available for the overall control of anterior vertical dimension of lower face.¹⁰ It is reported that a 1-mm posterior teeth extrusion could result in a movement of up to 3 mm at gnathion. Much emphasis has been focused on reduction of maxillary posterior alveolar heights. Furthermore, some authors stated that the vertical control of mandibular posterior teeth had been considered a contributing factor for the mandible rotation in counterclockwise direction with improvement of the facial profile.^{11,12} However, the intrusion of molars in one jaw was not enough to improve the facial profile because unwanted extrusion of molars occurred in the opposite jaw.^{13,14} It is better to intrude the molars of two jaws to obtain proper vertical control.

Prior to treating a deep bite and gummy smile case, it is

necessary to determine its etiologic factors. Deep bite occurs due to a reduced lower facial height and lack of eruption of posterior teeth or overeruption of anterior teeth¹⁵. Gummy smiles can be divided into several categories¹⁶⁻¹⁸, including lip length and activity¹⁹, gingival hyperplasia with short clinical crown length²⁰, dentoalveolar extrusion, vertical maxillary excess²¹ or combination of these factors. In our case, the Me to PP length was within the normal range; however, the mandibular plane angle (SN-MP), the L1 to MP length and the U1 to PP length were greater than the normative mean. It was assumed that this deep bite and gummy smile was caused by dentoalveolar extrusion and vertical maxillary excess. The Class II malocclusion case with vertical maxillary excess and dentoalveolar extrusion might be treated with orthodontic treatment and orthognathic surgery, which is considered the optimal overall solution to the involved dental, skeletal, and soft tissue problems. Based on the decision made by the patient, an orthodontic-only treatment was selected.

While treating deep bite by extrusion of posterior teeth, it is difficult to maintain mandibular angle in nongrowing patients²². In addition, Proffit and Fields¹⁵ suggested that it

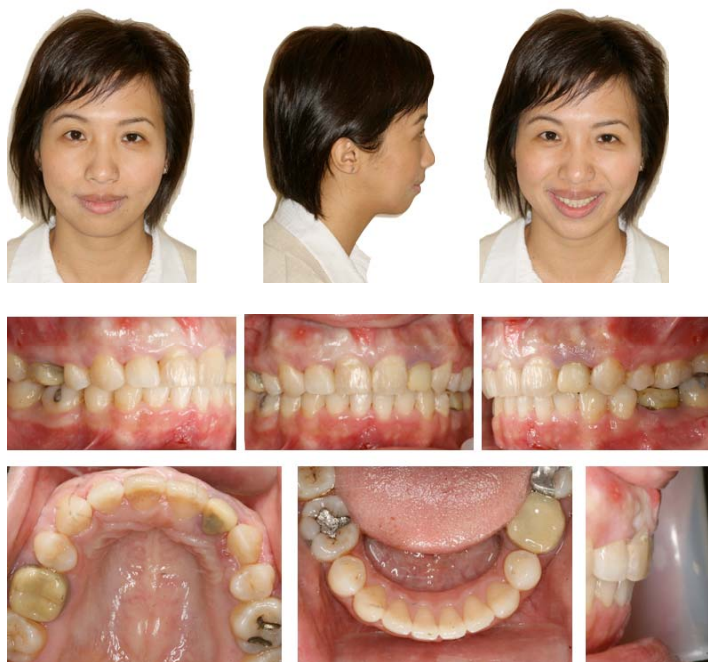

Fig 7. Posttreatment facial and intraoral photographs.

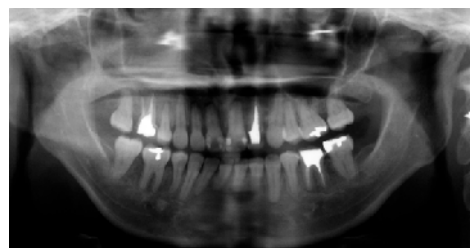


Fig 8. Posttreatment panoramic radiograph

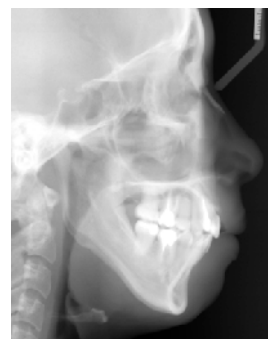

Fig 9. Posttreatment lateral cephalometric radiograph

would be better to intrude incisors to obtain proper gingival exposure. The J-hook headgear is used for incisor intrusion, while it requires patient's excellent cooperation²³. Furthermore, utility arch²⁴ or intrusion arch¹⁸ are also used for incisor intrusion, however it is very likely to extrude the molars at the same time^{15,25}. According to Creekmore and Eklund¹, miniscrew implants had been used to intrude incisors and to correct a deep overbite. They inserted a bone screw just below the anterior nasal spine and intruded the maxillary central incisors approximately 6 mm after 1 year of orthodontic treatment. In 1997, Kanomi² proposed using a screw of 6 mm in length and 1.2 mm in diameter to intrude mandibular anterior teeth in a patient with a deep overbite. Ohnishi et al.⁹ also reported a patient with deep overbite, which was corrected by intruding the maxillary incisors by using a miniscrew implant as orthodontic anchorage; furthermore, this could improve the gummy smile. Comparing the result, intruding maxillary incisors by using a miniscrew implant as anchorage with a segmented wire²⁶ or a continuous archwire⁹ could correct the gummy smile efficiently both without elongation of the molars.

In our case, miniscrew implants placed between the first and second molars in the maxillary arch provided anchorage for anterior teeth retraction and posterior teeth intrusion. Meanwhile, mandibular miniscrew implants placed between the first and second molars provided an anchorage for retracting the anterior teeth and uprighting the molars during space closure.

However, the intruding force for posterior teeth was not applied directly from the microscrew implants to the main archwire. We believe that en masse retraction of the six anterior teeth against the miniscrews implants would rotate the maxillary occlusal plane in clockwise direction and the mandibular occlusal plane in counterclockwise direction. Since the resultant force is not

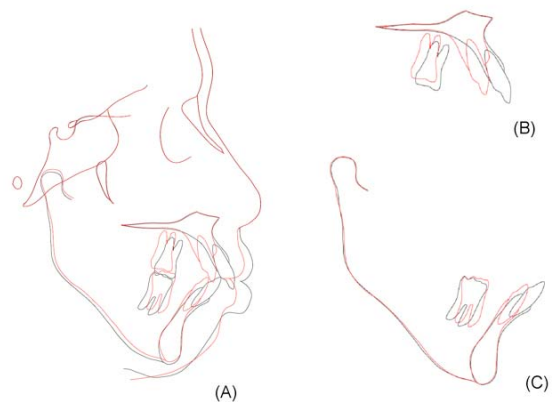


Fig 10. Cephalometric superimposition (A) on the S-N plane; (B) on the palatal plane; (C) and on the mandibular plane at the pretreatment (black line)

Skeletal Horizontal			Dental		
SNA	81.4°	(81.5°±3.5)	U1-SN	100.1→92.5°	(108.2°±5.4)
SNB	71.9→72.2°	(77.7°±3.2)	U1-L1	109.0→126.2°	(119.9°±8.5)
ANB	9.5→9.2°	(4.0°±1.8)	L1-OP	50.9→62.0°	(61.8°±5.4)
A-Nv	2.07mm	(0±2mm)	L1-MP	97.0→88.0°	(93.7°±6.3)
Pg-Nv	-19.7→-19.0mm	(-5±8mm)	U1-NP	25.7→14.6mm	(6.4±2.7mm)
NAP	5→3.5°	(5.1°±3.8)	U1 to PP	35.9→32.8	(27.9±1.7mm)
Skeletal Vertical			L1 to MP	50.5→45.3	(38.1±1.9 mm)
SN-FH	10.0°	(5.7°±3.0)	Liner		
SN-OP	21.8→22.3°	(16°±2)	Me to PP	68.5→67.6	(68.6±3.7mm)
SN-MP	53.9→53.3°	(33.0°±1.8)	Upper lip length	25.3	21.0±1.9 mm
UFH	44.2→44.8%	45%	Lower lip	54.7	46.9±2.3 mm
LFH	55.8→55.2%	55%			

Table 1

passing through the center of resistance, it rotates the occlusal plane which induces the molars intruding and the bite closing. The maxillary incisors were intruded 2.3 mm and the mandibular incisors were intruded 1.5 mm by applying an elastic thread from the main archwire to an orthodontic ligature wire which tied in the head of the miniscrew implants. There was no extrusion of molars giving clockwise rotation of the mandible. Therefore, the

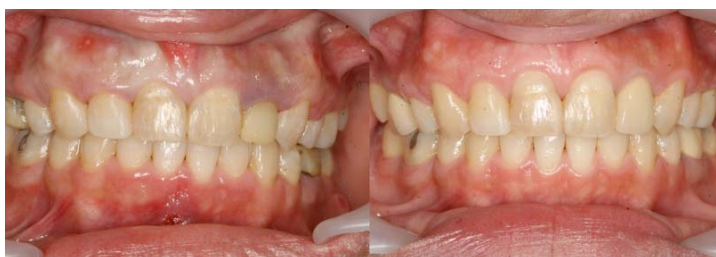

Fig 11. Pretreatment and posttreatment of a periodontal surgery after orthodontic treatment

miniscrew implants anchorage demonstrates correction of the deep overbite and the gummy smile efficiently without the patient's cooperation. The final esthetic improvement of short upper anterior teeth crown length was achieved by using a periodontal procedure after orthodontic treatment (Fig 11, 12).

The post-treatment panoramic radiograph showed that no root resorption occurred in the retracted and intruded incisors region (Fig.8). For one thing, Edwards²⁷ found that the alveolar bone at the mid-root level and alveolar margin but not the apical zone was remodeled with tooth movement. Handelman²⁸ also reported that if the teeth are moved beyond the cortical plates of the alveolus at the level of the incisor apex, root resorption and dehiscence could be expected to occur. Sarikaya et al.²⁹ claimed that bone remodeling-to-tooth movement was not 1:1 and much greater reduction in the alveolar bone was at coronal and mid-root levels than at apical level. Regarding these studies, the entire alveolar

References:

1. Creekmore TM, Eklund MK. The possibility of skeletal anchorage. *J Clin Orthod* 1983; 17:266-9.
2. Kanomi R. Mini-implant for orthodontic anchorage. *J Clin Orthod* 1997; 31:763-7.
3. Costa A, Raffaini M, Melsen B. Miniscrews as orthodontic anchorage: a preliminary report. *Int J Adult Orthod Orthognath Surg.* 1998; 3:201-209.
4. Maino BG, Bednar J, Pagin P, Mura P. The spider screw for skeletal anchorage. *J Clin Orthod* 2003; 37: 90-97.
5. Kyung SH, Choi JH, Park YC. Miniscrew anchorage used to protract lower second molars into first molar extraction sites. *J Clin Orthod* 2003; 37: 575-579.
6. Park HS, Kwon DG, Sung JH. Nonextraction treatment with microcrew implant. *Angle Orthod.* 2004; 74:539-549.
7. Lee JS, Kim DH, Park YC, Kyung SH, Kim TK. The efficient use of midpalatal miniscrew implants. *Angle Orthod* 2004;74: 711-714.
8. Carano A, Velo S, Leone P, Siciliani G. Clinical applications of the Miniscrew Anchorage System. *J Clin Orthod* 2005; 39: 9-24 quiz 29-30.
9. Ohnishi H, Yagi T, Yasuda Y, Takada K. A mini-implant for orthodontic anchorage in a deep overbite case. *Angle Orthod* 2005; 75:444-52.
10. Kuhn, Robert J.: Control of anterior vertical dimension and proper selection of extraoral anchorage, *Angle Orthod* 38:340-349, 1968.
11. Klontz HA. Facial balance and harmony: an attainable objective for the patient with a high mandibular plane angle. *Am J Orthod Dentofacial Orthop.* 1998; 114:176-188.
12. Gebeck TR. Analysis-concepts and values, Part 1. *J Tweed Found.* 1989; 17:19-48.
13. Umemori M, Sugawara J, Mitani H, Nagasaka H, Kawamura H. Skeletal anchorage system for open-bite correction. *Am J Orthod Dentofacial Orthop.* 1999; 115:166-174.
14. Sherwood KH, Burch JG, Thompson WJ. Closing anterior open bites by intruding molars with titanium miniplate anchorage. *Am J Orthod Dentofacial Orthop.* 2002; 122:593-600.
15. Proffit WR, Fields HW. *Contemporary Orthodontics.* 3rd ed. St. Louis, Mo: Mosby Year Book Inc; 2000.
16. Monaco A, Streni O, Marci MC, Marzo G, Gatto R, Giannoni M. Gummy smile: clinical parameters useful for diagnosis and



housing should be considered when retracting the anterior teeth. For another, applying light forces (15–25 gm) during orthodontic treatment produce appropriate pressure within the periodontal ligament^{15,30} and avoid the risk of root resorption. In our case, the retraction of anterior teeth which were accompanied with intrusion could make the anterior teeth stay in the alveolar housing, and an elastic thread could produce this optimal light force from mini-implant anchorage.

■ Conclusion

To achieve excellent improvement of facial profile by maximal anchorage, the anterior teeth could be retracted against the miniscrew implants without anchorage loss and patient's cooperation. Moreover, miniscrew implants can be used to control the posterior teeth vertically and correct the gummy smile and the deep bite efficiently by intruding anterior teeth.



Fig 12. Posed smile before and after orthodontic treatment

therapeutical approach. *J Clin Pediatr Dent* 2004; 29:19-25.

17. Robbins J. Differential diagnosis and treatment of excess gingival display. *Pract Periodontics Aesthet Dent* 1999; 11:265-72.
18. Burstone CR. Deep overbite correction by intrusion. *Am J Orthod* 1977; 72:1-22.
19. Miskinyar SA. A new method for correcting a gummy smile. *Plast Reconstr Surg* 1983; 72:397-400.
20. Redlich M, Mazor Z, Brezniak N. Severe high Angle Class II Division 1 malocclusion with vertical maxillary excess and gummy smile: a case report. *Am J Orthod Dentofacial Orthop* 1999; 116:317-20.
21. Ataoglu H, Uckan S, Karaman AI, Uyar Y. Bimaxillary orthognathic surgery in a patient with long face: a case report. *Int J Adult Orthod Orthognath Surg* 1999; 14:304-9.
22. McDowell EH, Baker IM. The skeletodental adaptations in deep bite correction. *Am J Orthod*. 1991; 100:370–375.
23. Melsen B, Agerbaek N, Markenstam G. Intrusion of incisors in adult patients with marginal bone loss. *Am J Orthod DentofacialOrthop*. 1989; 96:232–241.
24. Ricketts RM, Bench RW, Gugino CF, Hilgers JJ, Schulhof RJ. *Bioprogressive Therapy*. Denver, Co: Rocky Mountain Orthodontics; 1979:111–126.
25. Southard TE, Buckley MJ, Spivey JD, Krizan KE, Casco JS. Intrusion anchorage potential of teeth versus rigid endosseous implants: a clinical and radiographic evaluation. *Am J Orthod Dentofacial Orthop*. 1995;107:115–120.
26. Kim TW, Kim H, Lee SJ. Correction of deep overbite and gummy smile by using a mini-implant with a segmented wire in a growing Class II Division 2 patient. *Am J Orthod Dentofacial Orthop*. 2006 Nov; 130(5):676-85.
27. Edwards JG. A study of the anterior portion of the palate as it relates to orthodontic therapy. *Am J Orthod*. 1976; 69:249–273.
28. Handelman CS. The anterior alveolus: its importance in limiting orthodontic treatment and its influence on the occurrence of iatrogenic sequelae. *Angle Orthod*. 1996; 66(2):95-109; discussion 109-10.
29. Sarikaya S, Haydar B, Ciğer S, Ariyürek M. Changes in alveolar bone thickness due to retraction of anterior teeth. *Am J Orthod Dentofacial Orthop*. 2002 Jul; 122(1):15-26.
30. Dermaut LR, DeMunck A. Apical root resorption of upper incisors caused by intrusive tooth movement. A radiographic study. *Am J Orthod*. 1986; 90:321–329.



Orthodontic Finishing : Art or Science ?

— Summary of Dr. Kokich's farewell lecture in Taiwan —

Dr. Kokich 有關 finish criterion 部分，在 NTO Vol. 13, p 28 - 31 已有詳述，在此僅就其與 art or science 之相關性加以說明。依據 Dr. Kokich 所提結論如下：

ABO Criterion	Art	Science
1. Alignment	v	v
2. Marginal Ridges	v	v
3. Buccolingual Inclination	v	v
4. Occlusal Relationships	v	
5. Occlusal Contacts	v	v
6. Overjet	v	
7. Root Angulation	v	
非 ABO Criterion		
1. Overbite	v	

符合 ABO Criteria 就屬於 work of art；若有研究統計結果顯示這個 criteria 和其他牙周或 TMD 有相關，則此 criteria 就不只是 Art，同時也是 Science。

1. Alignment

當 Alignment 符合 ABO Criteria 時看起來比較吸引人，也符合 esthetics 要求；所以 Alignment 屬於 work of art。Malocclusions 是否會影響個人生活品質和口腔健康的相關部分呢？依據 Trqebert and Peres¹ 的統計結果，若上顎前牙的 crowding 超過 2 mm，就會導致對露齒而笑感到難堪，其程度達一般人的 2.5 倍以上。因此，牙齒 crowding 的確對個人生活品質有負面影響。

至於 Alignment 與牙周健康是否有相關呢？根據 Ngom 等人的研究²指出，下顎 Dental crowding 明顯和幾乎所有的牙周狀況指標有相關，包括 Hygiene, Gingival inflammation 以及 Periodontal disease severity，但上顎卻非如此。因此，基於為了排除因牙齒位置不正而造成牙周不良影響的情況，為患者施與矯正治療是合理的。因為有研究支持 Alignment 和個人生活品質以及牙周健康有關，所以 Dr. Kokich 認為 Alignment 不只是 Art，也是 Science。

2. Marginal Ridges

對牙周健康的患者而言，Marginal ridge 等高，CEJ 也會等高，表示 bone level 也會等高。對 Marginal ridge discrepancy 的患者，若 elongation 的牙齒，X-ray 顯示 bone level 和鄰牙一樣高，則應將 elongation 牙齒 recontouring 以維持等高的 bone level (Fig. 1)。

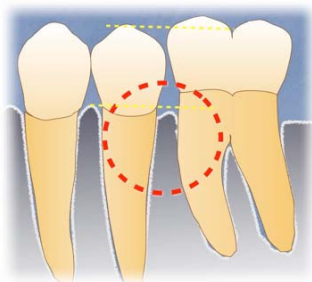


Fig. 1

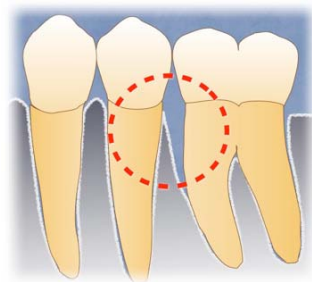


Fig. 2

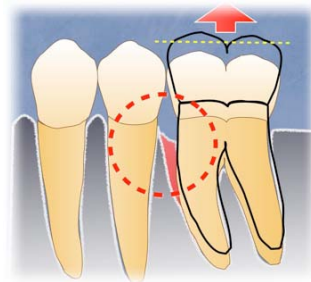


Fig. 3

蘇乙洋 醫師
新洋牙醫診所
貝多芬矯正課程講師



如果 Marginal ridge 一樣高，但 Bone level 卻不一致的時候要怎麼辦呢？這種情形便是所謂的 periodontal defect (Fig. 2)。這種 one-wall periodontal defect 的 prevalence 情況如何呢？本篇研究的結論顯示，在有牙周病的患者中，One-wall periodontal defect 的發生率相當常見（約佔 35%），治療的方式是將這顆牙齒“erupt” (Fig. 3)，目的是使骨頭與鄰牙一樣高，再將這顆牙齒做 occlusal equilibration。因此，在有牙周疾病的患者中，Level the marginal ridge 就等於 Level the bone。所以這不只是 Art，也是 Science。

3. Buccolingual Inclination

從下顎 Frontal view 及 Lateral view 來看，Curve of Wilson 及 Curve of Spee 會組成 Sphere of Monson (Fig. 4)，但事實上這個 Sphere of Monson 只適用於 Denture 的 Balance occlusion。Ferrario 在他的研究中⁴ 提到，下顎牙弓的咬合曲率不受性別影響，但明顯受年齡影響。統計值成年人 Curve of Wilson 的半徑約為 100 mm，兒童為 80 mm。這種 Curve of Wilson 從青春期到成人期的變化可解釋為是因為後牙的 long axis 會沿著咬合平面略往頰側移動，也就是咬合平面會隨著年齡增加而愈變愈平 (Fig. 5)。從成年人 Curve of Wilson 的半徑約為 100 mm (約為 4 inches) 來看，下顎後牙的 buccal 及 lingual cusps 都會接觸到這個圓周，表示高度差異不大，若高

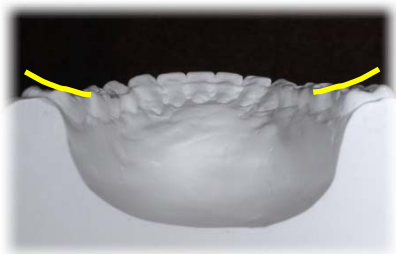


Fig. 4

度差異太大可能跟某種程度的 relapse 有關。因此可以說 Buccolingual Inclination 不只是 Art，也是 Science。

4. Overbite

Overbite 在 ABO 並不列入評分項目。Overbite 的目的是讓下顎在做 protrusive movement 時能夠 disocclude 後牙。因此，Overbite 的深淺取決於後牙 cusps 的長度。依據 Glaros 等人的研究⁵ 顯示，Overbite 深淺與 TMD symptoms 並沒有絕對相關，因此 Overbite 純屬於 Work of art 而非 Science。

5. Overjet

根據 Hirsch 等的研究⁶ 顯示，當我們排除年齡與性別這兩個因子後，Overjet 多寡以及 Overbite 深淺 都不是導致 TMJ sounds (包含 Reproducible reciprocal clicking 以及 crepitus) 的 Risk factors。因此，Overjet 純屬於 Work of art 而非 Science。

6. Occlusal Contacts

根據 Ciancaglini 等人的研究顯示⁷，有單側 TMD 的患者較沒有 TMD symptom 的一般人，兩側 Occlusal contact 點的多寡有較大的差異值。TMD 患側的 Occlusal contacts 值大於沒有問題的那一側。結論是：單側 TMD 和兩側 Occlusal contacts 值的不對稱，有正相關但關連

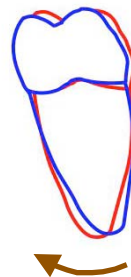


Fig. 5 從青春期到成年期，後牙咬合平面會隨著年齡增加而愈變愈平，也等同於 Curve of Wilson 的半徑變大。

性較弱。因此若以導致 TMD 的 standpoint 來看，Occlusal contacts 不只是 Work of art，也是 Science。

7. Occlusal Relationships

根據 Gesch 等人的研究⁸ 顯示，發現沒有任何 Occlusal factors 和 TMD symptoms 有顯著的相關性。也沒有任何 Functional occlusal factors 和 TMD symptoms 有顯著相關，但有 “Frequent clenching” 這種 parafunction 的患者罹患 TMD 的機率是一般人的 3.4 倍。因此，Class II malocclusion 和 TMD 並沒有相關性。另外，根據 Gesch 等人的研究⁹ 顯示，Malocclusion 和 functional occlusion 與 TMD 的 signs and symptoms 之間的關聯性（association）不大，而且沒有相關性（correlation）。由於沒有任何研究顯示那一種 Occlusal Relationship 會導致 TMD，因此 Occlusal Relationship 純屬於 Work of art。但是，如果我們把 case finish 在 complete Class II 咬合，這樣去考 ABO 會不會過呢？答案是會的（這樣只會扣十分）！！

8. Root Angulation

根據 Artun 等人的研究¹⁰ 顯示，發現矯正治療後的 Root proximity 和相鄰牙齒的 Inflammation，Level of attachment，以及 Bone level 變化並沒有顯著相關。

結果指出：前牙牙根在很接近的情況下，並不會有導致更快速牙周破壞的傾向。但 Dr. Kokich 認為，關於這個研究有幾個 Bias 要考慮：1. 樣本的年齡，他們所選取的患者年齡普遍較年輕（平均 39.7 歲）；2. 患者的類型，他們所選取的患者都是年輕時就接受矯正治療的患者，而非牙周病患者。另外，牙根太靠近所產生的潛在問題還有：1. 牙齒間 papilla levels 的問題，牙根太靠近可能導致 missing papilla；2. 牙周健康維持的問題，牙根太靠近可能導致清潔困難；3. 相鄰牙齒補綴上（Restorability）的問題，牙根太靠近可能導致 crown 的

contour 不好。所以，雖然並沒有證據支持 Root angulation 的 “Science”，在矯正時還是要講求牙根平行性以符合 “Work of art” 比較好（Fig. 6）。

Acknowledgements

感謝黃瓊嬋醫師協助審稿及訂正，蘇荃偉醫師繪圖。

References

1. Traebert & Peres. Do malocclusions affect the individuals oral health-related quality of life? *Oral Health Prev Dent* 5:3-12, 2007
2. Ngom, et al. Intraarch and Interarch Relationship of the Anterior Teeth and Periodontal Conditions. *Angle Orthod* 76:236-242, 2006
3. Tal H. Prevalence and Distribution of Periodontal Defects in Dry Mandibles. *J Periodontol* 55:149-154, 1984
4. Ferrario VF. Three-dimensional dental arch curvature in human adolescents and adults. *Am J Orthod Dentofacial Orthop* 115:401-495, 1999
5. Glaros A et al. Impact of overbite on Indicators of Temporomandibular Joint Dysfunction. *Cranio* 10:277-281, 1992
6. Hirsch C et al. Relationship Between Overbite/Overjet and Clicking or Crepitus of the Temporomandibular Joint. *J Orofac Pain* 19:218-225, 2005
7. Ciancaglini R et al. Unilateral temporomandibular disorder and asymmetry of occlusal contacts. *J Prosthet Dent* 89:180-185, 2003
8. Gesch D et al. Association of Malocclusion and Functional Occlusion with Subjective Symptoms of TMD in Adults : Results of the Study of Health in Pomerania (SHIP). *Angle Orthod* 75:183-190. 2005
9. Gesch D et al. Association of Malocclusion and Functional Occlusion with TMD and Adults : A Systemic Reviews of Population-Based Studies. *Quintessence Int* 35:211-221, 2005
10. Artun J et al. Long-Term Effect of Root Proximity on Periodontal Health after Orthodontic Treatment. *Am J Orthod Dentofac Orthop*

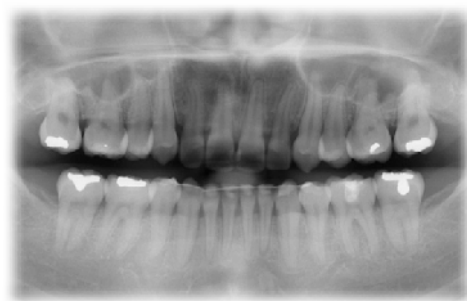
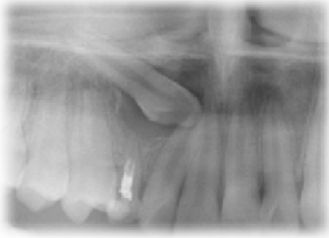
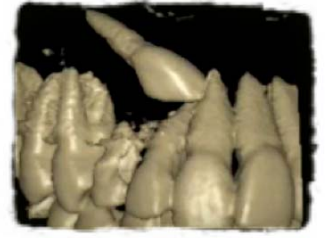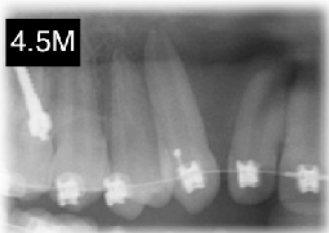
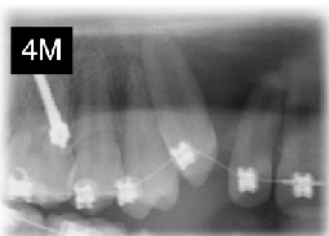
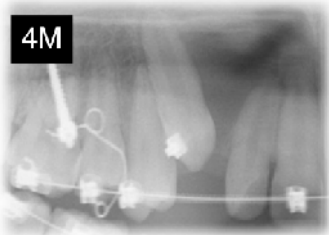
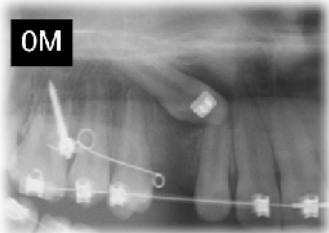
Fig. 6



OrthoBoneScrew (OBS) has a double crossed rectangular slot on its neck. This 18 by 25 rectangular slot provides versatile use of orthodontic mechanics. Wire size with 17 by 25 dimension can be secured in the slot firmly.

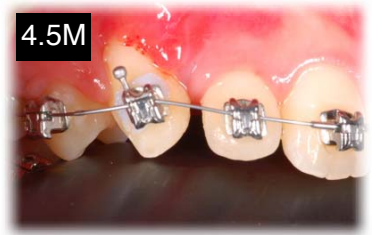
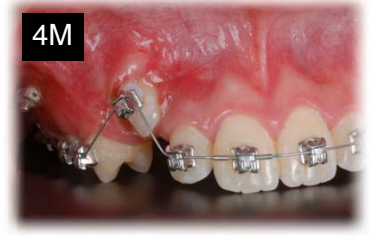
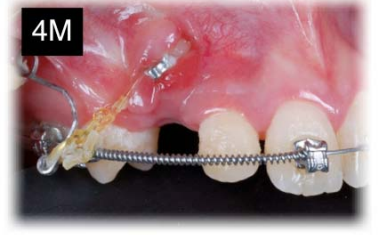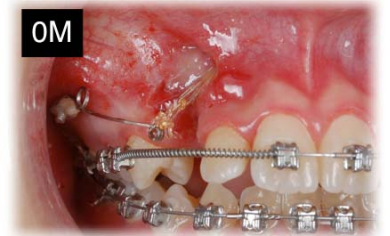A case report of mesially displaced impacted maxillary canines: Demonstration of OBS application



Mechanics design:

A 0.017- x 0.025-inch TMA lever arm was fabricated with a helical coil on one end and helical attachment on the other end. When this lever arm was inserted in the square hole in the OrthoBoneScrew (located at infrazygomatic crest) and activated, it can build a force system which distalizes the canine first, then move buccally a little, finally downward to the reserved canine space. If the mechanics was designed to exert force directly from the main arch wire, it would be detrimental to the roots of the incisors. During the follow-up visits, the helix can be adjusted without taking out. After four months, the impacted canine was successfully moved apart from previous impacted site and ready for bracket bonding.



OrthoBoneScrew
Corporate Headquarters

2F, No. 25, Jian-Jhong First Road, Hsinchu, Taiwan
300

Tel: +886 3 5735676

Fax: +886 3 5736777

Web: <http://orthobonescrew.com>
<http://newtonsa.com.tw>

Surgical and Orthodontic Management of Impacted Maxillary Canines

~Notes from Dr. Kokich's farewell lecture in Taiwan

Impacted maxillary canines is the common situation orthodontists encounter during treatment. Dr. Kokich had published many articles explaining in details about how to manage the impacted maxillary canines^{1,2}. We had a great opportunity to listen Dr. Kokich himself lecturing this topic and had learned a lot from him. Followings, we summarized some important notes from his lecture and shared them with you.

Labial impaction

There are three techniques we can use for uncovering a labially impacted maxillary canine: 1. Excisional uncovering, 2. Apically positioned flap, 3. Closed eruption technique. How should we choose the appropriate technique to uncover the impaction? There are four criteria we need to evaluate:

1. Faciolingual position:

When impacted tooth is out to the facial side, we can use any one of three techniques, since there is little or no bone covering the tooth. However, when the tooth is impacted in the mid-alveolus, the excisional uncovering is not appropriate, because it's hard to know how much bone we need to remove to expose the tooth through this technique.

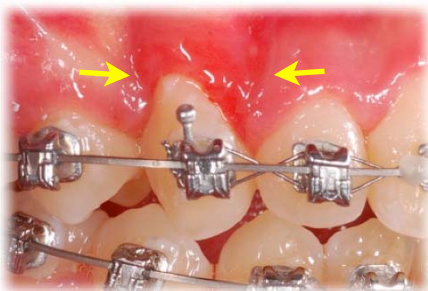


Fig 1. Mucosa lines on mesial and distal side of canine

2. Vertical position of the tooth relative to the mucogingival junction (MGJ):

When most of the tooth is below the MGJ, any of three techniques could be used; in contrast, when most of tooth is above MGJ, excisional uncovering is not recommended. Because when the tooth uncovering with simple excision in the mucosa and moves to the final position, it usually presents with a thicker “roll margin” and left two “mucosal lines” (Fig 1). These mucosal lines may hold the tooth backup and cause the uneven incisal edge position.

3. The amount of gingiva in the area of impacted canine:

When canine erupted, eventually the crown margin will be at the same level as central incisor. Therefore, we can draw a line extended from gingival margin of the central incisor (Fig 2). From this line to the MGJ, we would like to have at least 2-3 mm gingiva, which can give the erupted canine enough epithelial and connective tissue attachment. If there is no enough gingiva present from this line to the MGJ, we should use apically positioned flap technique and produce more gingiva for the canine.

4. The mesiodistal position of the canine crown:

When the impacted canine is in position, any of three techniques could be used. However, when the impacted

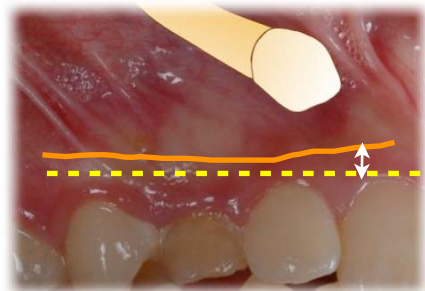

Fig 2. CEJ line to MGJ: 2-3 mm attached gingiva

Dr. Grace Chiu (left), Lecturer, Beethoven Orthodontic Course
Dr. Chris Chang (middle), Director, Beethoven Orthodontic Center
Dr. Dennis Hsiao (right), Lecturer Beethoven Orthodontic Course



canine is displaced mesially or distally (Fig 3), apically positioned flap is recommended.

**** How to perform an apically positioned flap?**

First, we need to do two vertical incisions and one horizontal incision on the area of impacted canine. Reflect a “split thickness flap” and then transmit to “full thickness flap” to expose the covering bone. Remove the covering bone down to the CEJ of the impacted canine (Fig 4). Cover the area with the periodontal dressing (Barricade). When the tissue heals, pull the crown out to the facial side first, then pull the tooth down to the position. With this method, the crown have already been pulled out to the facial and the “root”, not the crown, moves through the bone. The root resorbs the bone efficiently and makes the tooth movement possible. On the contrary, if we use the close eruption technique in this mesially displaced impaction and cover the flap back, the “crown” of the tooth, instead of the “root”, need to move through the bone. However, the enamel don’t resorb bone, it only causes “pressure necrosis”, which can cause the tooth movement very slow and hardly move the impacted canine to the position. Therefore, when impacted canine is displaced mesially or distally, the most appropriate method for uncovering is apically positioned flap.

****When is the close eruption technique appropriate?**

Actually, close eruption technique is the most often used uncovering method for the labially impacted maxillary canine. When comparing the apically positioned flap to the closed eruption technique, apically positioned flap (APF) has more unesthetic results³. It usually presents with a longer tooth and thicker gingiva. Besides, when using the APF technique, the gingiva tissue is healed first in the mucosa then pulled downward. It usually leaves two mucosal lines (Fig 1). These mucosal lines could pull the crown apically and cause undesirable results. Therefore, when the mucosal lines were present, we should perform gingivoplasty (with diamond bur or laser to remove the mucosal lines down to the connective tissue layer and leave them secondary healing) to eliminate mucosal lines and have more favorable results.

In conclusions, Dr. Kokich recommended: We should uncover labially impacted maxillary canine with “close eruption technique”, unless: (1) They are below the MGJ and have adequate gingiva. Then “excisional uncovering” is the choice. or (2) They are displaced mesiodistally or have inadequate gingiva. Then APF is the most appropriate method to use.

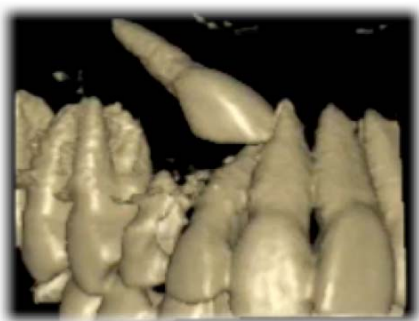


Fig 3. Mesially displaced impacted canine

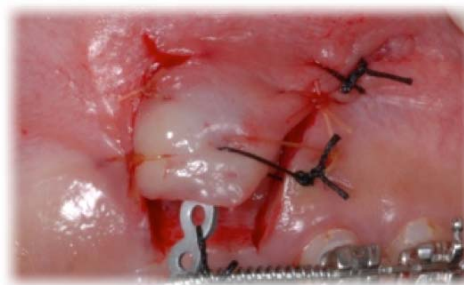

Fig 4. Apically positioned flap

Palatal impaction

Palatally impacted canine is twice as common as labially impacted canine. Is there any preventive method for avoiding palatal impaction? Ericson and Kurol⁴ did a study about early treatment of palatally impacted canines by extraction of the primary canines. They found out that “removal of the primary canine before the age of 11 years will normalize the position of the ectopically erupting permanent canine in 91% of the case, if the canine crown is distal to the midline of the lateral incisor on the radiograph. The success rate of self correction is 64%, if the canine crown is mesial to the midline of the maxillary lateral incisor. However, if the permanent canine is beyond the mesial surface of the lateral incisor, self correction does not occur and it is the case must be treated orthodontically.

When uncovering the palatally impacted canine, Dr. Kokich recommended following procedures: First, uncover the canine and let it erupt on its own (Fig 5). Then start to align the teeth. Once the canine have already erupted to the occlusal plane and space have been created, pull the canine to the position. Finish the treatment. Through these procedures, canine crown erupts first and “root” instead of the crown moves through the bone. When root moves through bone, it lays down bone behind and cause no destruction. On the contrary, if we don’t let the tooth erupt but pull it inside the bone, the enamel of the crown instead of root moves through the bone. When enamel moves through bone, it destroys bone and lays down nothing behind. It can cause the severe periodontal destruction on the adjacent tooth. Therefore, Dr. Kokich recommended: “Routinely uncover palatal impaction early (in the mixed

dentition) before the beginning orthodontic treatment! “With this method, the overall treatment time could be reduced and the results could be more favorable periodontally and esthetically.

References:

1. Kokich VG. Surgical and orthodontic management of impacted maxillary canines. *Am J Orthod Dentofacial Orthop* 2004;126:278-83.
2. Schmidt A, Kokich VG. Periodontal response to early uncovering, autonomous eruption, and orthodontic alignment of palatally impacted maxillary canines. *Am J Orthod Dentofacial Orthop* 2006;131:449-55.
3. Vermette M, Kokich V, Kennedy D. Uncovering labially impacted teeth: close eruption and apically positioned flap techniques. *Angle Orthod* 1995;65:23-32
4. Ericson S, Kurol J. Early treatment of palatally erupting maxillary canines by extraction of the primary canines. *Eur J Orthod* 1988;10:283-95

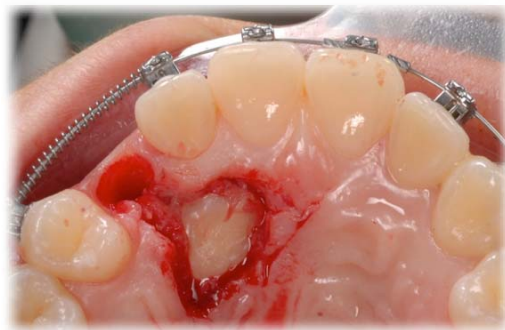
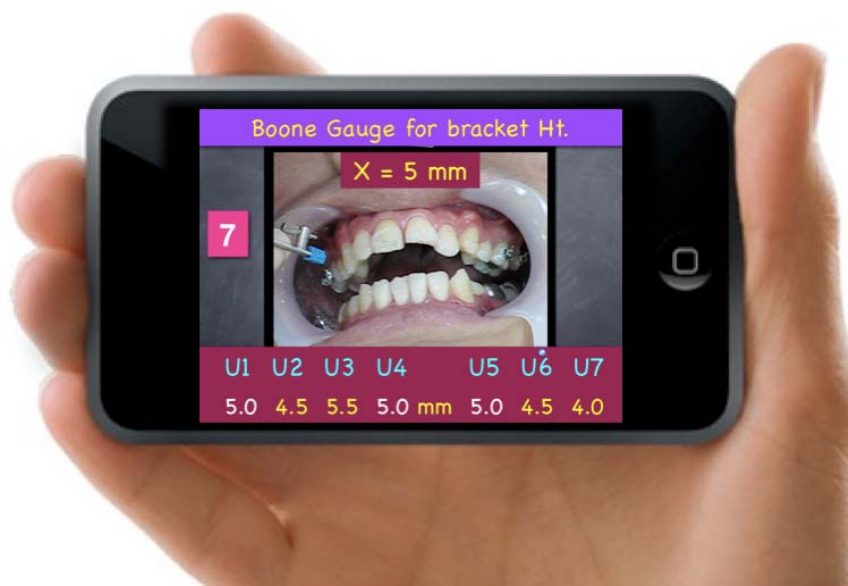

Fig 5. Uncover the canine and let it erupt on its own.

iPod touch

矯正行動學習的最佳利器



iPod touch 貝多芬矯正相關視訊課程軟體

展示期間優惠價九折、課程學員價七折



Beethoven Orthodontic Mobile Learning Program

貝多芬進階班矯正視訊課程系列

售價：7000 元

A. 矯正視訊課程十一大系列：

售價：10,000元

系列一：理想入門病例及矯正器黏著

系列七：維持及復發：持續微力的祕訣

系列二：矯正療程四部曲

系列八：病例示範及診斷分析 (1)

系列三：簡潔有效的錨定系統

系列九：病例示範及診斷分析 (2)

系列四：不拔牙與拔牙分析

系列十：病例示範及診斷分析 (3)

系列五：Damon 診斷流程及微調

系列十一：病例示範及診斷分析 (4)

系列六：生物力學及完工檢測

B. 初、進階植體視訊課程系列：

售價：2,000元

C. 助理視訊課程五大系列：

售價：5,000元

系列一：認識Damon器械 / 照相

系列四：取模 / 活動與固定維持器

系列二：初診流程 / 療程說明 / X-ray

系列五：矯正螺絲/Damon Morph/衛教Keynote

系列三：Bond 與相關衛教 / 辨認 Damon 線 / Damon 應對 Q & A

備註：每年提供視訊課程更新資料只酌收工本費

連絡電話：(03)5735676 黃思涵

金牛頓網頁：www.newtonsa.com.tw

Dr. Charles J. Burstone on Biomechanics of TAD



1月3日，非常高興睽違十年再次邀請 Dr. Burstone 來台演講，Dr. Burstone 素有矯正力學之父的稱號，大家莫不引領企盼他的來臨，這兩天課程涵蓋內容甚廣，以下是有關矯正植體力學的重點整理，與各位分享，其餘的部份會在往後刊出。

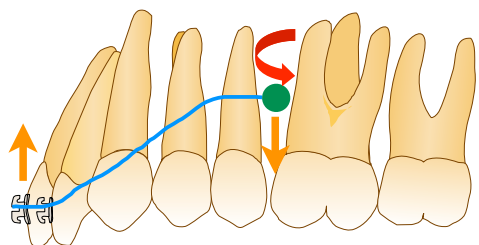


Fig. 1

當代矯正治療由於矯正植體的引進，以往需要許多複雜裝置才能進行的矯正治療，因此得以用更簡單的方法解決。例如原本需要用 posterior segmental osteotomy 才能解決的 severely elongated molar intrusion，現在只要在頰側及舌側各裝一個矯正植體施予 intrusive force 即可達成。矯正植體在臨床上使用愈趨廣泛，矯正醫師常會因此而忘記要去思考“矯正力學”而將它單純化，不過 Dr. Burstone 卻持著不一樣的想法，他認為矯正醫師應要俱備更多的力學知識，去思考加入矯正植體後整個 force system 的改變並分析矯正植體所承受的力量與力矩！

在進入矯正植體不同的應用前，需要有以下幾個基本觀念：

1. Torque on implants

矯正醫師使用矯正植體施力是每天的例行治療，不過卻很少會考量到對矯正植體的影響。譬如在一個從矯正植體延伸出的 intrusion arch 的力學平衡裡，除了對矯正植體有 extrusion 的作用力外，還會有一個 moment 的產生，若是這個 moment 剛好是相反於鎖入方向的，這就會形成潛在鬆脫的原因之一。(Fig. 1)

2. Equivalency

在我們施力時，可以將合力分解成分力，但仍然有相同的施力效果。在有些無法直接施與 C_R (center of resistance) 的情況，可以利用這個觀念。(Fig. 2)

3. Equilibrium

在任何一個力學系統裡都要符合牛頓第一運動定律，也就是所有的力量都達成平衡。

4. Straight wire effects

如果有 continuous wire 使用下，需要考慮使用 TADs 改變整個

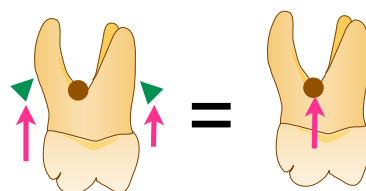


Fig. 2



force system 對 dentition 造成的影響，此外線愈粗摩擦力越大。

● Fine Tuning Anterior Retraction

利用 TAD 作 maximum anchorage 拉前牙來關拔牙空間是我們最常使用的方式。假設 anterior segment 並沒有跟 posterior segment 以 continuous wire 連在一起，hook 的高低及 TAD 的位置就會決定 anterior segment 移動的方式，通常這樣施力會通過 center of resistance 的下方，所以會產生一個讓前牙 dumping 的 moment (Fig. 3)。為了避免這樣的副作用，最簡單的做法是利用 hook extension 來接近前牙的 C_R ，不過這種方法臨床上在頰側常常會受到解剖構造的限制 (Fig. 4)。

假設這時後我們利用一條 dimension 較小且 flexible 的 continuous wire 將前後牙連在一起，這時前牙仍然有會 tipping 的現象，不過由於 continuous wire 想要把彎曲的線變直，而產生了一個類似 step bend 的 force system，使得 posterior segment 產生 mesial tipping 的 moment，這就是為甚麼有些醫師會納悶，明明使用 absolute anchorage，為甚麼仍會有 anchorage loss 的問題？所以臨床上當使用不夠硬的線施力又不通過 C_R 時，就會產生前牙往後 tipping，後牙往前 tipping，以及 posterior openbite 等 side effect (Fig. 5)。

隨著拔牙空隙的關閉，或是 wire 比較粗、摩擦力增加無法 free slide 時，center of resistance 也會逐漸往後移，TAD 的施力會對整個牙弓產生影響，即使在這個情況施力通常無法通過 C_R ，所以會有 occlusal plane canting 的副作用，前牙 bite 會變深，後牙會被 intrusion (Fig. 6)。另外一個利用 continuous wire 的副作用則是會造成 molar rotation 及 buccal crossbite。

Dr. Burstone 認為，在 continuous wire system 下使用

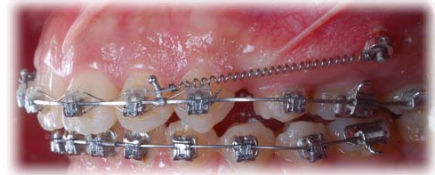

Fig. 3

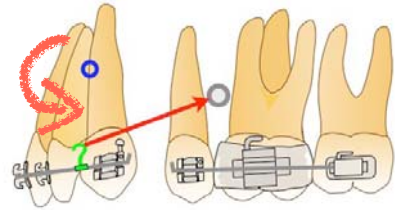


Fig. 4

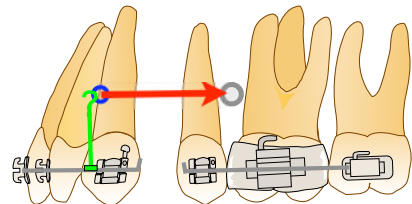


Fig. 5

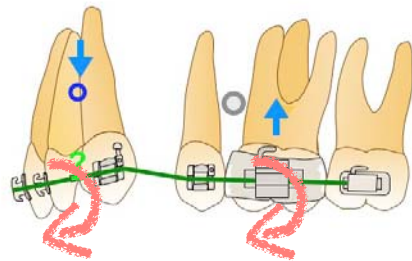
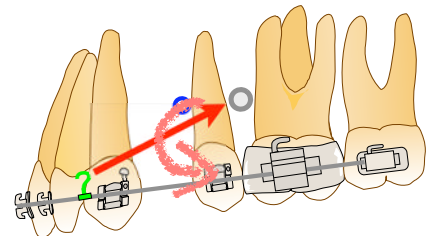


Fig. 6



TAD 作 direct anchorage 常會破壞後牙的咬合，所以最好在前牙作 extension，後牙不用 bracket 及 wire 經過，或利用 TAD 作 indirect anchorage 來避免不必要的副作用。

● Fine Tuning Molar Distalization

一般施力在 occlusal level 的 molar distalization，常會造成 buccal segment distal tipping 而不是 translation，且 molar 會有 mesial out rotation 以及 intrusion 的 side effect。若從 gingival level 施力也會造成 buccal segment 的牙根被 tip-back (root move back more than crown)。因此最好從舌側利用 TPA 作施力，讓力量盡量接近 C_R ，除了有控制 arch width 的好處外，還可利用 extension 的效果來作 molar translation (Fig. 7, 8)。Dr. Burstone prefer 的 TPA 可用不鏽鋼或 TMA 線製作，dimension 為 .032 X .032，通常在臼齒近心端作一個 stop 並多留一些長度來增加 TAD 施力的距離，在 TPA 上 welding 的 hook 材料要與 TPA 一致，而 molar 舌側則是黏上可開蓋的 lingual hinge cap，在這個基本的架構下，利用不同的 hook 及 TAD 位置，可以產生不同的牙齒移動 (Fig. 9, 10)。

另外要注意的是兩側施力對稱性的考量。若是左右兩側的合力不通過 C_R 時，仍然會產生額外的 moment。以咬合面來分析時，左右不對稱的施力也會造成 arch skew (Fig. 11)。

● Fine Tuning Posterior Intrusion

利用 TAD，我們可以 intrude individual tooth、buccal segment 或是 full arch。若是以單顆第一大臼齒而言，到底他的 C_R 在哪裡呢？答案是位於 furcation area 且較接近 palatal root 處，理由有二：一、以 tooth morphology 來說，palatal root 相對較大。二、因為 curve of Monson 的關係，所以 center of resistance 較偏舌側。從這個觀念延伸出去，一般我們對於 molar 做 intrusion 時，palatal side 所用的力量一般要比 buccal side 大一些 (Fig. 12)。若是沒有注意到這一點，容易產生 buccal crossbite 的 side effect。當然除了頰舌側方向的考量，我們也要注意在近遠心方向的合力是否有通過 C_R 。若是要

Fig. 7

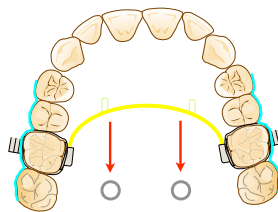


Fig. 8

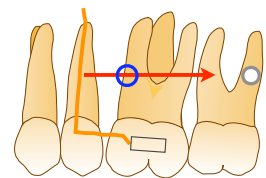


Fig. 9

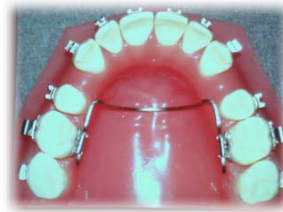

Fig. 10

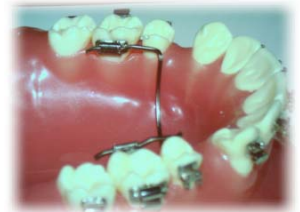

Fig. 11

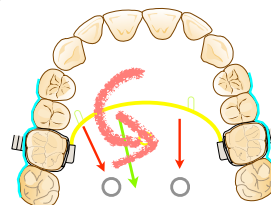
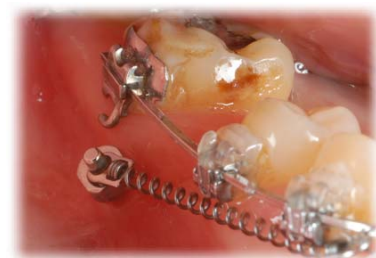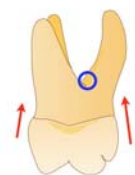


Fig. 12



intrude buccal segment，TPA 的使用可以控制 molar width 和 molar inclination，而施力是否有通過整個 segment 的 C_R 會決定 occlusal plane 是否會產生 canting 的副作用。另外，若要做單側 molar 的 lingual root torque control 以及 intrusion 則不建議用 TPA 做，最好只改 lingual root torque。因為如果要用 TPA 做 intrusion，會對另一側的 molar 造成很大的 moment。

● Fine Tuning Posterior Protraction

在做後牙的 protraction 時，理想上只要在 molar 作 extension，少掉 continuous wire 造成的摩擦力，讓施力通過 TAD 及 C_R ，並且同時在頰舌側施力，避免 rotation 的 side effect（若利用 lingual arch，可免除舌側施力），這樣就能讓 molar 產生 bodily movement（Fig. 13）。但若是以上幾個 factors 並未考量到，就會產生以下幾種 side effects。

1. 未在 molar 作 extension，矯正植體植入位置較低位：容易造成 molar tipping and intrusion。
2. Continuous wire 較 rigid，雖然牙齒比較不容易 tipping，但相對產生較大摩擦力，減緩牙齒移動速度，有時也會造成 anterior segment flaring。
3. Continuous wire dimension 較小且 flexible，容易有

straight wire effect，造成前牙產生往後 tipping 的 moment，再加上若只有頰側施力，還會有 molar rotation 的 side effect（Fig. 14）。

● Fine Tuning Incisor Intrusion

Dr. Burstone 提到 intrude incisor 可以直接利用前牙根間的 TAD 做壓入，或是從後牙的 TAD 延伸出來的 intrusion arch 做壓入，不過這時後要注意 intrusion arch 所產生的 moment 是否過大而造成 TAD 的鬆脫。

● Fine Tuning Indirect Anchorage

一般利用 indirect anchorage 施力時，對 TAD 仍會有很大的 moment，這時可以利用 heavy wire 來降低 TAD 上的 moment，不過相對上就會產生較大的摩擦力。

● Conclusion

“TAD doesn't simplify anything” !! Dr. Burstone 懇切地叮嚀我們在享受使用矯正植體的便利之虞、不要忘記仔細思考整個力學系統，針對不同的情況詳加規劃位置及施力，才不會讓副作用降低你的治療效率。

● Acknowledgements

感謝黃麗芬醫師、蔣金玉醫師及楊宗邦醫師提供參考資料、蔡士棹醫師攝影。

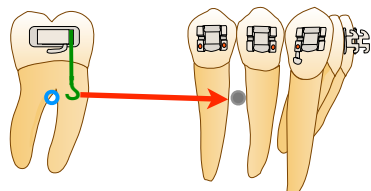


Fig. 13

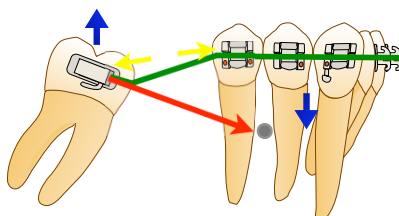


Fig. 14



Impinging Overbite and Large Overjet

HISTORY AND ETIOLOGY

A 25-year-and-9-month-old male was referred by his dentist. His chief concern was an impinging overbite. The patient was in good general health and was eager to receive treatment. Tetracycline stain was noticed throughout the entire dentition. He presented with a deep impinging overbite and 11 mm overjet due to a severe flaring of maxillary incisors. Diastema and the buccal crossbite of #2 were observed. The patient reported no known habits that may have contributed to the malocclusion. However, the clinical examination suggested that the etiology was related to a “lower lip trap” defined as habitual posturing of the lower lip between the maxillary and mandibular incisors .

DIAGNOSIS

Skeletal: Skeletal Class I (SNA 84°, SNB 82°, ANB 2°), lower mandibular plane angle (SN-MP 22.5°, FMA 17°)

Dental: Bilateral Class I molar relationship, 11 mm anterior overjet, 100% deep impinging overbite, protrusive upper, proclined lower incisors, constricted maxillary arch with buccal crossbite of #2, and spacing of the upper anterior teeth.

Facial: Straight profile.

SPECIFIC OBJECTIVES OF TREATMENT

Maxilla (all three planes):

- A - P: Maintain.
- Vertical: Maintain.
- Transverse: Maintain.

Mandible (all three planes):

- A - P: Maintain.
- Vertical: Maintain.
- Transverse: Maintain.

Maxillary Dentition

- A - P: Maintain a Class I molar relationship and reduce dentoalveolar protrusion.
- Vertical: Maintain.



Fig. 1 Pretreatment facial photographs

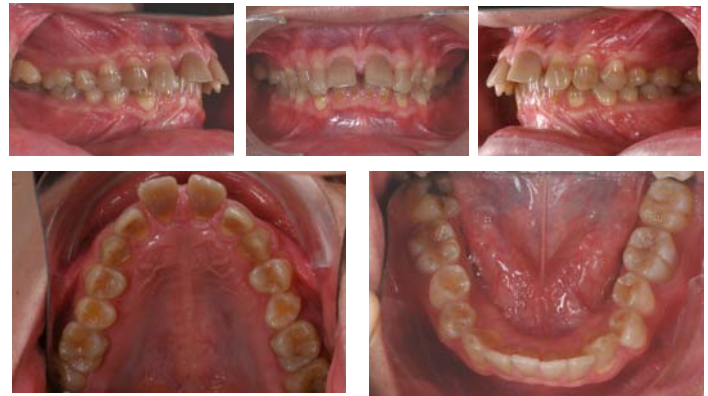

Fig. 2 Pretreatment intraoral photograph

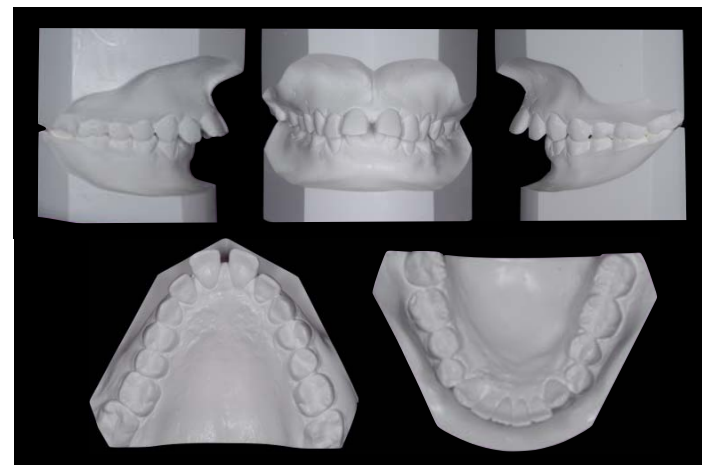

Fig. 3 Pretreatment study models

Dr. Chris HN Chang, Director, Beethoven Orthodontic Center (middle)
 Dr. Steven Wu, Lecturer, Beethoven Orthodontic Course (left)
 Dr. Eugene W. Roberts, Consultant, *News and Trends in Orthodontics* (right)




Fig. 4 Posttreatment facial photographs

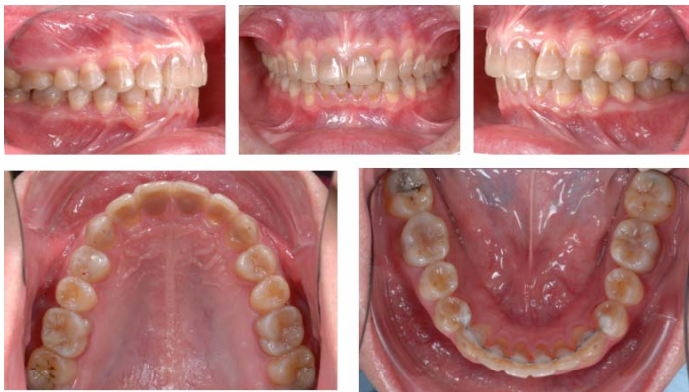

Fig. 5 Posttreatment intraoral photographs

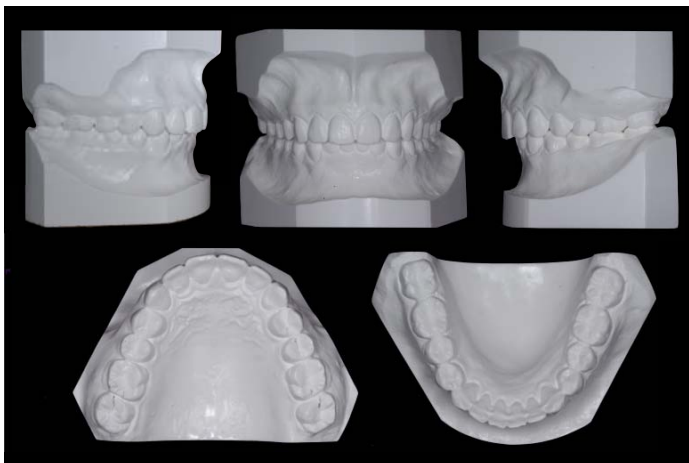

Fig. 6 Posttreatment study models

- Inter-molar Width: Increase.

Mandibular Dentition

- A - P: Maintain a Class I molar relationship and prevent incisor flaring.
- Vertical: Maintain.
- Inter-molar / Inter-canine Width: Increase first molar width and correct #2 buccal crossbite.

Facial Esthetics: Maintain.

TREATMENT PLAN

Non-extraction treatment was pursued by bonding fixed appliances on both arches and placing occlusal posterior bite turbos on lower 1st molars bilaterally. The buccal crossbite of #2 was corrected with cross elastics. Treatment included early light short elastics (2 oz) and anterior bite turbos to achieve a favorable jaw position and to intrude the incisors. Class II elastics were used to resolve the sagittal discrepancy and detailing bends produced the final occlusion. Fixed appliances were removed and the corrected dentition was retained with an upper Hawley retainer and a lower fixed retainer from 4 - 4.

APPLIANCES AND TREATMENT PROGRESS

0.022-in Damon D3MX brackets (Ormco) were used. Both arches were bonded and occlusal bite turbos (Glass Ionomer Cement) were placed on both lower 1st molars, and a lingual button was placed on the lower right 2nd molar. Full time cross elastics (3.5 oz) were applied to the right 2nd molars to correct the crossbite.

Six months after the treatment, the posterior bite turbos were removed and the anterior bite turbos (molded composite resin) were placed. The wire sequences in this case were as follows: .014 copper NiTi, .014X25 copper NiTi, .017X25 TMA and .019X25 SS. The Class II elastics were upgraded gradually from 2 oz, 3.5 oz, 4.5 oz to 6 oz respectively. Upper spaces were closed by power chains on a .019X25 SS wire.

In the 10th month of the treatment, a panoramic film was taken to further examine the bonding positions. Two

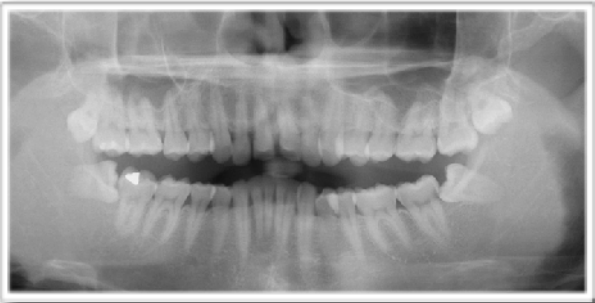
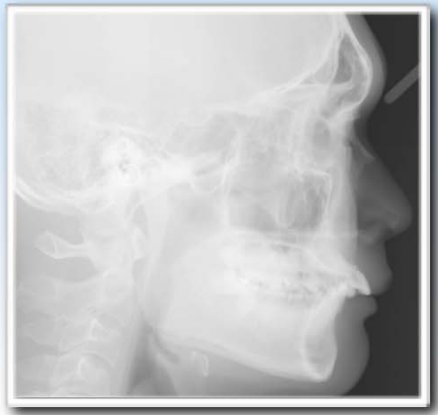
Fig. 7 Pretreatment pano and ceph radiographs

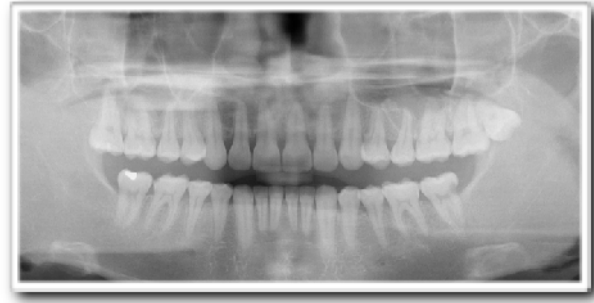
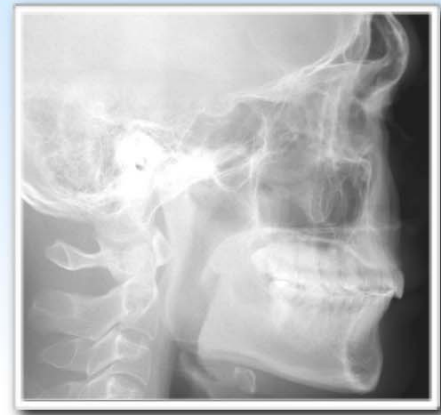
Fig. 8 Posttreatment pano and ceph radiographs

miniscrews (2X12 mm, stainless steel) were implanted on both sides of the infrazygomatic crests to retract the upper posterior segment to a Class I relationship in the 15th month.

The upper archwire was sectioned behind the cuspids one month prior to the completion of treatment. Light up and down elastics (2 oz) were further used for final detailing. Appliances were removed and retainers were delivered. Tooth #30 had a distal marginal chip and was restored with composite resin by the patient's family dentist.

RESULTS ACHIEVED

Maxilla (all three planes):

- A - P: Maintained.
- Vertical: Maintained.
- Transverse: Maintained.

Mandible (all three planes):

- A - P: Maintained.
- Vertical: Maintained.
- Transverse: Maintained.

Maxillary Dentition

- A - P: Retracted upper incisors.
- Vertical: Slightly intruded upper incisors.

CEPHALOMETRIC

SKELETAL ANALYSIS

	PRE-TX	POST-TX	DIFF.
SNA°	84°	84°	0°
SNB°	82°	82°	0°
ANB°	2°	2°	0°
SN-MP°	22.5°	22.5°	0°
FMA°	17°	17°	0°

DENTAL ANALYSIS

U1 TO NA mm	11.5 mm	4 mm	7.5 mm
U1 TO SN°	129°	109°	20°
L1 TO NB mm	4 mm	5 mm	1 mm
L1 TO MP°	101°	108°	7°

FACIAL ANALYSIS

E-LINE	4 mm	2 mm	2mm
--------	------	------	-----

Table. Cephalometric summary

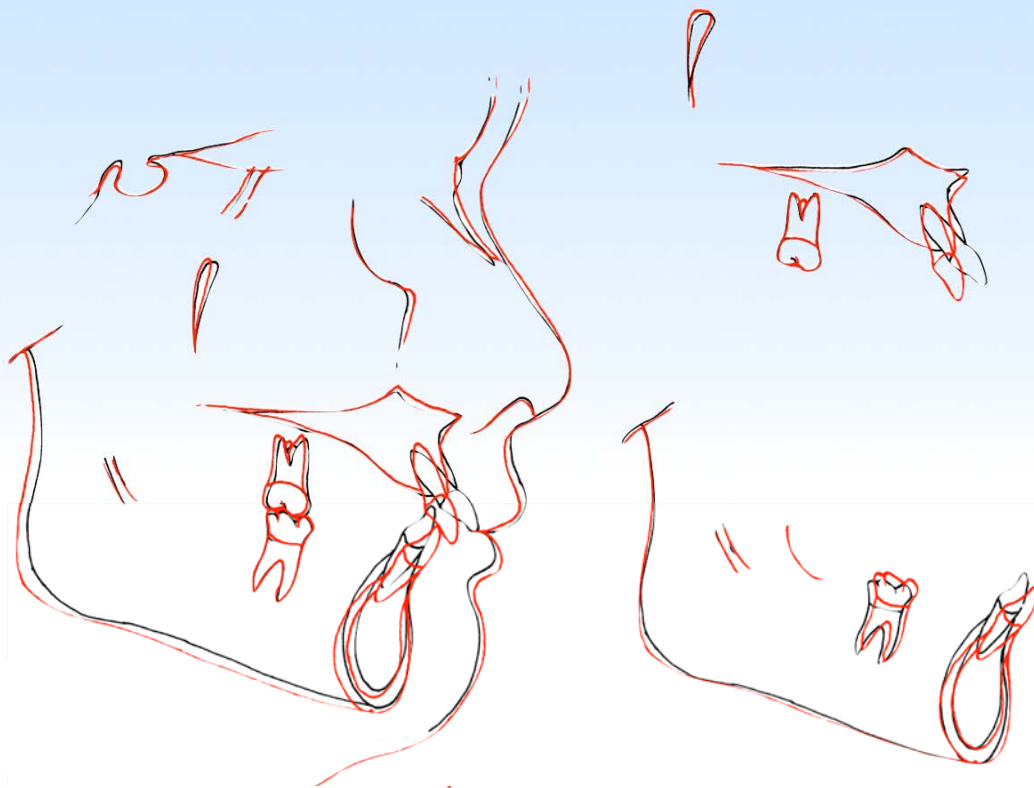


Fig. 9 Superimposed tracings

- Inter-molar Width: Increased 3 mm and #2 buccal crossbite corrected.

Mandibular Dentition

- A - P: Flaring.
- Vertical: Intruded lower incisors.
- Inter-molar / Inter-canine Width: Increased 1.5 mm / Increased 1 mm.

Facial Esthetics: Improved lip profile.

RETENTION

An upper Hawley retainer was delivered. The patient was instructed to wear it full time for the first 6 months and nights only thereafter. The lower fixed 4-4 retainer was bonded on every tooth. The patient was instructed relative to home care and maintenance of the retainers.

FINAL EVALUATION OF TREATMENT

Retraction of upper incisors helped improve the facial balance significantly. The excessive overjet and impinging overbite were reduced but remained slightly greater than ideal. Wearing elastics as instructed was the key to success for this case. Posterior and anterior bite turbos also played important roles.

The buccal cross-bite and anterior overjet were corrected by extensive application of elastics and by the more proclined position of lower incisors. The proclined

position of lower incisors could be avoided by using mandibular miniscrews on the buccal shelf to retract the lower incisors and to hook the Class II elastics or by choosing the low torque anterior brackets at the beginning.

The inter-molar width increased more than expected. The increased inter-molar width and proclined lower incisors will be a challenge for long term stability and the patient will be in close follow up. Overall, there was significant improvement in both dentition and esthetics. The results were acceptable and the patient was satisfied with the treatment.

DISCUSSION

Correction of deep bite and large overjet is difficult in adult patients. There are several considerations needed to be made in order to decide whether to extract premolars or not in these cases. They include facial profile, skeletal pattern, lip protrusion, and growth potential. In this case we chose non-extraction treatment due to a low mandibular angle and straight profile.

Patients with large overjet are usually treated by retraction of upper incisors with headgears, orthodontic bone screws, or elastics. In these patients torque control of upper incisors is often a challenge for orthodontists. In this case Damon's anterior high torque brackets and early light short elastics were used to overcome this problem.

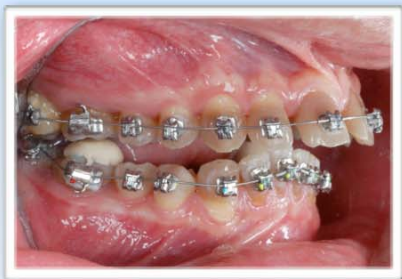

Fig 10. Posterior bite turbos for correction of #2 buccal crossbite

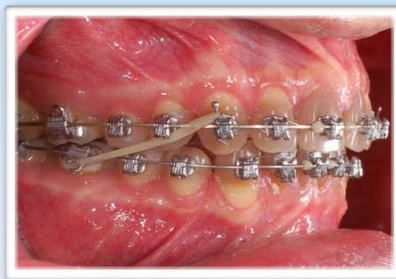

Fig 11. 4.5 oz Bear (10th month)

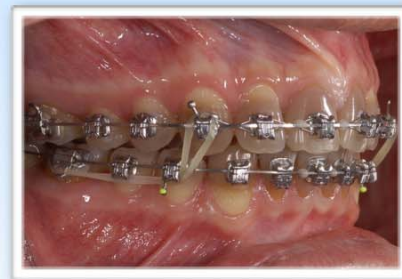

Fig 12. 6 oz Moose (13th month)

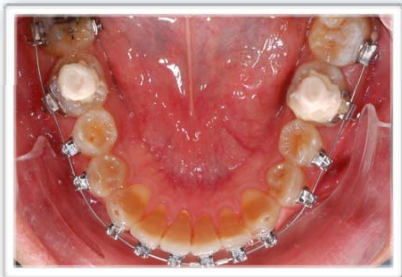


Fig 13. Posterior bite turbos

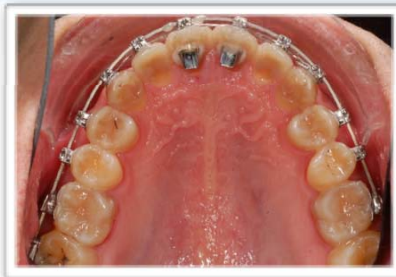

Fig 14. Anterior bite turbos

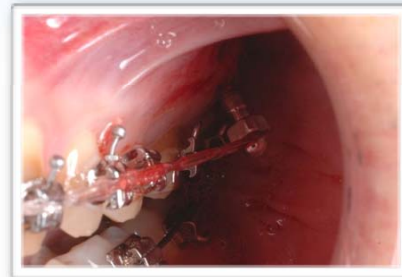


Fig 15. Miniscrews in 15th month

According to Burden's study¹, when using fixed appliances on patients with very large overjet, an excellent outcome can be expected if the upper incisors are quite proclined, which is found in this case.

Correction of deep bite can be achieved by molar extrusion, incisor intrusion or both. However, it is often unstable to use molar extrusion for correcting deep bite in adult patients, because muscles tend to maintain their original length contributing to relapse of the deepbite²⁻³. Therefore, intrusion of anterior incisors is a better choice of treatment for adult patients. There are several useful tools to intrude anterior teeth, such as utility arches, lever arms combined with orthodontic bone screws, and interradicular orthodontic bone screws in the anterior area. Different tools are chosen based on individual situations. Besides tool selection, we should also pay attention to root resorption. According to Burstone's study⁴, 20gm of force is recommended for intrusion of anterior teeth to decrease root resorption. In this case the lower incisors were intruded by anterior bite turbos successfully, and root resorption was not apparent.

Proclination of lower anterior teeth is often seen in the treatment of correcting deep bite and excessive overjet. According to Mills' study⁵, the average amount of "stable" proclination of lower incisors is 1 to 2 mm, and a fixed retainer is also needed. In this case the proclination of lower incisors was 1mm, and we used a lower fixed retainer for long-term stability.

In brief, bite turbos were used with early light short elastics and pre-torqued Damon brackets for correcting impinging overbite and large overjet. The result was satisfactory and the treatment completed in 17 months. The mechanics were relatively simple and efficient. Therefore, we recommend this method for correcting deep bite and large overjet in non-extraction cases. It is important to correct the etiology of the malocclusion by instructing the patient to overlap the upper incisors when closing the lips. Lip trap posture (lower lip between the incisors) must be avoided.

Acknowledgements: Thank Tzu Han Huang and Dr. Grace Chiu to proofread this article.

REFERENCES

1. Donald J. Burden et al: Predictors of outcome among patients with Class II Division 1 malocclusion treated with fixed appliances in the permanent dentition. *Am J Orthod Dentofacial Orthop* 1999;116:452-9
2. Yi-Jane Chen et al: Nonsurgical correction of skeletal deep overbite and Class II Division 2 malocclusion in an adult patient. *Am J Orthod Dentofacial Orthop* 2004;126:371-8
3. Cheol-Ho Paik et al: Correction of Class II deep overbite and dental and skeletal asymmetry with 2 types of palatal miniscrews. *Am J Orthod Dentofacial Orthop* 2007;131:00
4. Burstone CR: Deep overbite correction by intrusion. *Am J Orthod* 1977;72:1-22
5. Mills JR: The stability of the lower labial segment: a cephalometric survey. *Dent Pract Dent Rec* 1968;18:293-306

DISCREPANCY INDEX WORKSHEETCASE # 1 PATIENT CHAO-YUEN CHIUTOTAL D.I. SCORE 25**OVERJET**

0 mm. (edge-to-edge) = 1 pt.
 1 – 3 mm. = 0 pts.
 3.1 – 5 mm. = 2 pts.
 5.1 – 7 mm. = 3 pts.
 7.1 – 9 mm. = 4 pts.
 > 9 mm. = 5 pts.

Negative OJ (x-bite) 1 pt. per mm. per tooth =

Total = 5**OVERBITE**

0 – 3 mm. = 0 pts.
 3.1 – 5 mm. = 2 pts.
 5.1 – 7 mm. = 3 pts.
 Impinging (100%) = 5 pts.

Total = 5**ANTERIOR OPEN BITE**

0 mm. (edge-to-edge), 1 pt. per tooth
 then 1 pt. per additional full mm. per tooth

Total = 0**LATERAL OPEN BITE**

2 pts. per mm. per tooth

Total = 0**CROWDING** (only one arch)

1 – 3 mm. = 1 pt.
 3.1 – 5 mm. = 2 pts.
 5.1 – 7 mm. = 4 pts.
 > 7 mm. = 7 pts.

Total = 1**OCCLUSION**

Class I to end on = 0 pts.
 End on Class II or III = 2 pts. per side pts.
 Full Class II or III = 4 pts. per side pts.
 Beyond Class II or III = 1 pt. per mm. pts.
 additional

Total = 0EXAM YEAR 2009
ABO ID# 96112**LINGUAL POSTERIOR X-BITE**1 pt. per tooth Total = 0**BUCCAL POSTERIOR X-BITE**2 pts. per tooth Total = 2**CEPHALOMETRICS** (See Instructions)ANB $\geq 6^\circ$ or $\leq -2^\circ$ = 4 pts.Each degree $< -2^\circ$ x 1 pt. = Each degree $> 6^\circ$ x 1 pt. = **SN-MP** $\geq 38^\circ$ = 2 pts.Each degree $> 38^\circ$ x 2 pts. = $\leq 26^\circ$ = 1 pt.Each degree $< 26^\circ$ 4 x 1 pt. = 41 to MP $\geq 99^\circ$ = 1 pt.Each degree $> 99^\circ$ 2 x 1 pt. = 2Total = 8**OTHER** (See Instructions)

Supernumerary teeth x 1 pt. =
 Ankylosis of perm. teeth x 2 pts. =
 Anomalous morphology x 2 pts. =
 Impaction (except 3rd molars) x 2 pts. =
 Midline discrepancy (≥ 3 mm) @ 2 pts. =
 Missing teeth (except 3rd molars) x 1 pts. =
 Missing teeth, congenital x 2 pts. =
 Spacing (4 or more, per arch) x 2 pts. = 2
 Spacing (Mx cent. diastema ≥ 2 mm) @ 2 pts. = 2
 Tooth transposition x 2 pts. =
 Skeletal asymmetry (nonsurgical tx) @ 3 pts. =
 Addl. treatment complexities x 2 pts. =

Identify:

Total = 4

Exam Year	2009
ABO ID#	96112

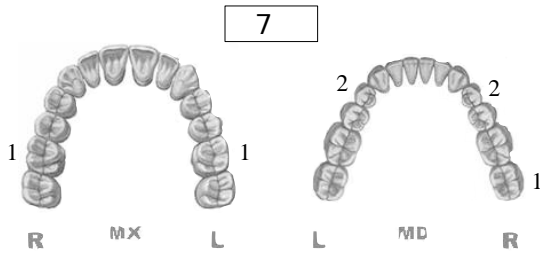
Examiners will verify measurements in each parameter.

ABO Cast-Radiograph Evaluation (Rev.6-1-08)

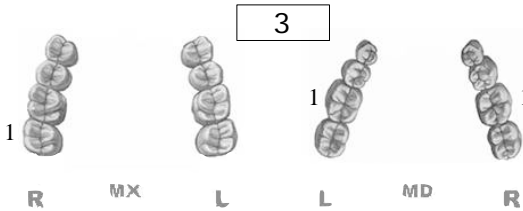
Case # Patient

Total Score:

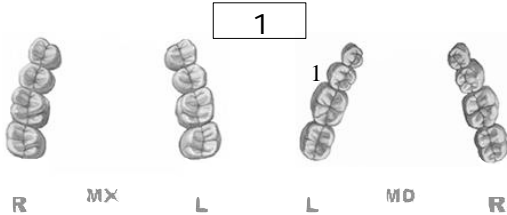
Alignment/Rotations



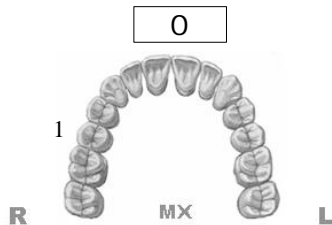
Marginal Ridges



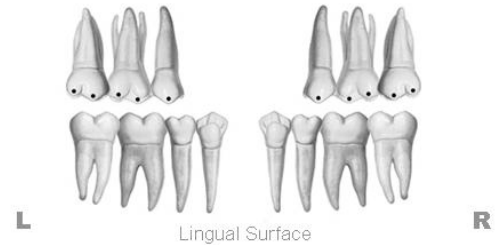
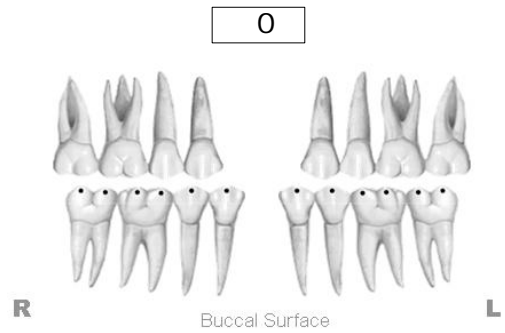
Buccolingual Inclination



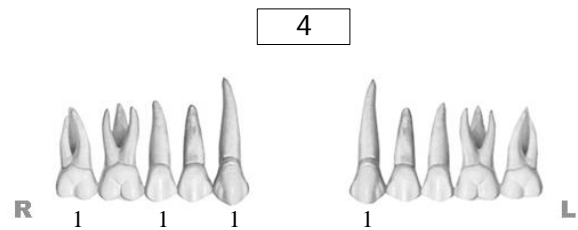
Overjet



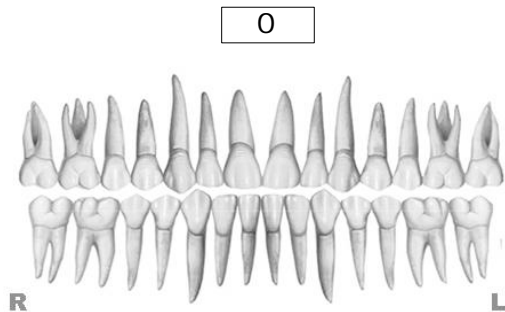
Occlusal Contacts



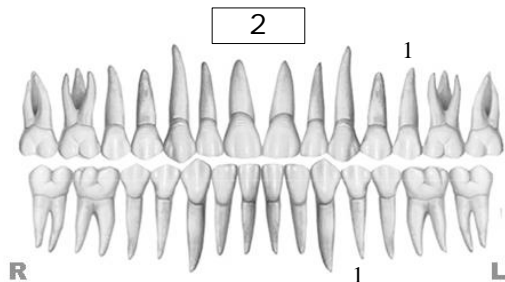
Occlusal Relationships



Interproximal Contacts



Root Angulation



INSTRUCTIONS: Place score beside each deficient tooth and enter total score for each parameter in the white box. Mark extracted teeth with "X". Second molars should be in occlusion.



Treating Anterior Open Bite with Early Light Short Elastics

The patient was a 16-year-old Asian girl whose chief concern was “My front teeth do not touch.” Oral soft tissues, frena, and gingival health were all within normal limits. Oral hygiene was excellent. Medical and dental histories were unremarkable.

DIAGNOSIS AND ETIOLOGY

Pretreatment facial photographs showed a straight profile with slightly protrusive lips. The pretreatment intraoral photographs and study models revealed bilateral Class I molar relationships, lower dental midline 2 mm to the right of the facial midline, 1.5 to 2 mm anterior open bite from the right to left first bicusps, as well as maxillary and mandibular anterior segment spacing. The patient had a thumb sucking habit until age 11. Tongue thrust swallowing and interdental tongue posturing were subsequently noted. The constant posturing of the tongue between the incisors appeared to be the primary etiology of her anterior open bite. The panoramic radiograph showed 4 impacted third molars.

Cephalometric analysis shows skeletal Class I and normal mandibular plane angle with a 2-mm anterior open bite. The ANB angle was 4° , and the SN-MP angle was 32° . The lower incisor to Md plane angle was excessive, at 106° . The cephalometric values are summarized in the Table. The total score American Board of Orthodontics (ABO) of Discrepancy Index was 24, as seen on the DI worksheet.



Fig 1. Pretreatment facial photographs

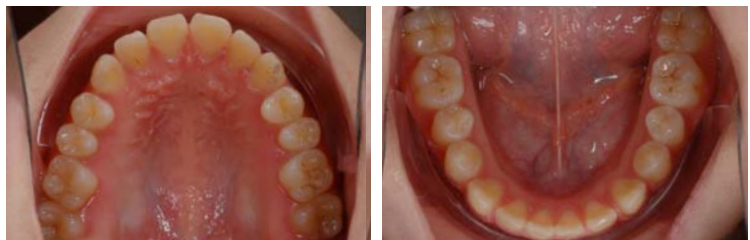
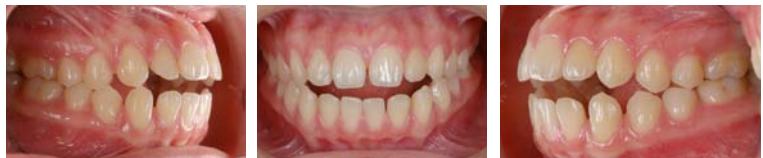
Fig 2. Pretreatment intraoral photographs

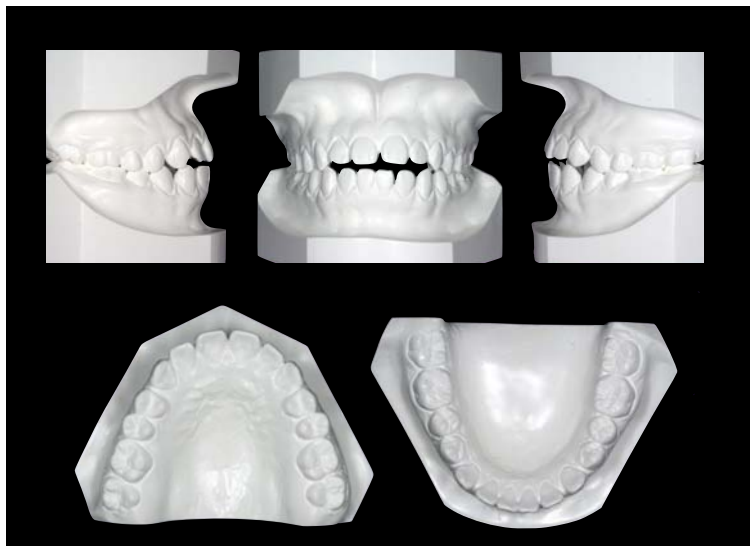

Fig 3. Pretreatment study models

Dr. Chris HN Chang, Director, Beethoven Orthodontic Center (middle)

Dr. Billy Su, Lecturer, Beethoven Orthodontic Course (right)

Dr. Eugene W. Roberts, Consultant, News and Trends in Orthodontics (left)





Fig 4. Posttreatment facial photographs (17 M)

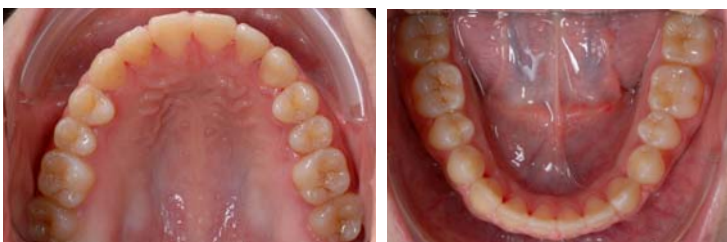
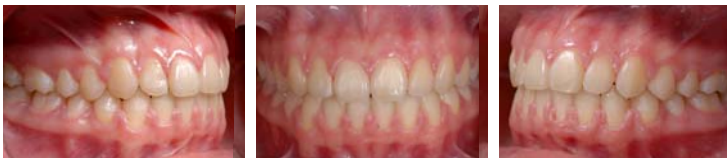
Fig 5. Posttreatment intraoral photographs (17 M)

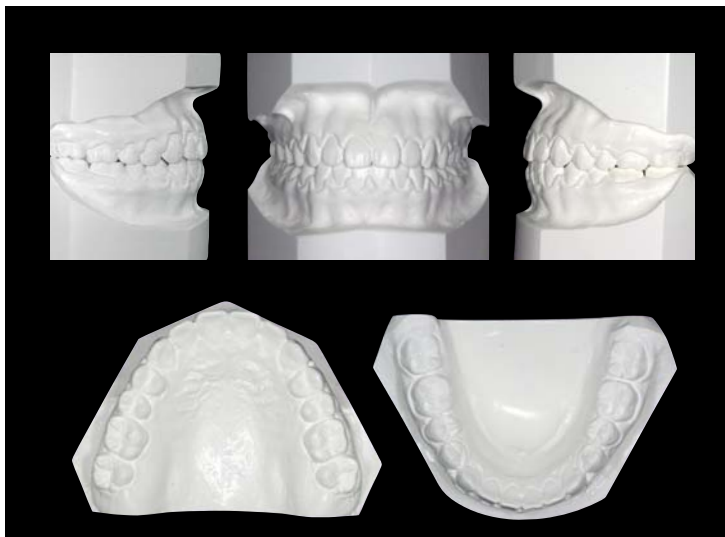

Fig 6. Posttreatment study models (17 M)

Many theories explain the possible causes of anterior open bite malocclusion, including digital habits, airway obstruction, tongue posture, unfavorable growth, and inherited facial form. In this patient the etiology was believed to be a combination of thumb sucking habit followed by habitual interdental tongue posture.

TREATMENT OBJECTIVES

The primary objective of treatment was to attain Class I molar and canine relationships with ideal overjet and overbite while retracting upper and lower lips. Specific treatment objectives were to :

- Maintain the skeletal position of the maxilla and the mandible.
- Avoid extrusion of the molars and clockwise rotation of the mandible during treatment.
- Extrude and retract the maxillary and mandible incisors.
- Close the anterior open bite, align the midlines, and provide proper overjet and overbite in a mutually protected, Class I occlusion.
- Retract upper and lower lips.
- Correct the tongue posture habit.

TREATMENT ALTERNATIVES

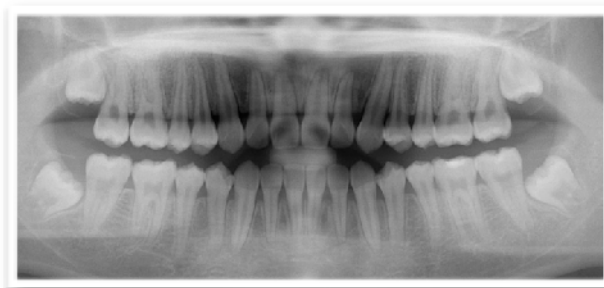
The patient's chief concerns were the anterior open bite and her inability to incise food. Because of the protrusive lips, an orthognathic surgical treatment option was discussed, but the patient deemed it too

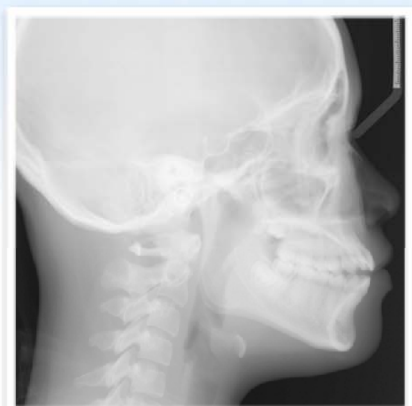

Fig. 7-8.
Pretreatment
pano and ceph
radiographs

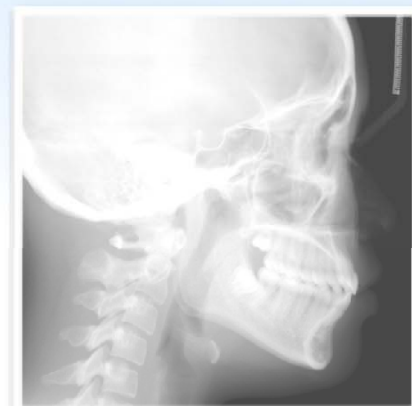
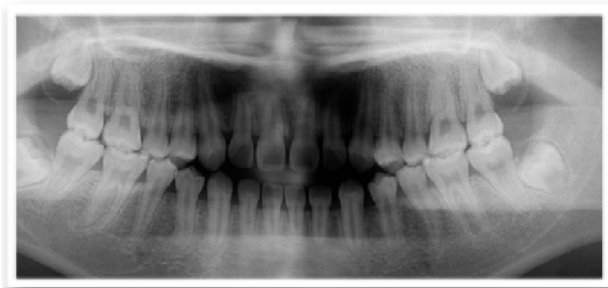
Fig. 9-10.
Posttreatment
pano and ceph
radiographs



aggressive. Thus a nonsurgical plan was devised to close the open bite and alleviate the patient's chief complaint. Non-extraction treatment was recommended. Anterior early light short elastics were used to correct the anterior open bite. Tongue spurs were used to correct the tongue posture and associated tongue thrust swallowing pattern. Squeeze exercise with chewing gum was recommended to intrude posterior segments. Apply Class II elastics was used to correct the sagittal discrepancy and the occlusion was detailed with finishing bends. Fixed appliances were removed and the occlusal correction was maintained with upper and lower fixed retainers in conjunction with an upper Hawley retainer.

TREATMENT PROGRESS

0.022-in Damon D3MX brackets (Ormco Corporation) were used. Both arches, including the lingual spurs on the lower anterior teeth, were bonded.

CEPHALOMETRIC

SKELETAL ANALYSIS

	PRE-TX	POST-TX	DIFF.
SNA°	84°	84.5°	0.5°
SNB°	80°	79.5°	0.5°
ANB°	4°	5°	1°
SN-MP°	32°	31.5°	0.5°
FMA°	25°	24°	1°

DENTAL ANALYSIS

U1 TO NA mm	5.5 mm	3 mm	2.5 mm
U1 TO SN°	110°	104°	6°
L1 TO NB mm	9.5 mm	7 mm	2.5 mm
L1 TO MP°	106°	94°	12°

FACIAL ANALYSIS

E-LINE	2 mm	2 mm	0 mm
--------	------	------	------

Table. Cephalometric summary

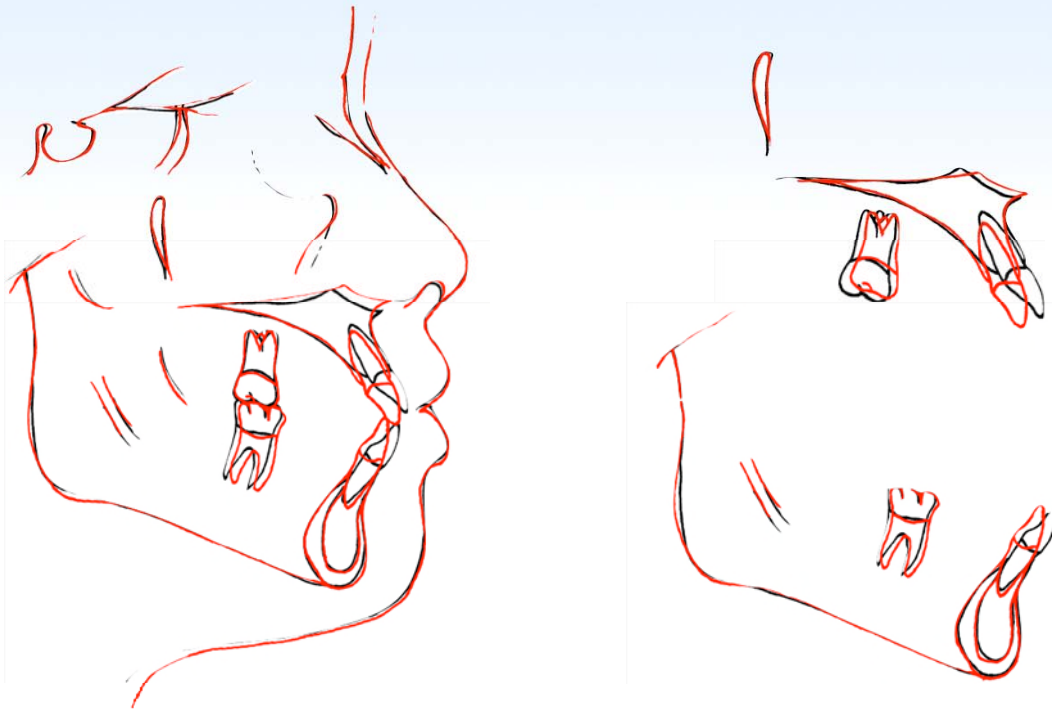


Fig 11. Superimposed tracings

The patient was instructed to wear anterior vertical (“up and down”) elastics (2 oz) full time at the start of active treatment. One month later, she was trained to lift the tongue tip to touch the hard palate and practice the squeeze exercise for 2 hrs / day to correct the low tongue posture and tongue thrust. She was cooperative and enjoyed the training. In the 5th month, a .016 x .025 copper NiTi with 20° pretorqued wire was used for the torque control of upper anterior segment. In the 6th month, a panoramic film was taken to further examine the root parallelism and repositioned the brackets. The wire sequences were as follows: .014 copper NiTi, .014 x .025 copper NiTi, .016 x .025 upper 20° pretorqued copper NiTi wire, .019 x .025 upper 20° pretorqued copper NiTi wire and .017 x .025 TMA. The Class II elastics were upgraded gradually from 2 oz, 3.5 oz, 4.5 oz to 6 oz respectively. The spaces were closed by power chains on a .017 x .025 TMA. The upper archwire was sectioned behind cuspids one month prior to the

completion of treatment. Light vertical (2 oz) were used for final detailing. Appliances were removed and retainers were delivered.

TREATMENT RESULTS

The overall results were acceptable, thanks in part to excellent patient cooperation with tongue posture training, intraoral elastics and optimal oral hygiene. Facial harmony and lip closure were improved. Posttreatment intraoral photographs and study casts showed bilateral Class I molar and canine relationships. Both dental midlines were aligned with the facial midline. Ideal overjet and overbite were achieved.

Cephalometric analysis and superimpositions showed no skeletal changes in the maxilla or the mandible. The upper incisor to the SN angle was from 110° to 104°. The lower incisor to the Md plane angle was from 106° to 94°. Critical assessment of this case with current ABO

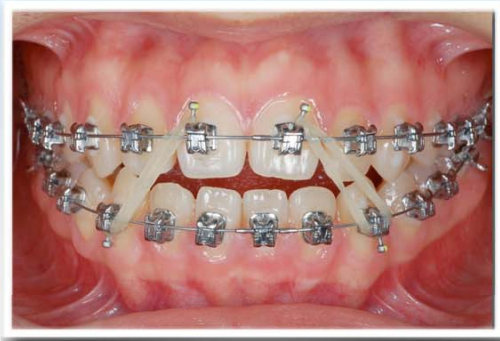

Fig. 12. 3 M during tx, 1/4 inch 3.5 oz Fox, U1-L3.

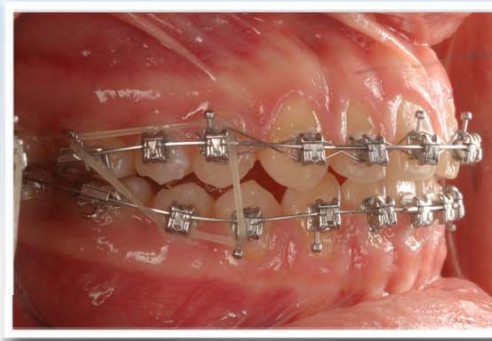

Fig. 14. 10 M during tx, 1/4 inch 4.5 oz Bear, Box U456-L45.

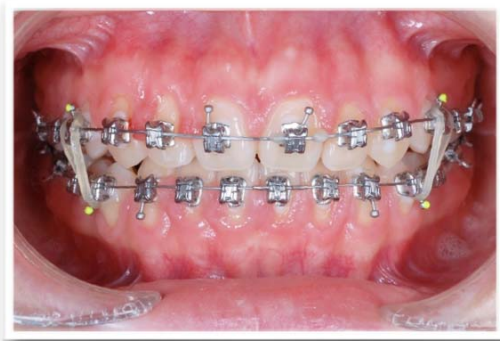

Fig. 13. 5 M during tx, 1/4 inch 4.5 oz Bear, U3-L3.

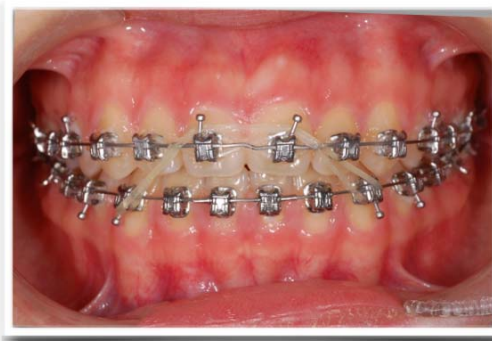


Fig. 15. 15 M during tx, 3/8 inch 3.5 oz Monkey, L3-U11-L3.

outcome standards showed the following deviations from ideal:

1. The maxillary right and left second molars exhibit excessive distal rotation.
2. The marginal ridge discrepancies exist between #3 #4, #14 #15, and #29 #30 #31.
3. The Mandibular right second premolar exhibits excessive buccal root torque.
4. The buccal cusps of the maxillary canines, second premolars are shifted mesially about 1~2 mm relative to the interproximal embrasures of the mandibular posterior teeth. The mesiobuccal cusps of the maxillary second molars shifted mesially about 1.5 mm to the buccal groove of the mandibular first molars.
5. The mandibular right and left first premolars need slightly more distal root movement.

The total score for the cast and panoramic radiograph grading system was 20, as seen on the Objective Grading System (OGS) worksheet¹. This score is well within the maximal allowable score of 26.

DISCUSSION

Success with a nonsurgical plan is complicated by the fact that most orthodontic mechanotherapy extrudes the teeth, resulting in a clockwise rotation of the mandible and lengthening of the face². The other concern is stability and retention. Over a third of the cases involving nonsurgical correction of open bite show significant posttreatment relapse³. Relapse is most likely in young patients, who often exhibit posttreatment vertical growth and posterior dental eruption. The patient must be told that the nonsurgical treatment often requires more time to complete and is more difficult, especially for stability and retention. The interdental tongue posture habit must be maintained by the patient⁴.

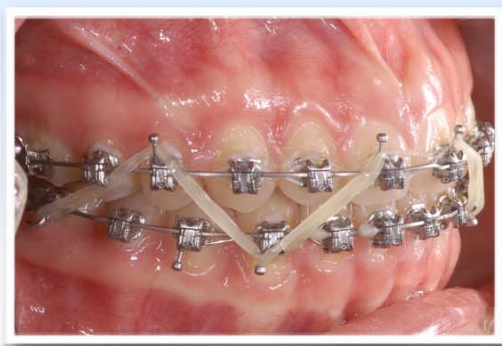

Fig. 16. 17M during tx, 3/8 inch 3.5 oz Monkey L6-U4-L3,

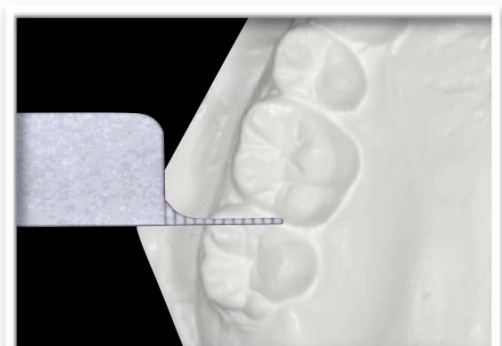


Fig. 17. #2 distal rotation, central groove discrepancy was noted between #2, #3.

Correcting the tongue habit and wearing elastics as instructed were the keys to correction of the patient's anterior open bite. Anterior early elastics must be used with a light force so that they would not produce a dumping effect on the anterior segments. The upper 20° pretorque copper NiTi wire was also helpful in keeping the upper anterior lingual root torque. Bonded tongue spurs and muscle exercises played important roles in this open bite correction. Miniscrews which provided maximal anchorage were not used to hold or to distalize the posteriors because lip profile was not her concern. The patient and her parents were satisfied with the final results. Long-term stability will be the challenge for this case. The patient was instructed to continue the tongue posture training and squeeze exercises. She will be followed closely with follow-up evaluations.

In conclusion, this case demonstrates that the successful open bite correction can be attained by simple mechanics

ELASTICS			
WIRE SEQUENCE	ELASTICS	DIRECTION	DURATION
14 NiTi	3/16 inch 2 oz Quail	U1-L3	Full time
14 x 25 NiTi	1/4 inch 3.5 oz Fox	U1-L3	Full time
16 x 25 U 20° PreQ NiTi	1/4 inch 4.5 oz Bear	U3-L3	Full time
19 x 25 U 20° PreQ NiTi	1/4 inch 4.5 oz Bear	Box U456-L45	Full time
17 x 25 TMA	3/8 inch 3.5 oz Monkey	L3-U11-L3	Full time
17 x 25 TMA	1/4 inch 3.5 oz Fox 3/8 inch 3.5 oz Monkey	U1-L3 L3-U4-L6	Full time

Table. Elastic sequence

and muscle posture exercises to eliminate the etiology of this special type of malocclusion.

ACKNOWLEDGEMENTS

Special thanks to our associate editors, Tzu Han Huang, Dr. Grace Chiu and Dr. Sarina Huang for English revision.

REFERENCES

1. Casco JS, Vaden JL, et al. Objective grading system for dental casts and panoramic radiographs. *Am J Orthod Dentofacial Orthop* 1998;114:589-99.
2. Linder-Aronson S, Woodside D. Excess facial height malocclusion etiology, diagnosis, and treatment. Chicago: Quintessence; 2000. p. 1-24.
3. Denison TF, Kokich VG, Shapiro PA. Stability of maxillary surgery in open bite versus nonopen bite malocclusions. *Angle orthod* 1989;59:5-10
4. Hiller ME. Nonsurgical correction of Class III open bite malocclusion in an adult patient. *Am J Orthod Dentofacial Orthop* 2002;122:210-6.

DISCREPANCY INDEX WORKSHEET

TOTAL D.I. SCORE

24

OVERJET

0 mm. (edge-to-edge)	=	1 pt.
1 – 3 mm.	=	0 pts.
3.1 – 5 mm.	=	2 pts.
5.1 – 7 mm.	=	3 pts.
7.1 – 9 mm.	=	4 pts.
> 9 mm.	=	5 pts.

Negative OJ (x-bite) 1 pt. per mm. per tooth =

Total

0

OVERBITE

0 – 3 mm.	=	0 pts.
3.1 – 5 mm.	=	2 pts.
5.1 – 7 mm.	=	3 pts.
Impinging (100%)	=	5 pts.

Total

0

ANTERIOR OPEN BITE

0 mm. (edge-to-edge), 1 pt. per tooth
then 1 pt. per additional full mm. per tooth

Total

16

LATERAL OPEN BITE

2 pts. per mm. per tooth

Total

0

CROWDING (only one arch)

1 – 3 mm.	=	1 pt.
3.1 – 5 mm.	=	2 pts.
5.1 – 7 mm.	=	4 pts.
> 7 mm.	=	7 pts.

Total

0

OCCLUSION

Class I to end on	=	0 pts.
End on Class II or III	=	2 pts. per side _____pts.
Full Class II or III	=	4 pts. per side _____pts.
Beyond Class II or III	=	1 pt. per mm. _____pts. additional

Total

0

LINGUAL POSTERIOR X-BITE

1 pt. per tooth

Total =

0

BUCCAL POSTERIOR X-BITE

2 pts. per tooth

Total =

0

CEPHALOMETRICS

(See Instructions)

ANB $\geq 6^\circ$ or $\leq -2^\circ$ = 4 pts.

Each degree $< -2^\circ$ _____ x 1 pt. = _____

Each degree $> 6^\circ$ _____ x 1 pt. = _____

SN-MP

$\geq 38^\circ$ = 2 pts.

Each degree $> 38^\circ$ _____ x 2 pts. = _____

$\leq 26^\circ$ = 1 pt.

Each degree $< 26^\circ$ _____ x 1 pt. = _____

1 to MP $\geq 99^\circ$ = 1 pt.

Each degree $> 99^\circ$ 7 x 1 pt. = 7

Total

8

OTHER

(See Instructions)

Supernumerary teeth	_____ x 1 pt. = _____
Ankylosis of perm. teeth	_____ x 2 pts. = _____
Anomalous morphology	_____ x 2 pts. = _____
Impaction (except 3 rd molars)	_____ x 2 pts. = _____
Midline discrepancy (≥ 3 mm)	@ 2 pts. = _____
Missing teeth (except 3 rd molars)	_____ x 1 pts. = _____
Missing teeth, congenital	_____ x 2 pts. = _____
Spacing (4 or more, per arch)	_____ x 2 pts. = _____
Spacing (Mx cent. diastema ≥ 2 mm)	@ 2 pts. = _____
Tooth transposition	_____ x 2 pts. = _____
Skeletal asymmetry (nonsurgical tx)	@ 3 pts. = _____
Addl. treatment complexities	_____ x 2 pts. = _____

Identify:

Total

0

Exam Year
ABO ID#

2009
96112

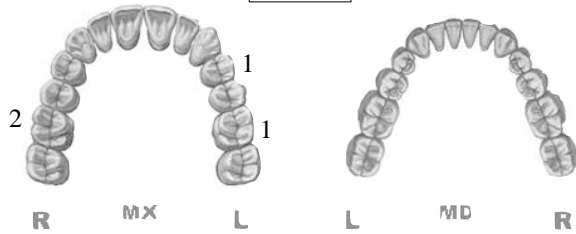
Examiners will verify measurements in each parameter.

ABO Cast-Radiograph Evaluation (Rev.6-1-08)

Total Score: 20

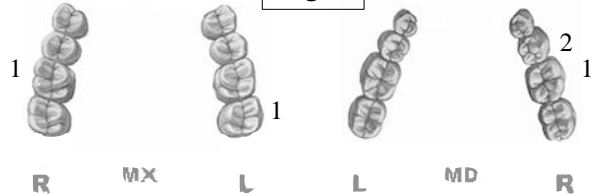
Alignment/Rotations

4



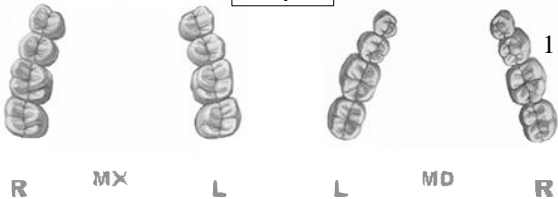
Marginal Ridges

5



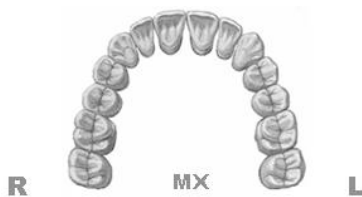Buccolingual Inclination

1



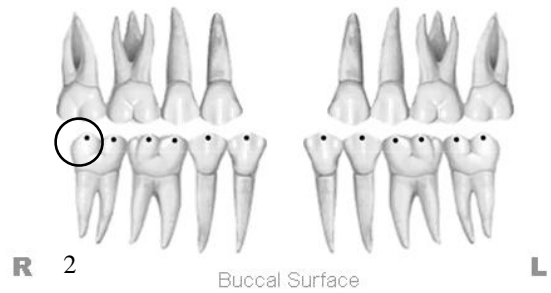
Overjet

0



Occlusal Contacts

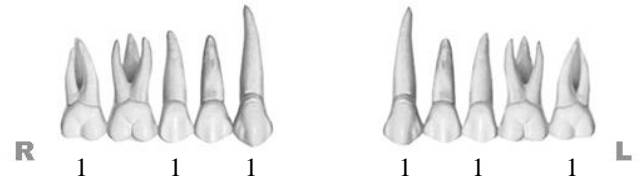
2



Buccal Surface

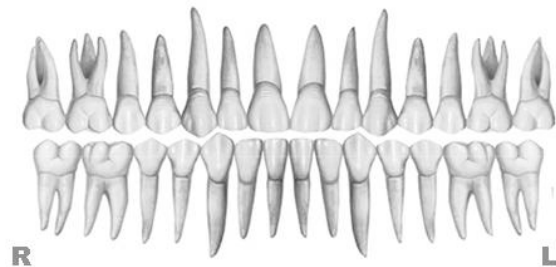
Occlusal Relationships

6



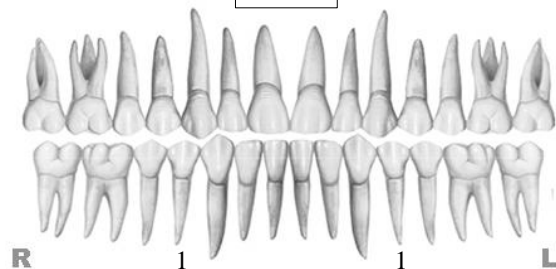
Interproximal Contacts

0



Root Angulation

2



INSTRUCTIONS: Place score beside each deficient tooth and enter total score for each parameter in the white box. Mark extracted teeth with "X". Second molars should be in occlusion.





Dr. Roberto Justus on Finishing

-The Standard of American Board of Orthodontics

WFO 致力於提升全世界矯正治療水準與促進矯正研究與交流，要讓大家知道必須達到哪些標準，才算是好的矯正治療，並將這些準則運用到日常臨床工作上。怎樣才算是 excellent finishing？世界各國各自有一套審查標準，到底那個才是最完整的呢？

• 客觀檢驗矯正治療

美國矯正專科審查會 (ABO) 歷經 4 年的時間，從上千位受試者治療完成的石膏模型與全口 X 光片中，訂出八個主要常見的錯誤：Alignment/rotations、Marginal ridges、Buccolingual inclination、Occlusal contacts、Occlusal relationships、Overjet、Interproximal contacts、Root angulation 等八項。為了能客觀且精確的測量，ABO 設計出專用的測量工具來評測這八個項目 (Fig. 1)，並建立起一套完整客觀的評分標準，來評定受試者是否能成為矯正專科醫師，這個方法稱為 Objective Grading System for Dental Casts and Panoramic Radiographs。

除此之外，治療前 ABO Discrepancy Index 困難度分析、X 光片 tracing 與 superimposition Skeletal dental facial analysis、臨床相片、治療紀錄的詳盡程度與品質如何都要列入審查評定範圍。這方法是目前全世界最完整、最嚴謹、最客觀公平的評測方式，來評定矯正完成的品質，以後全世界都會用這套標準來檢驗矯正結果。

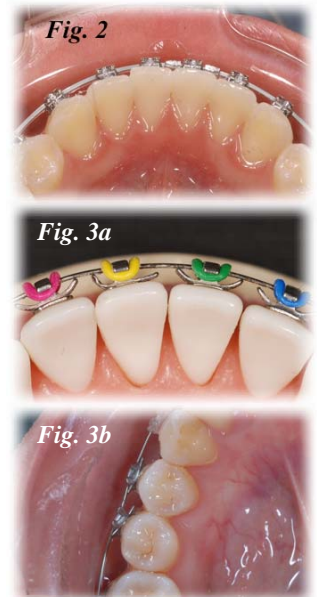• 常見錯誤原因

若以 Dr. Justus 的觀點而言，我們都不是完美的矯正醫師，因為做得不夠好，還是會犯很多錯誤。這些錯誤經常肇因於矯正器黏的位置不對，第二大臼齒沒上矯正器或只會用 straight wire 不會彎線等。

• 有效控制旋轉 (rotation)

受試者在 Alignment/rotations 項目中經常被扣分，因為使用 twin bracket 還是有約 10 % 的 rotation 無法完全改正 (Fig. 2)，必須配合 wire bending 才行。

Dr. Justus 認為，Lewis bracket 有兩個 wing，只要調整兩側 wing 的高低位置，比 twin bracket 更容易改正 rotation 並可額外做些 over rotation (Fig. 3)。而且 inter-bracket distance 比 twin bracket 長，wire 彈性更好 (wire 的長度每增加一倍，彈性會增加為立方倍，亦即若長度增為 2 倍，彈性會增為 8 倍)，這對 crowding 下顎前牙的 derotation 很有幫助。有時前牙 crowding 無法將 bracket 黏到牙齒的 long axis 時，可以將會碰到的 wing 修掉，去除干擾且可做些 over-correction。Rotation wedge 並無法真正改正 rotation，因為他是用 wedge 效應將牙齒推向內側，有時還必須做 mesial / distal offset bending 才能達到真正的 derotation，且 wire bending 後容易造成鄰牙 rotation。



• Circumferential fiberotomy

Rotation 的牙齒治療完後非常容易有 relapse 的情況，可以做 over-correction 或配合 circumferential fiberotomy 效果更好。Circumferential fiberotomy 是繞著牙齒周圍，從 gingival sulcus 直接切到 alveolar crest 上，切

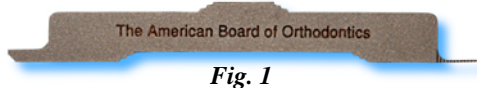

Fig. 1

蔡鎰隆 醫師
誠品、長春牙醫診所
貝多芬矯正課程講師



斷牙齒跟牙齒間的 transseptal fiber，可減少約 30%~50% rotation relapse 的機會。

• Retainer & Stability

Dr. Justus 認為用 fixed retainer 的患者，約 90% 曾經發生脫落的情況，其他研究顯示 3 到 3 fixed retainer 2 年內的失敗機率約 20%，而且很容易看到 rotation relapse 甚至 space 出現。為什麼前牙容易發生 relapse？根據研究，移除維持器後 inter-canine width 會有一直變小的傾向，incisors liability 會變大。該如何避免 rotation relapse 的發生呢？首先一定要有足夠 space，並且在矯正時做 over-correction，拆除矯正器後做 circumferential fiberotomy 以及確實戴 retainer。Dr. Justus 喜歡用全口活動式維持器，請患者長期晚上戴，根據 20 年長期追蹤的結果發現維持效果不錯。

• 第二大臼齒輕鬆黏著

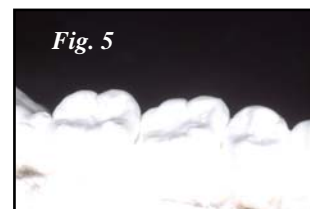第二大臼齒在許多項目中經常被扣分，通常是因位置關係不容易上 band，bonding 也容易脫落，而且不好放 wire。Dr. Justus 建議 bonding 時可以用 Fuji ORTHO LC (Fig. 4)，它是 hydrophilic 比較不怕口內濕氣，而且可釋放氟離子預防蛀牙。但因為它的 bonding strength 較差，所以很多醫師不喜歡用。Dr. Justus 認為 bonding 失敗的原因，是因為牙齒表面 etching 不好的關係，他建議用小毛刷沾 5.25% 的 NaOCl 塗在牙齒表面一分鐘，不要沾到牙齦，去除牙齒表面的蛋白質附著物 (pellicle) 後再 etching，可使 Fuji Ortho LC 增加約三成的 bonding strength，約可接近於樹脂的強度。如果 wire 不好放時，可以從末端放入，但這需要一些 bending 技巧。



Fig. 4

• Marginal Ridge 的重要性

相鄰的 marginal ridges 必須等高，因為 marginal ridges 是與對咬牙相接觸的地方，等高代表能提供對咬牙最佳的咬



合位置。健康的齒列中 marginal ridge 一致，代表 CEJ 也在同一位置，其所支持的 bone level 也在同一位置，達到最佳牙周情況。Marginal ridge 不等高時，容易導致與鄰牙 bone level 的高低差，產生牙周疾病，Marginal ridge 的重要性不容小覷。

• 牙根平行的重要性

拔牙的患者特別要注意牙根平行性，平行的牙根可獲得較佳的穩定性、咬合功能、牙周健康與美觀。雖然利用 pano 檢查牙根是否平行並不是最好的方式，但已經可提供足夠資訊。一定要養成治療中拍 pano 的習慣，治療品質才會好。治療後的 pano 也相當重要，因為包括患者本身、患者家人、矯正醫師自己、X 光技師、牙科助理、轉診的一般牙醫師、假牙醫師、牙周病醫師、植牙醫師、口腔外科醫師、根管治療醫師等都會看到，若發生醫療糾紛法官也會看 pano，可見拍 pano 與牙根平行的重要性。希望大家能注重牙根的平行性，讓大家都知道你是一位好矯正醫師。

• 結論

Dr. Justus 希望大家了解 ABO 八項準則，它是矯正醫師最熟悉但也是最常忽視的地方。我們要了解這些地方的重要性與必要性，改正常犯的錯誤，達到大家公認的 Excellent finish。Dr. Justus 也提供一些自己的臨床技巧及改進方法，希望大家能真正將這些落實到臨床患者治療上，以提高矯正治療水準，讓患者得到最佳醫療品質。





Feedback on Dr. Chris Chang's

On Jan 21, Dr. Chris Chang was invited by Dr. Tom Pitts to give a lecture of how to make effective presentation with Keynote. Billy Su and I were pleased to have the honor to be his assistants to help Dr. Pitts and his members of the Progressive Study club. We shared a wonderful morning. I invited three of the members to write an essay about their impressions on the Keynote workshop. Sabrina Huang

1 Dr. Chris Chang presented a Keynote Workshop for members of our Progressive Study Club at the Damon Forum in January 2009. His workshop consisted of a prepared Keynote presentation he created to teach all of the basic and some advanced techniques in creating a Keynote presentation. I thought his presentation and the method in which he then taught Keynote was a unique and an effective technique. We would look at a slide, analyze what he had done to create that particular slide, then proceeded through the steps to duplicate the slide and go through the process of learning these techniques. Chris has a definite philosophy of creating presentations. He prefers all presentations to be simple and interesting. He emphasized that creating too many lines of text is not effective. It is too hard to read and does not get across his message. From a novice standpoint, this was an excellent method of teaching. The problem that I saw after completing this workshop was it was difficult to recreate on my own without Chris and his capable assistants. I would have loved to

see written directions starting from step 1 to finish that I could refer back to a later time. I did not have a difficult time at the workshop learning the technique, it was only after the workshop that I found that I could have used some written manual.

Overall, I appreciated Dr. Chris Chang, Dr. Sabrina Huang and Dr. Billy Su guidance to learn Keynote. It was quite an extensive course in a half day and it would be quite valuable to someone who is just learning Keynote or someone who is really adept at Windows Power Point. Thank you for your time and instructions, we will hopefully make you proud as we present at different venues.

Dr. Errol Yim, USA



Keynote Workshop in Phoenix



2 I have admired Dr Chang's presentation and educational style as well as his graphic slides for some time now. I made a commitment to change from my Windows computer to an

Apple. Knowing that Chris was going to attend the Forum in Phoenix, I ask him to give us instruction on the use of Keynote for my study group members.

Needless to say he came with a very great presentation and thorough instructions outline.



He also generously brought you, and three other people to help in this endeavor. I was not only impressed with Dr. Chang's instruction, but with all of the giving attitudes of the various instructors.

It was a pleasure to be part of it and to now be using my new Apple with Keynote. I know all of the attendees are now using Keynote. I grade the session as an A+.

Thank you Sabrina & Billy for all of your help in this endeavor and for sending follow-up info via email and actually putting into slides the methodology for review.

Dr. Tom Pitts,, USA

3 I had the pleasure of meeting Dr. Chris Chang last summer in Spain at Dr. Tom Pitts' Progressive Study Club. I found him to be a unique and engaging fellow, intelligent, and particularly funny. The fact that he likes golf instantly drew me to him, because I also enjoy the game. Chris gave a wonderful presentation at the meeting in Spain, one like I had never seen before. I had only used PowerPoint to give lectures before this, and what he amazed me about his presentation was the degree of sophistication and beauty with which he gave his. Of course, I am speaking of Apple's Keynote. Chris is a master at making presentations with this tool that are clear and concise and that keep the attention of the audience. Because of his skill with Keynote, Dr. Pitts asked Chris to come to the Damon Forum in Phoenix, Arizona in January to put on a short course in Keynote for anyone interested in mastering this wonderful tool. Of course, I had to have the same computer as Chris, so when I got home I bought a MacBook Air and an iPhone.

On the Wednesday before the Damon Forum began we met with Chris and several bright and helpful young orthodontists who came with him to lend their aid to this teaching experience. This course was merely a long distance extension of the course he teaches at his Newton's Apple in Taiwan. For many of us who have used PowerPoint sparingly,

his team took us through the basics of how to get started with Keynote and how to navigate the toolbar. Of course, we had to customize the toolbar, so Chris taught us which Icons to use and where to place them. Next, we went through shortcuts that make creating presentations easier. His staff spent individual time with each of us as we went through the process of creating, duplicating, masking, moving, and animating. They were all very patient with us, and spent enough one-on-one time that we could master the concepts. In one morning, Keynote opened its doors to us, and giving presentations will never again be the same.

Chris Chang and his staff are true givers, and I would advise anyone who has the opportunity to take a course from him to do so. Keynote is a tool far better than anything else on the market, and once you have seen it you will agree. I want to thank Chris for taking his time to come so far to teach his new American friends this wonderful technique.

Dr. J. Michael Steffen, USA





Newton's A

金牛頓藝術科技

2009春夏季課程表

類型	課程名稱	內容	開課日期	上課對象
入門推廣	Mac OS X 蘋果電腦新手入門	Mac OS X	4/4, 5/2 (六) 15:00~16:00	樂於嘗試生活科技應用者
入門推廣	iWork系列： 簡單上手的多媒體簡報	Keynote	4/11, 5/9 (六) 15:00~16:00	樂於嘗試生活科技應用者
入門推廣	iLife系列： 多采iPod影音生活	iPod + iTunes	4/18, 5/16 (六) 15:00~16:00	樂於嘗試生活科技應用者
入門推廣	iLife系列： 免費 個人隨身秘書	iCal + Address Book	4/25 (六) 15:00~16:00	樂於嘗試生活科技應用者
專業簡報	Keynote 簡報法 series 1 簡報聖經	1. Keynote入門 2. 常見簡報問題	6月11日(四) 09:00~17:00	科技人、醫師、教師、學生
專業簡報	Keynote簡報法 series 2 Dr. Kokich的十大秘訣	1. 多媒體簡報製作 2. 簡報演練	7月23日(四) 09:00~17:00	科技人、醫師、教師、學生
專業簡報	Keynote簡報法 series 3 掌握賈伯斯的演講祕訣	1. 簡報設計 2. 演說技巧	4月16日(四) 09:00~17:00	科技人、醫師、教師、學生
International	Keynote, OBS & Damon Workshop	Keynote, Management OrthoBoneScrew & Damon	6/29 ~ 7/02	International Dentists
青少年簡報	蘋果魅力簡報生活營	iLife + iWork 文書、簡報、影音製作	8.1 (六)~8.2(日)	12-18歲之學生及家長
臨床見習	牙醫生臨床見習營	1. 臨床觀摩見習 2. 蘋果科技在牙科之應用	8.13(四)~8.15 (六)	全國牙醫系四升五學生

注意事項：上課期間欲租借教學用電腦，酌收維護費200元。

上課地點：金牛頓藝術科技教育中心（交大華廈2樓）新竹市建中一路25號（巴士馬偕醫院下車步行5分鐘）

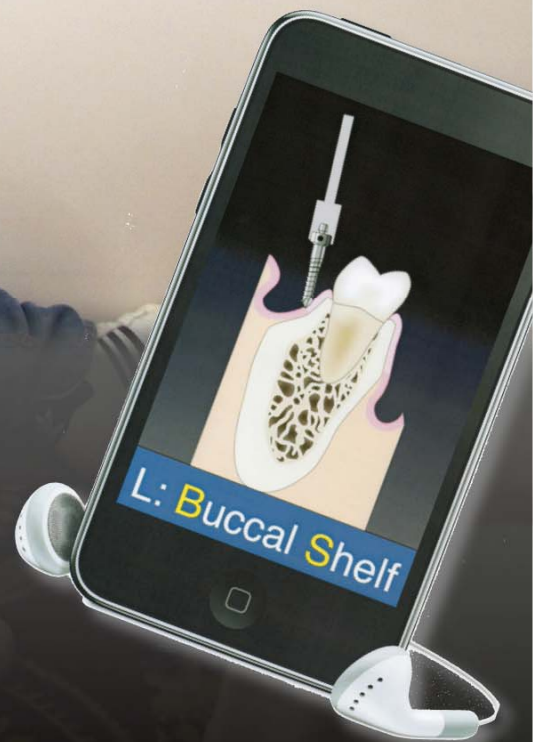報名專線：03-5735676 黃小姐 金牛頓網頁：www.newtonsa.com.tw

ONE size fits
all

Ortho Bone Screw

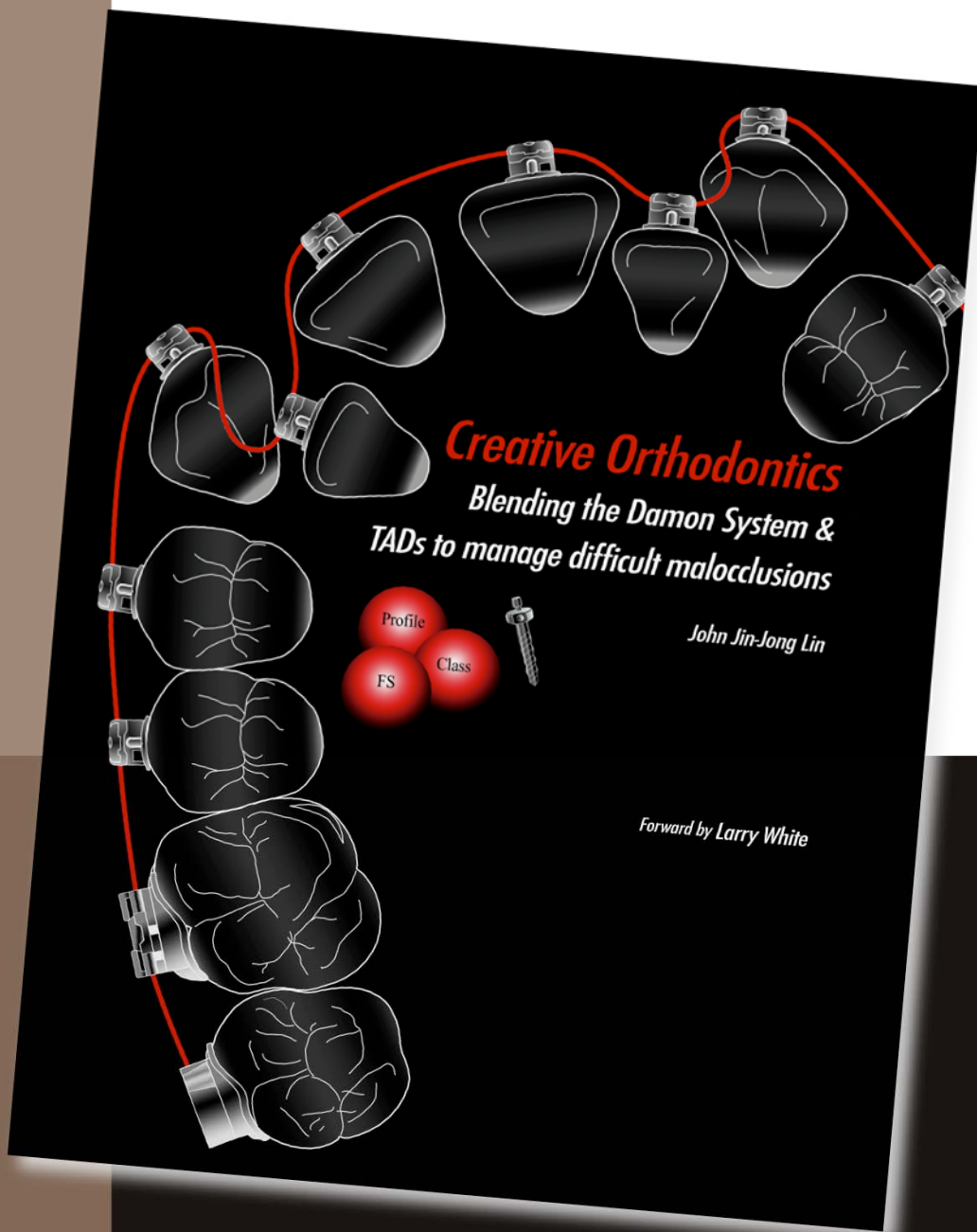
diameter	length	squared-hole	code
2 mm	12 mm	No	OBS 2.0
2 mm	12 mm	Yes	OBS 2.4

OBS 訂購專線：03-573-5676 呂小姐
金牛頓網頁：www.newtonsa.com.tw



An excellent instructive and reference text for postdoctoral orthodontic students and specialist clinical orthodontists. Definitely recommended reading!”

—Alex Jacobson, associate editor of *AJODO*



2009 Beethoven 4th International OrthoBoneScrew and Damon Workshop