

Treatment of a Class III Malocclusion with Anterior Crossbite and Deepbite, Utilizing Infrazygomatic Crest (IZC) Bone Screws as Anchorage

Drs. Irene Yi-Hung Shih, John Jin-Jong Lin & W. Eugene Roberts

Asymmetric Crowded Class II with Missing First Molars: Space Closure or Implants?

Drs. Shih-Wei Lu, Chris Chang & W. Eugene Roberts

Nonsurgical Treatment of Anterior Open Bite Malocclusion

Drs. Ming-Jen Chang, Chris Chang & W. Eugene Roberts

Skeletal Class III Malocclusion with Canine Transposition and Facial Asymmetry

Drs. Wei Ming-Wei, Chris Chang & W. Eugene Roberts

IJOI

International Journal of
Orthodontics & Implantology

Vol. 40 Oct 1, 2015



Portrait of (from left to right) Drs. Chris Chang, Charles Burstone, Eugene Roberts, James Baldwin (oil painting) and bust of C. Burstone (center left). Permanent collection in the Department of Orthodontics and Oral Facial Genetics at Indiana University School of Dentistry.

International Journal of Orthodontics & Implantology is an experience sharing magazine for worldwide orthodontists and Implantologists. Download it at <http://iaoi.pro>.

《僅供牙科專業人士參閱》

2015~2016

熱愛學矯正

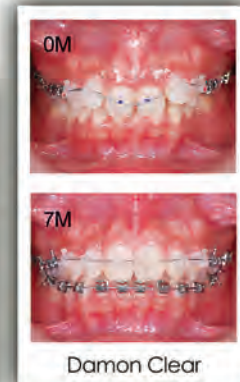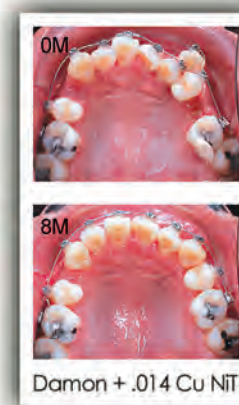
張慧男 博士



新竹貝多芬齒顎矯正中心負責人
 中華民國齒顎矯正專科醫師
 美國齒顎矯正專科醫師學院院士 (ABO)
 美國印地安那普渡大學齒顎矯正研究所博士

學會開始做矯正需多久?

39小時讓您入門矯正。本課程採高效學習法及高效矯正簡報法 - Keynote, 在舒適、輕鬆的環境下, 學會簡單有效的矯正方法, 教室與診間結合, 讓您現學現用, 立即熟悉各種習得的技巧, 而不需太多課後複習。全程以 In-Office Training 方式, 用病例帶動分析、診斷, 治療計畫與療程技巧, 每一步驟皆以圖片及影片教學, 讓您很難錯失任何環節, 更沒有聽不清楚或無法理解的可能。為提高課後自我學習及臨床印證之效率, 另備有教學電子檔, 供學員家中研習。我們的終極目標是: 用最短時間、最輕鬆的方式, 讓每位學員 - 熱愛矯正學、熱愛學矯正。



Damon 矯正課程

【課程】9:00 - 12:00
 【實習】另外安排

使用最新一代矯正器 Damon Q 進行課程, 歡迎舊生報名參加。

	台北 (二)	高雄 (四)	2016 台中 (四)	LECTURE	LAB
1	10/13/15	5/7/15	5/5/16	理想入門病例+Damon Q黏著	Bonding (Damon Q) + BT
2	10/20	5/14	5/19	快速矯正療程四部曲	Ceph + Photo
3	11/3	5/21	5/26	簡捷有效的錨定系統	Damon + OrthoBoneScrew I
4	11/24	6/25	6/16	不拔牙與拔牙分析	Damon + OrthoBoneScrew II
5	12/15	7/16	6/23	Damon 診斷流程及微調	Finish Bending
6	12/22	7/30	6/30	完工檢測及報告示範	Fixed Retainer (FR)
7	12/29	8/13	7/7	維持及復發; 病例示範	Presentation Demo
8	1/5/16	8/27	7/21	矯正力學及診斷分析 (1)	DDX + Case Reports I
9	1/12	9/17	7/28	軟硬組織及診斷分析 (2)	DDX + Case Reports II
10	1/19	9/24	8/11	兒童矯正及診斷分析 (3)	DDX + Case Reports III
11	2/2	11/19	8/25	成人矯正及診斷分析 (4)	DDX + Case Reports IV

矯正植體課程

【課程】9:00 - 12:00
 【實習】13:30 - 20:00

矯正植體的操作時機、植法與實習、個案討論、臨床跟診及實作示範。

新竹(五) 11/6'15 (含午、晚餐)

International workshop

Keynote & management OrthoBoneScrew & Damon

2015	
亞洲B班	10/29 - 30
英文B班	12/1 - 3
2016	
英文A班	4/26 - 29
英文B班	10/18 - 21
馬國A班	9/22 - 24
馬國B班	12/8 - 10

矯正進階課程

【新竹】9:00 - 12:00

以病例討論為主軸, 培養學員如何正確診斷及快速排除臨床疑點, 課程中亦訓練每位學員善用 Keynote。

	新竹 (二)	Paper Reviews	Topics & Case Demo
1	9/15/15	Bracket Placement	Crowding: Ext. vs. Non-ext.
2	9/22	Impacted Canines	Upper Impacted Teeth
3	12/1	Canine Substitution	Lower Impacted Teeth
4	2/16/16	Missing 2nd Premolar	Missing: Ant. vs. Post.
5	3/1	DI Workshop	Crossbite: Ant. vs. Post.
6	3/22	CRE Workshop	Open Bite High Angle
7	3/29	Excellence in Finishing (occlusion)	Deep Bite Low Angle
8	4/5	Excellence in Finishing (esthetics & perio)	Gummy Smile & Canting
9	4/19	Ortho-Perio-Restore Connection	Esthetic Finishing (Transposition)
10	4/26	Adjunct to Perio	Implant-Ortho
11	5/3	Unhappy Patient	IDT - Adult Complex

助理訓練課程

【課程】10:00 - 14:30
 【實習】15:00 - 20:00

每梯次共兩堂課程與技術操作, 內含照相技術、Morph 與公關衛教之電腦資料處理; 另安排一次診所見習。



新竹(五) 10/2、16'15 (含午、晚餐)

課程資訊

上課地點

【台北】
 犇亞會議中心
 / 台北市復興北路99號15樓
 (捷運文湖線 南京復興站旁)

【新竹】
 金牛頓藝術科技公司
 / 新竹市建中一路25號2樓

【台中】
 中國文化大學台中教育中心
 / 台中市西屯區臺灣大道三段
 658號3樓 (Rich 19 大樓)

【高雄】
 國立科學工藝博物館-南館
 / 高雄市三民區九如一路797號
 (107研討室)

報名專線

湧傑 Yong Chieh
北區
 (02) 27788315
 楊文君 分機 # 122

中區
 (04) 23058915 張馨云

南區
 (07) 2260030 王慧靜

* 每次上課請依最新一期
 IJOI 公告為主

矯正精修課程

【課程】9:00 - 12:00

協助每位學員了解由古典到現代之文獻, 進而應用於實際病例; 並藉由DI及CRE讓精緻完工 (Excellent Finishing) 變成易達到的目標。

新竹(二) 精修VII	2015/6/16	7/7	8/11	9/8	10/27	11/17	12/8
	2016/3/15	4/12	5/10	6/14			

Words from the Publisher -
Remembering Dr. Charlie Burstone

On October 22nd I will be heading off to Indiana for a Burstone Memorial Symposium, which this year will commemorate Dr. Charlie Burstone's sad passing and in which I'm sure there will be many tributes for the man whom I like to call the Father of Orthodontic Biomechanics.

Being an Indiana University alumni, I have always been inspired by him, as he had been Chairman and Professor in our orthodontic department, as well as being a great pioneer and champion of the specialty. He made pivotal contributions to orthodontics through his research and his greatest impact was in biomechanics, not surprisingly as his passions were physics and engineering, and every orthodontist appreciates how his genius has helped us to better understand defining predictable force systems.

I started to think about what made Dr. Burstone such a real professional. After learning the fundamentals you have to use what is between your ears coupled with passion and drive. Having met him on numerous occasions I can assure you that he was full of passion, dedication and that his brain never stopped working. He always wanted to push the boundaries of our profession and never stopped thinking.

My mentor, Dr. Eugene Roberts, took over the baton from his mentor, Dr. Burstone, at Indiana University and was the visionary who set up the first Orthodontic PhD program in America. I was so lucky and will be forever honored to have been chosen as his first PhD student. In recognition of these two great mentors passing on the baton to me, I have produced several Dr. Burstone busts, which I will present to every speaker of the symposium as well as to all of my fellow Indiana University PhDs, to ensure that his legacy will continue and to remind today's teachers to pass on the baton to their students and encourage them to emulate his pioneering achievements.

The orthodontic world is indeed indebted to him – we have been lucky to learn and practise orthodontics in the age of Dr. Charlie Burstone and I hope we can march together along our path to glory, which has already been well trodden by our Father of Orthodontic Biomechanics.

Chris Chang DDS, PhD, Publisher of IJOI.

3 Editorial

LIVE FROM THE MASTER

4 Treatment of a Class III Malocclusion with Anterior Crossbite and Deepbite, Utilizing Infrazygomatic Crest (IZC) Bone Screws as Anchorage

IAOI CASE REPORT

18 Asymmetric Crowded Class II with Missing First Molars: Space Closure or Implants?

44 Nonsurgical Treatment of Anterior Open Bite Malocclusion

66 Skeletal Class III Malocclusion with Canine Transposition and Facial Asymmetry

84 Simple Mechanics to Upright Horizontally Impacted Molars with Ramus Screws

MEMORIAM

96 In Memoriam:
 Charles J. Burstone (1928-2015)
 Burstone Biomechanics: a Living Legacy



Examiner
 Dr. W. Eugene Roberts



Examiner
 Dr. Tom Pitts



Examiner
 Dr. John J. J. Lin



Consultant
 Dr. Frederick J. Regennitter



Consultant
 Dr. Tucker Haltom



Consultant
 Dr. J. Michael Steffen



Consultant
 Dr. Larry White



Examiner
 Dr. Thomas Han



Examiner
 Dr. Kwang Bum Park



Examiner
 Dr. Homa Zadeh



Examiner
 Dr. Fernando Rojas-Vizcaya



Consultant
 Dr. Baldwin W. Marchack



Consultant
 Dr. Stephen Wallace



Consultant
 Dr. Mark Y. K. Ou



Guest Editor
 Dr. Rungsi Thavarungkul



Contributors (left to right) :
 Dr. Hong Po Chang, Consultant
 Dr. Ming Guey Tseng, Consultant
 Dr. John Lin, Consultant
 Dr. Frank Chang, Consultant
 Dr. Johnny Liaw, Consultant
 Dr. Chris Chang, Publisher

Treatment of a Class III Malocclusion with Anterior Crossbite and Deepbite, Utilizing Infrazygomatic Crest (IZC) Bone Screws as Anchorage

Abstract

Malocclusions with anterior crossbite are a major esthetic and functional concern for patients and their parents. A 14-year-old boy was diagnosed as a Class III malocclusion, combined with anterior crossbite, deepbite, concave profile, and inadequate maxillary incisor exposure. There was functional shift on closure, and the mandible could be manipulated to an edge-to-edge incisal occlusion, when the condyles were positioned in centric relation. The Discrepancy Index (DI) was 24. A passive self-ligation appliance, with infrazygomatic crest (IZC) bone screw anchorage, and Class III intermaxillary elastics were used to correct this severe malocclusion in only 10 months to a Cast-Radiograph Evaluation (CRE) score of 18. The IZC bone screws were installed buccal to the alveolar process between the upper 1st and 2nd molars. They provided reliable anchorage for intermaxillary elastics to retract the lower incisors and increase the vertical dimension of occlusion. The malocclusion was corrected with a relatively short treatment time, but the maxillary incisors were excessively flared. Long term follow up is required to monitor the potential for late mandibular growth to produce a skeletal Class III relationship. (*Int J Orthod Implantol*;40:2-14)

Key words:

Class III deep bite malocclusion, functional shift, passive self-ligation appliance, IZC bone screws, extra-alveolar bone screw anchorage

History and Etiology

A 14 year-old male presented for orthodontics consultation with Class III malocclusion, anterior crossbite and deep overbite. He had a decreased vertical dimension of occlusion (VDO), lip redundancy, mildly concave profile, and a slightly protrusive lower lip (Figs. 1, 2 and 3). The chief complaint was poor dental esthetics and function due to the anterior crossbite. Medical and dental histories were non-contributory. A functional examination revealed that the mandible could be manipulated from centric occlusion (CO) to a centric relation (CR) position with an edge-to-edge occlusion of incisors, but there was a large posterior open bite, due to the deep curve of Spee in the lower arch. The patient was treated to a

pleasing result in 10 months with a passive self-ligation appliance, combined with infrazygomatic (IZC) bone screws and Class III elastics (Figs. 4, 5 and 6). Cephalometric and panoramic radiographs document the dentofacial patterns before (Fig. 7) and after (Fig. 8) treatment. Superimposed cephalometric tracings show dentofacial changes associated with treatment (Fig. 9).

Diagnosis

Skeletal:

- Class III malocclusion (SNA 83.8°, SNB 89.6°, ANB -5.8° in CO)
- Low mandibular plane angle (SN-MP 25.8°, FMA 19.5 °)

Dr. Irene Yi-Hung Shih,
Visiting Staff, Beauty Forever Dental Clinic (Left)

Dr. John Jin-Jong Lin
MS, Marquette University, Chief Consultant of IJOI, President of TAO (2000~2002)
Author of Creative Orthodontics (middle)

W. Eugene Roberts,
Consultant, International Journal of Orthodontics & Implantology (right)



Fig. 1:
Pre-treatment facial photographs show a mild concave profile with acute nasolabial angle and lower lip protrusion.



Fig. 4: Post-treatment facial photographs:
The upper incisal exposure has increased although the nasolabial angle appears more acute due to proclination of the upper incisors.

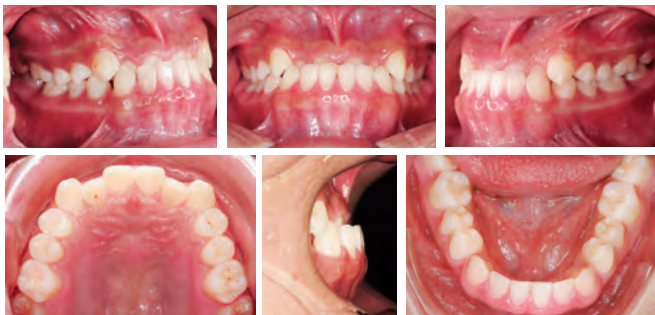

Fig. 2:
Pre-treatment intraoral photographs show mild Class III canine and molar relationships on the left, and Class I canine and molar relationships on the right. Anterior crossbite with a deep overbite and deep Curve of Spee resulted from a lack of vertical stops for the lower anteriors.

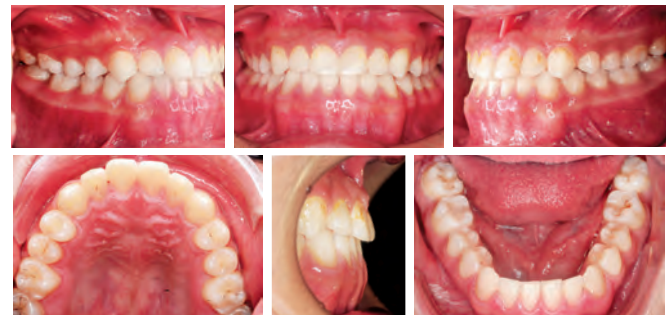

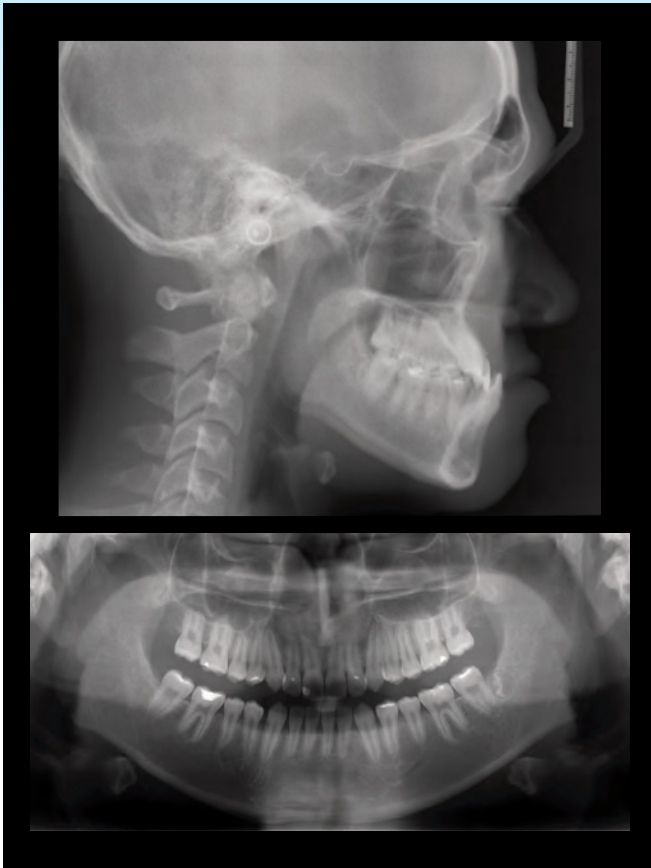
Fig. 5:
Post-treatment intraoral photographs show that the upper and lower midlines are coincident. Positive overjet as well as bilateral canine and molar Class I relationships have been achieved.

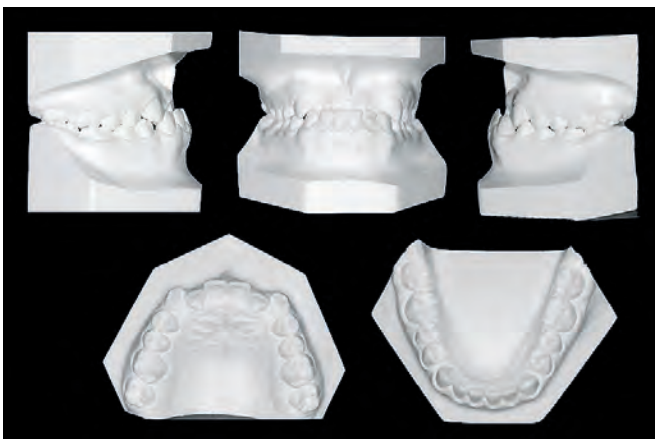

Fig. 3: Pre-treatment study models (casts)

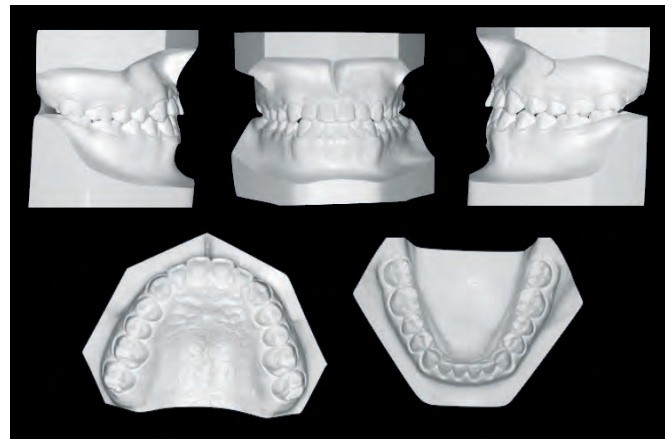

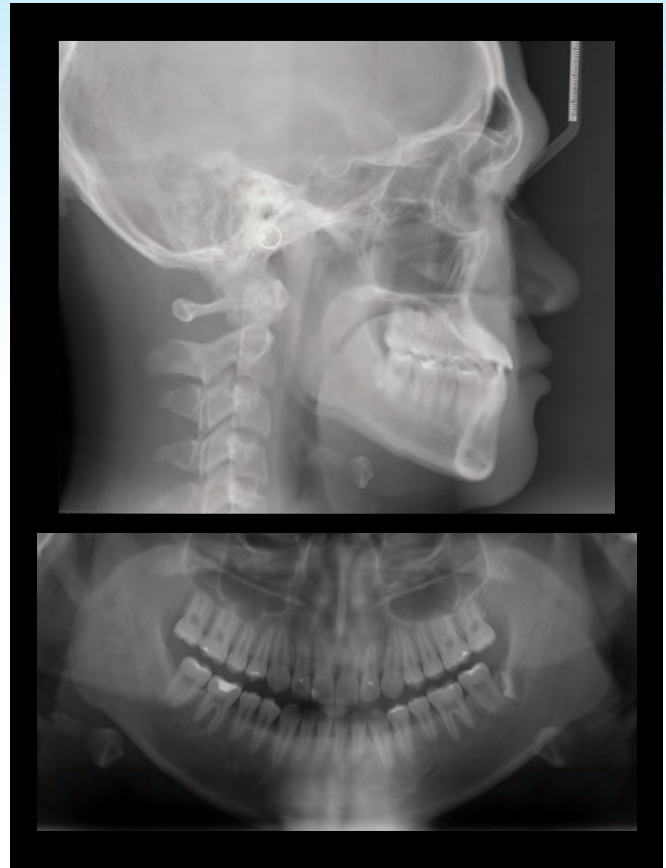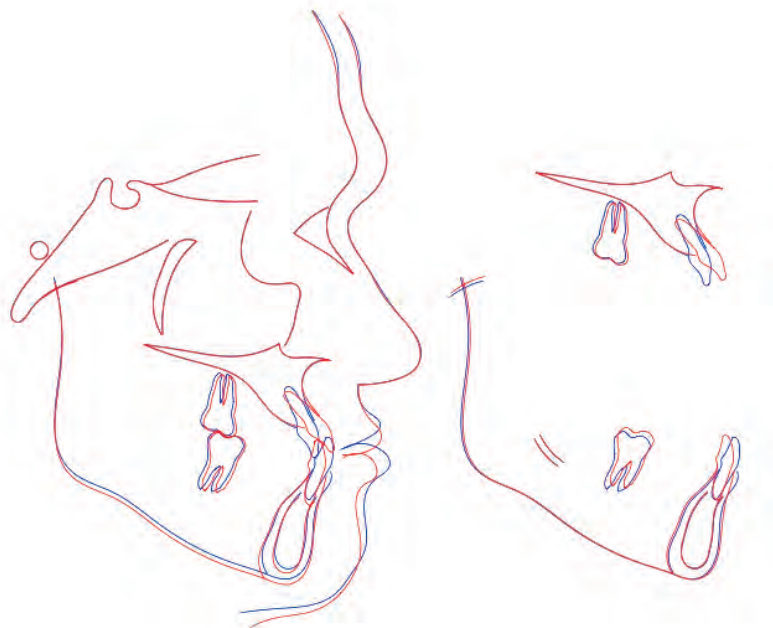
Fig. 6: Post-treatment study models (casts)



■ Fig. 7:
Pre-treatment panoramic and cephalometric radiographs



■ Fig. 8:
Post-treatment cephalometric and panoramic radiographs



■ Fig. 9:
Cephalometric superimposition on the anterior cranial base (blue pre-treatment and red post-treatment) revealed that the anterior crossbite was corrected with marked proclination of upper incisors and retraction of lower incisors. Extrusion of the lower incisors and molars is due to the bite turbo and Class III elastics. The slight increase in length of the mandible indicates there was some growth during the 10 month treatment phase.

Dental:

- Molar relationship in CO: *Class I on the right and Class III on the left*
- Canine relationship in CO: *Class I on the right and Class III on the left*
- The negative OJ was -3.5 mm
- The deep overbite was 78% (7 mm) with a deep curve of Spee
- Space deficiency in the upper arch was 5.5 mm
- Redundant space in the lower arch was 3 mm
- Lower left 3rd molar is still developing
- Upper dental midline was coincident with the facial midline; lower dental midline was shifted to the right about 1.5 mm
- Arch forms: *symmetrical square form in the maxilla and ovoid in the mandible*

Facial:

- Slightly concave profile
- Acute nasolabial angle
- Short upper lip and slightly protrusive lower lip
- Decreased vertical dimension of occlusion (VDO)
- Chin point deviated to the right

The ABO Discrepancy Index (DI) is 24, as shown in the subsequent worksheet.

Treatment Objectives

Maxilla (all three planes):

- A – P: *Allow for normal expression of growth*

- Vertical: *Allow for normal expression of growth*
- Transverse: *Maintain*

Mandible (all three planes):

- A – P: *Decrease*
- Vertical: *Increase*
- Transverse: *Maintain*

Maxillary Dentition:

- A – P: *Increase the axial inclination of the upper incisors*
- Vertical: *Maintain*
- Transverse: *Maintain*

Mandibular Dentition:

- A – P: *Retract the lower incisors*
- Vertical: *Maintain*
- Transverse: *Maintain*

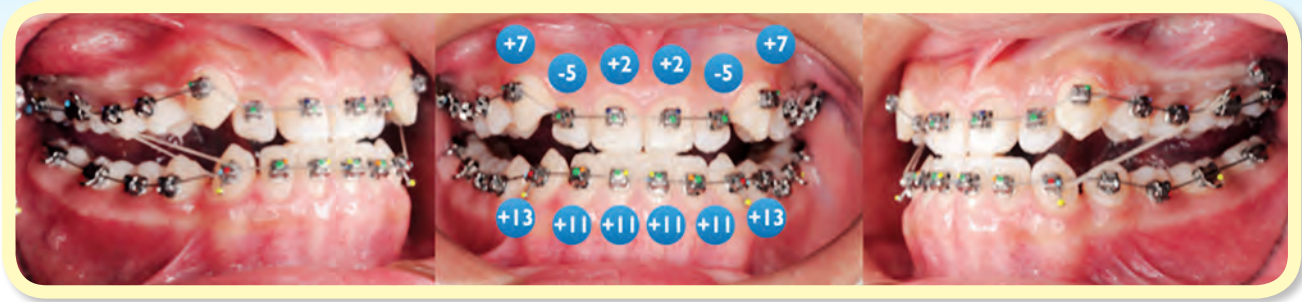Facial Esthetics: Retract the lower lip, and increase the maxillary incisor exposure

Treatment Plan

Non-extraction treatment with a full fixed orthodontic appliance was planned to align and level the dentitions to correct the anterior crossbite. IZC bone screws (2x8 mm, SS) were planned as anchorage for Class III elastics to retract the lower incisors.

Appliances and Treatment Progress

A full fixed .022" slot Damon Q PSL appliances (Ormco, Glendora, CA) was installed (Fig. 10). Low torque brackets were used on the upper incisors (+2°



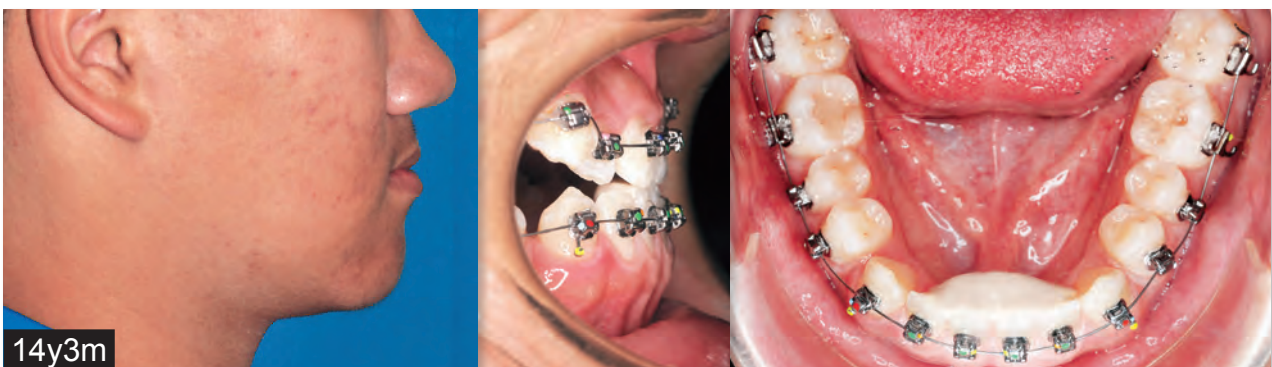■ Fig. 10:

Bracket prescription: Low torque brackets were bonded on the upper incisors to counteract the labial crown torque while aligning upper anteriors. Upside down low torque brackets were used on the lower incisors and high torque brackets bonded on the lower canines to provide more labial crown torque while retracting lower anteriors to correct the anterior crossbite.

on the central incisor, and -5° on the lateral incisor) to counteract the excessive tipping expected when the incisors are aligned to correct the anterior crossbite. Upside down, low torque brackets were used on the lower incisors to deliver $+11^\circ$ of torque. High torque brackets were bonded on the lower canines ($+13^\circ$) to provide labial crown torque as the lower dentition was retracted to correct the anterior crossbite with Class III elastics (Fig. 10). The initial archwires were .014" CuNiTi for both arches. A GIBT (Glass Ionomer Bite Turbo) was constructed on the lingual surfaces of the lower incisors. The immediate increase in the VDO improved the concave profile considerably (Fig.

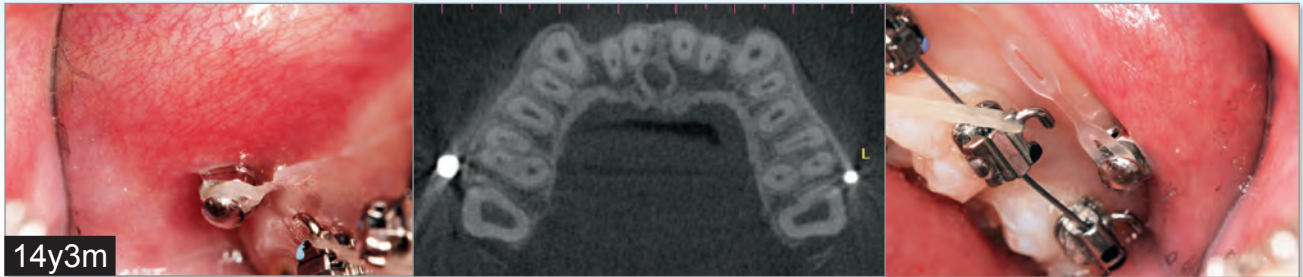
11). The IZC bone screws (2x8 mm, SS), installed on the same day the brackets were bonded, provided anchorage to retract the upper buccal segments with elastic chains, and the entire lower arch with Class III elastics (Fig. 12). An intra-arch elastic chain between the first molars was used to help level the curve of Spee in the lower arch (Fig. 13).

The anterior crossbite was corrected in 2 months by retracting the lower anteriors and flaring the upper anteriors. In the third month of treatment, .014x.025" CuNiTi archwires were placed (Fig. 14). Repositioning of brackets and detailing bends were carried out in



■ Fig. 11:

GIBT (Glass Ionomer Bite Turbos) were bonded on the lingual surface of lower incisors to raise the bite, and the facial profile improved immediately.



■ Fig. 12:

2 IZC bone screws (2x8mm, SS) were installed in the extra-alveolar (E-A) area located between the upper 1st molars and 2nd molars. They provided reliable anchorage for simultaneous retraction of upper and lower arches to help control flaring on upper dentition due to Class III elastics application.

the 8th month of treatment (Fig. 15). After 10 months of active treatment, the dentition was aligned and all the fixed appliances were removed.

Result Achieved

The patient was treated to the planned result as

documented by the cephalometric radiograph superimpositions. The latter demonstrated that the correction of the anterior crossbite was achieved by labial tipping of the upper incisors and extrusion of the lower molars to increase the VDO (Figs. 4-6 and 9). A summary of the cephalometric measurements is provided in Table 1. Pre-treatment and post-treatment panoramic radiographs document the appropriate root parallelism after treatment (Figs. 7 and 8). Cephalometric superimpositions reveal a small increase in the length of the mandible, increased axial inclination of the maxillary incisors, and an increased VDO (Fig. 9).

The ABO Cast-Radiograph Evaluation (CRE) is 18 as shown in the subsequent worksheet.

CEPHALOMETRIC			
SKELETAL ANALYSIS			
	PRE-Tx	POST-Tx	DIFF.
SNA°	83.8°	83.5°	-0.4°
SNB°	89.6°	89.5°	-0.1°
ANB°	-5.8°	-6.0°	-0.3°
SN-MP°	25.8°	26.0°	0.2°
FMA°	19.5°	20.2°	0.7°
DENTAL ANALYSIS			
U1 TO NA mm	7.4 mm	12.6 mm	5.2 mm
U1 TO SN°	114.0°	131.7°	17.7°
L1 TO NB mm	3.5 mm	-0.3 mm	-3.1 mm
L1 TO MP°	79.8°	69.7°	-10.1°
FACIAL ANALYSIS			
E-LINE UL	-6.7 mm	-4.6 mm	2.1 mm
E-LINE LL	-0.9 mm	-2.1mm	-1.2 mm

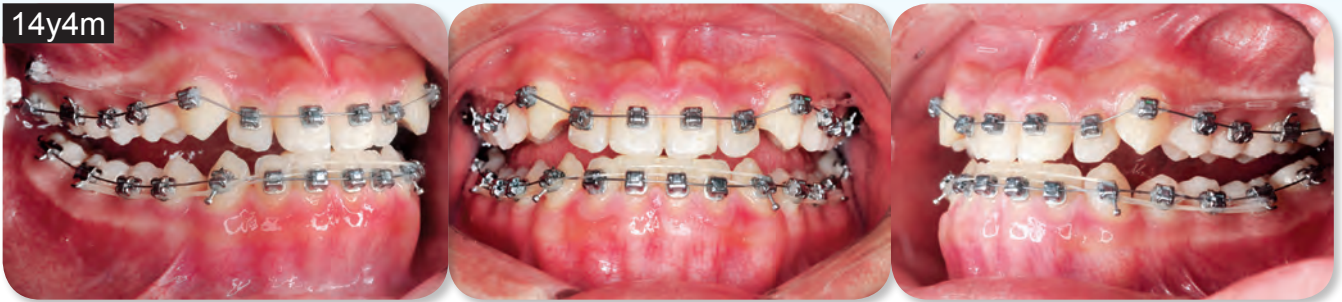■ Table 1: Cephalometric summary

Maxilla (all three planes):

- A – P: *Maintained*
- Vertical: *Maintained*
- Transverse: *Maintained*

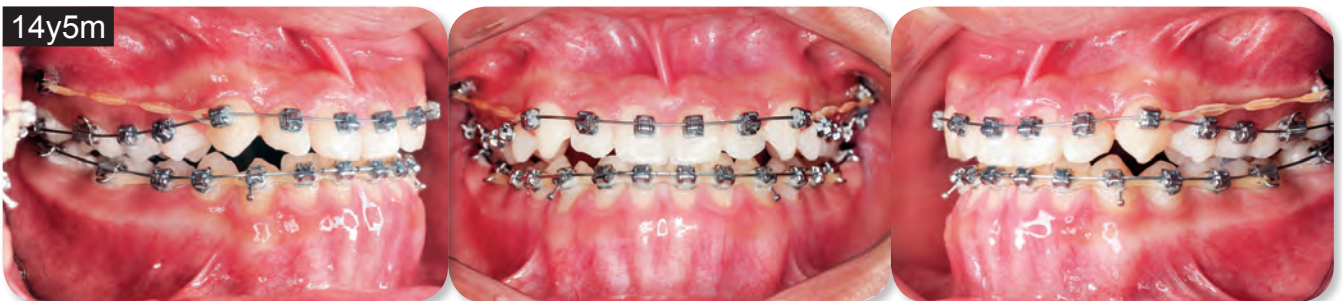Mandible (all three planes):

- A – P: *Maintained*

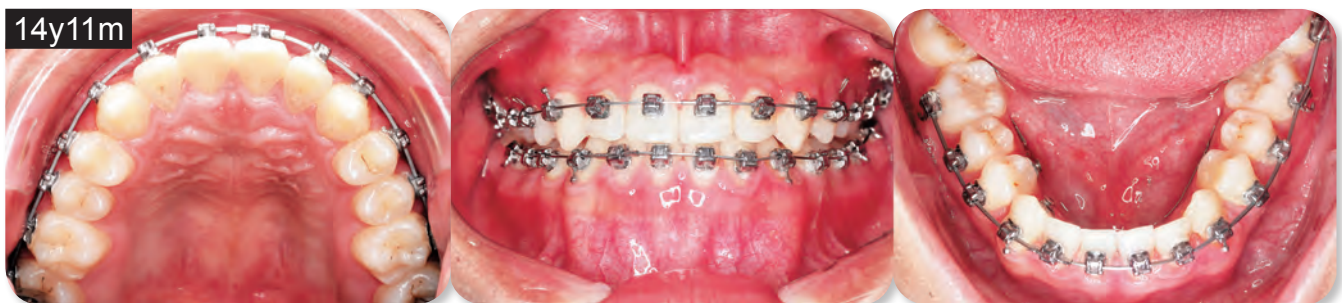

■ Fig. 13:

Intra-arch elastics connected from lower right 1st molar to lower right canine, from lower right canine to lower left canine passed over the top of lower incisors and from lower left canine to lower left 1st molar. These mechanics helped level the curve of Spee and closing all lower spaces.



■ Fig. 14: Anterior crossbite was corrected in the 2nd month of treatment.



■ Fig. 15: Repositioning and detailing were performed.

- Vertical: *Increased*
- Transverse: *Maintained*

Maxillary Dentition:

- A – P: *Increased*
- Vertical: *Decreased incisal exposure as they were tipped labially*
- Transverse: *Maintained*

Mandibular Dentition:

- A – P: *Retracted*
- Vertical: *Increased with molar extrusion to flatten the Curve of Spee*
- Transverse: *Maintained*

Facial Esthetics:

- Increased the lower facial height and VDO
- Increased maxillary incisal exposure
- Increased length of the upper lip

Retention

Upper and lower clear retainers were delivered. The patient was instructed to wear the retainers full time for the first 6 months and nights only thereafter. In addition, the patient was instructed in proper home hygiene and maintenance of the retainers.

Final Evaluation of Treatment

Both arches were well aligned and articulated in Class I canine and molar relationships with the

dental midlines coincident. The overjet has reduced from -3.5 to 2 mm and the overbite has improved from 7mm (80%) to 4 mm (40%) at the end of the treatment. The Cast-Radiograph Evaluation (CRE) score was 18 points, which reflects an excellent alignment. Most of the residual problems were in alignment/rotations, marginal ridge discrepancies, and the axial inclinations of the molars. For details, see the CRE worksheet at the end of this case report.

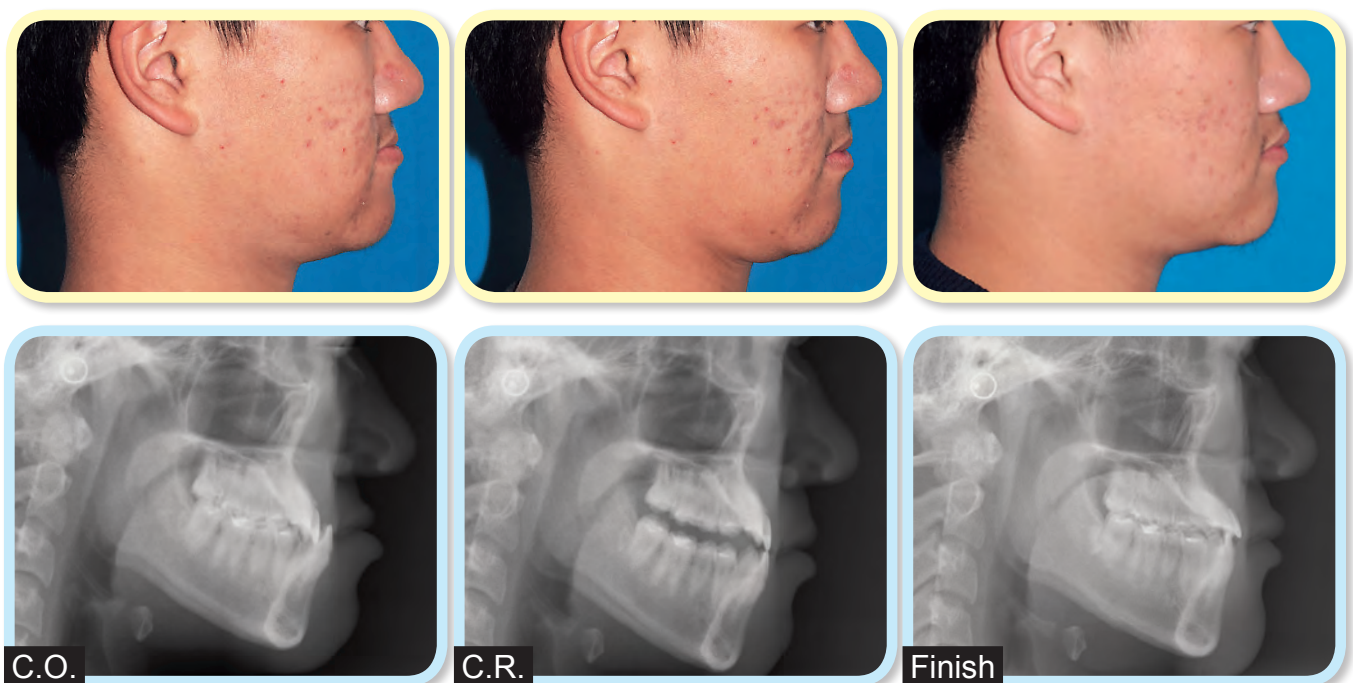Discussion

Correction of anterior crossbite is usually requested by patients and their parents during the developmental years because of esthetic and functional concerns.¹ Anterior crossbite may be a pseudo Class III malocclusion if there is a functional shift of the mandible to achieve maximal intercuspation.^{2,3,4} The functional shift (Fig. 16) indicated that the anterior crossbite could be managed orthodontically, without resorting to extractions and/or orthognathic surgery. Although the patient's mandible could be manipulated backward to an edge-to-edge position, his occlusion was still diagnosed as a dental Class III on the left side, and a dental Class I on the right. In addition, there was a low mandibular plane angle and Class III compensation: ANB -5.8°, SN-MP 25.8°, U1-SN 114°, and L1-MP 79.8°. Mandibular manipulation is important for anterior crossbite patients to determine if there is a functional shift, and whether the malocclusion can be treated with conservative

with conservative orthodontics, as opposed to extractions and/or orthognathic surgery. Furthermore, the differences in the facial profile, when the mandible is positioned in CO and CR, is helpful for understanding the probable outcome of treatment, by patients and their parents (Figs. 16 and 17).^{5,6} However, there may be a large discrepancy between the estimated outcome and the actual result, particularly if the patient is still growing. The pre-treatment CR profile for deepbite patient is usually better than the final result because occluding on an incisal prematurity increases the VDO, and produces a more obtuse nasolabial angle. However, as the patient is treated and the occlusal prematurity is corrected, the deepbite pattern will

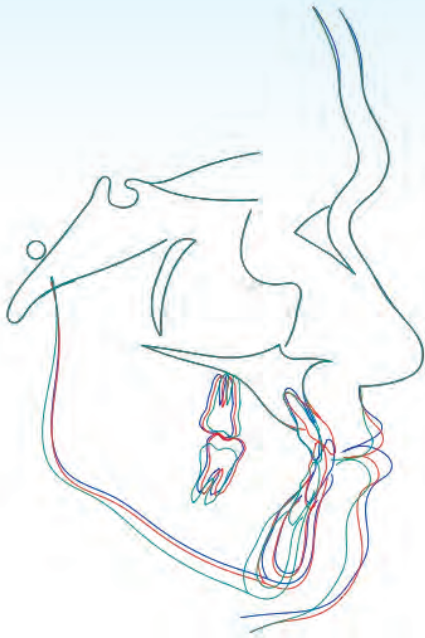return, which requires increased labial inclination of the maxillary incisors to correct the negative overjet.

For the present patient, differential pretorqued brackets were selected for better control of axial inclinations for the upper and lower anterior segments.⁷ Low torque brackets were used on the upper incisors (*Central: +2°, lateral: -5°*) to counteract the labial crown torque, due to the labial force associated with protracting the upper incisors, to correct the anterior crossbite. However, there was still too much labial flaring of the upper incisors at the end of the treatment (*U1-SN 114°→131.7°*). In retrospect, standard torque brackets (*central: +15° lateral: +6°*), placed upside down on the maxillary



■ Fig. 16:

Different profile changes are shown in centric occlusion (CO), in centric relation (CR) with an edge-to-edge bite, and after treatment.



■ **Fig. 17:**
Cephalometric superimpositions at initial C.O. (Blue), initial C.R. (edge-to-edge bite, Green), and end of treatment (Red). The dramatic increase in the VDO achieved with the bite turbos was not sustained after the arches were aligned. Compare to Figure 9.

incisors, would have delivered more negative torque (*central: -15°, lateral: -6°*) to help control the labial tipping. Furthermore, labial movement of the upper incisors could have been delayed until enough space was created by retraction the upper canines with elastic chains anchored by the IZC bone screws. In the lower arch, upside down low torque brackets were used on the lower incisors (+11°) and high torque brackets were bonded on the lower canines (+13°) to provide more labial crown torque to offset the retraction force applied by Class III elastics.

In addition to differential bracket torque, elastic chains from the canines to the IZC bone screws

provided a distal force to counter labial flaring of the maxillary incisors, as the crowding was relieved and the incisors were advanced. Because of their extra-alveolar (E-A) location (Fig. 12), IZC bone screws are effective anchorage for retracting both arches, as well as for resisting incisal flaring due to Class III elastics.⁸ The upper molars were stabilized for Class III elastic anchorage by the retraction force from the IZC bone screws to the maxillary canines bilaterally (Fig. 10).

The treatment for this severe malocclusion was completed in 10 months. It is possible that the final result could have been improved with additional detailing, but a CRE score of 18 at the finish is excellent for a malocclusion with a DI of 24. The treatment reported was conducted relatively early in adolescence (*age 14yr*) so long term follow up is indicated until the age of ~21yr to rule out late mandibular growth. Late adolescent and early adult males may grow out of a Class III correction because of continuing mandibular growth, and develop into a skeletal Class III malocclusion.⁹

Conclusion

Some functional malocclusions may appear to be very difficult in habitual or CO occlusion, but are less imposing in the CR (*retruded*) position of the mandible. It is important to assess or rule out functional discrepancies in the initial evaluation. E-A IZC bone screws provide reliable anchorage for intra-arch alignment and orthopedic correction of both

the maxilla and mandible. Skeletal malocclusions can be corrected in growing adolescent patients, but long term follow up is necessary until the growth of the mandible is complete.⁹

References

1. Major PW, Glover K. Treatment of anterior crossbite in early mixed dentition. *J Can Dent Assoc* 1992;58:574-575.
2. Rabie AB, Gu Y. Management of pseudo-Class III malocclusion in southern Chinese children. *Br Dent J* 1999;186:183-7.
3. Rabie AB, Gu Yan. Diagnostic criteria for pseudo-Class III malocclusion. *Am J Orthod Dentofacial Orthop* 2000;117:1-9.
4. Lin JJ, Liaw JL, Chang CH and, Roberts WE. *Class III Correction Orthodontics*. Taipei: Yong Chieh; 2013.
5. Wood NG. Centric relation and the treatment position in rehabilitating occlusion: A physiologic approach. Part II: The treatment position. *J Prosthet Dent* 1988;60:15-18.
6. Dawson PE. A classification system for occlusions that relates maximal intercuspation to the position and condition of the temporomandibular joints. *J Prosthet Dent* 1996;75:60-66.
7. Lin JJ. *Creative Orthodontics: Blending the Damon system & TADs to manage difficult malocclusions*. 2nd ed. Taipei: Yong Chieh; 2010.
8. Lin JJ. A new method of placing orthodontic bone screws in IZC. *News & Trends in Orthodontics* 2009;13:4-7.
9. Alexander AE, Mcnamara JA Jr, Franchi L, Baccetti T. Semilongitudinal cephalometric study of craniofacial growth in untreated class III malocclusion. *Am J Orthod Dentofacial Orthop* 2009 Jun;135(6):700. e. 1-14.



Discrepancy Index Worksheet

TOTAL D.I. SCORE 24

OVERJET

- 0 mm. (edge-to-edge) =
- 1 – 3 mm. = 0 pts.
- 3.1 – 5 mm. = 2 pts.
- 5.1 – 7 mm. = 3 pts.
- 7.1 – 9 mm. = 4 pts.
- > 9 mm. = 5 pts.

Negative OJ (x-bite) 1 pt. per mm. per tooth = **14**

Total = 14

OVERBITE

- 0 – 3 mm. = 0 pts.
- 3.1 – 5 mm. = 2 pts.
- 5.1 – 7 mm. = 3 pts.
- Impinging (100%) = 5 pts.

Total = 3

ANTERIOR OPEN BITE

0 mm. (edge-to-edge), 1 pt. per tooth
then 1 pt. per additional full mm. per tooth

Total = 0

LATERAL OPEN BITE

2 pts. per mm. per tooth

Total = 0

CROWDING (only one arch)

- 1 – 3 mm. = 1 pt.
- 3.1 – 5 mm. = 2 pts.
- 5.1 – 7 mm. = 4 pts.
- > 7 mm. = 7 pts.

Total = 2

OCCLUSION

- Class I to end on = 0 pts.
- End on Class II or III = 2 pts. per side _____ pts.
- Full Class II or III = 4 pts. per side _____ pts.
- Beyond Class II or III = 1 pt. per mm. _____ pts.
additional

Total = 0

LINGUAL POSTERIOR X-BITE

1 pt. per tooth Total = 0

BUCCAL POSTERIOR X-BITE

2 pts. per tooth Total = 0

CEPHALOMETRICS (See Instructions)

ANB $\geq 6^\circ$ or $\leq -2^\circ$ = 4 pts.

Each degree $< -2^\circ$ 4 x 1 pt. = 4

Each degree $> 6^\circ$ _____ x 1 pt. = _____

SN-MP

$\geq 38^\circ$ = 2 pts.

Each degree $> 38^\circ$ _____ x 2 pts. = _____

$\leq 26^\circ$ = 1 pt.

Each degree $< 26^\circ$ 1 x 1 pt. = 1

1 to MP $\geq 99^\circ$ = 1 pt.

Each degree $> 99^\circ$ _____ x 1 pt. = _____

Total = 5

OTHER (See Instructions)

- Supernumerary teeth _____ x 1 pt. = _____
- Ankylosis of perm. teeth _____ x 2 pts. = _____
- Anomalous morphology _____ x 2 pts. = _____
- Impaction (except 3rd molars) _____ x 2 pts. = _____
- Midline discrepancy (≥ 3 mm) @ 2 pts. = _____
- Missing teeth (except 3rd molars) _____ x 1 pts. = _____
- Missing teeth, congenital _____ x 2 pts. = _____
- Spacing (4 or more, per arch) _____ x 2 pts. = _____
- Spacing (Mx cent. diastema ≥ 2 mm) @ 2 pts. = _____
- Tooth transposition _____ x 2 pts. = _____
- Skeletal asymmetry (nonsurgical tx) @ 3 pts. = _____
- Addl. treatment complexities _____ x 2 pts. = _____

Identify:

Total = 0

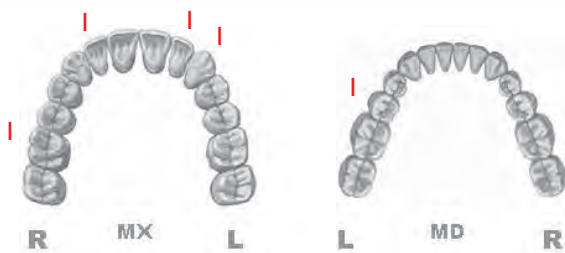
Cast-Radiograph Evaluation

Total CRE Score

18

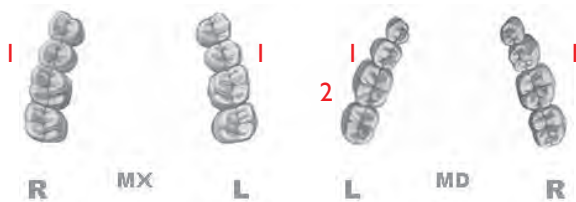
Alignment/Rotations

5



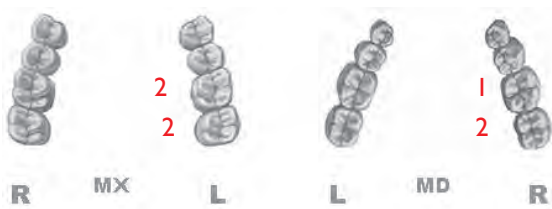
Marginal Ridges

6



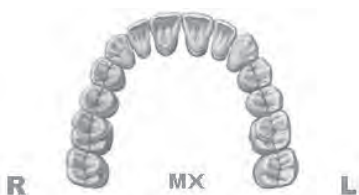Buccolingual Inclination

7



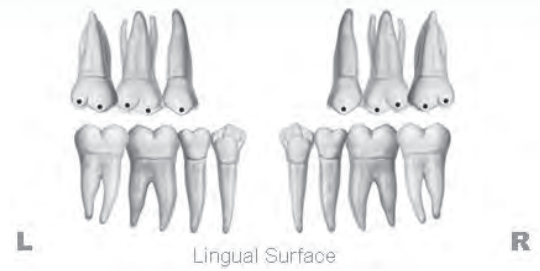
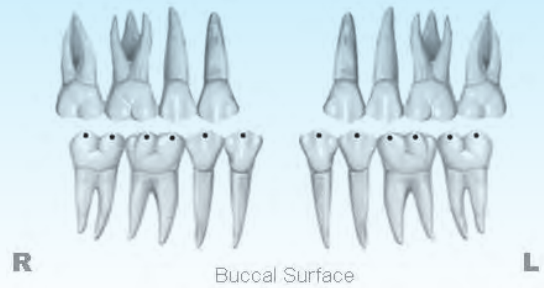
Overjet

0



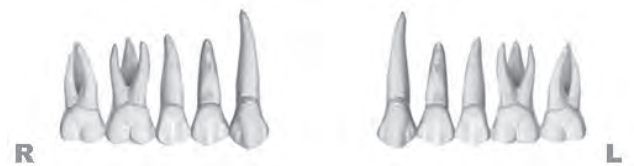Occlusal Contacts

0



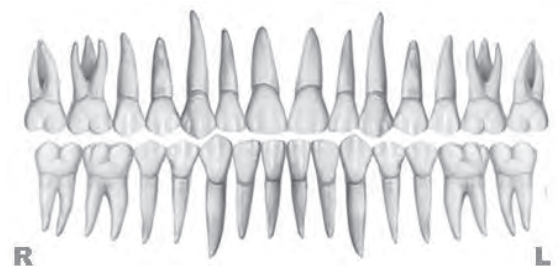
Occlusal Relationships

0



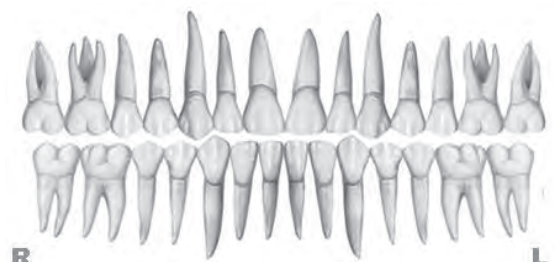
Interproximal Contacts

0



Root Angulation

0



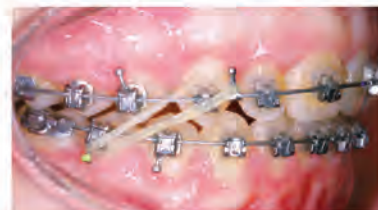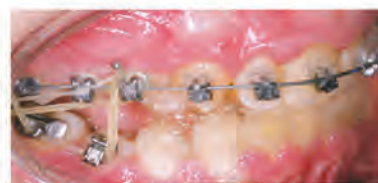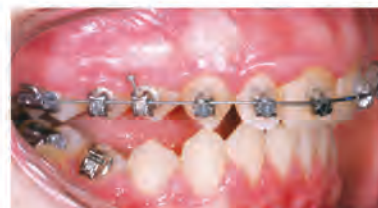INSTRUCTIONS: Place score beside each deficient tooth and enter total score for each parameter in the white box. Mark extracted teeth with "X". Second molars should be in occlusion.

Orthodontic Solutions to

Asymmetry & TMJ Problems



Dr. Elizabeth Menzel



強力推薦

張慧男醫師

我第一次聽 Dr. Menzel 的演講是在三年前美國 Damon Forum 的 break out session，當時就對她深入的案例分析以及獨到的治療方式印象深刻。隔天我又再次去重聽她的演講，赫然發現昨天的鄰席聽眾-加拿大名醫 Dr. Jean Réne也忍不住跑來重聽，他告訴我：「這次來聽這個演講就夠本了！」她與眾不同的魅力可見一般。

今年在歐洲的 Damon Forum 再度聆聽她的演講，她熱情的表達魅力再次征服全場觀眾。Dr. Menzel 的專長在以簡潔的矯正技術來處理各式的 asymmetry 問題。由於她的分析能深入討論 TMJ 與 occlusion 的關係，讓我們對病因及其發展可以有更深入的體會，也因此可以發展出有創見的治療方式。這是我二十多年來聆聽這麼多矯正演講，深感極具啟發性的一名講者。她不僅是一位實踐家，也是一位哲學家。誠懇向大家推薦這一場今年絕對不能錯過的原創演講！

時間：2015/12/27 9:00-17:00

地點：台灣金融研訓院 菁業堂

台北市羅斯福路3段62號2-3F

報名方式：

官方網站：<http://iaoi.pro>

或報名專線：03-5711377

收費表：

	11/30 前報名	12/01 後報名
會員價	3,600 元	5,000 元
非會員價	5,000 元	7,000 元

協辦單位會員同享會員價，

入會費	年費	第一階段資格考 Board Eligibility Exam
1,000 元	3,000 元	9,000 元 → 3,000 元 (含入會費、年費、考試及證書費)

匯款帳戶：

日盛國際商業銀行 (815) 光復分行 (0347)

帳號：105-27376210-000

戶名：國際矯正植牙學會

主辦單位：iAOL 國際矯正植牙學會

協辦單位：中華民國齒顎矯正學會

台灣口腔矯正醫學會

湧傑企業股份有限公司

2016 活動預告

12/27 現場報名
享超級優惠！

年中大會 4.24 (日)



西班牙
隱形矯正大師

Dr. Diego Peydro Herrero

年度大會
7.31~8.01

(日、一)



義大利
舌側矯正 Eline
系統創辦人

Dr. Giuseppe Scuzzo



International **A**ssociation of **O**rthodontists & **I**mplantologists

For more information on benefits and requirements of iAOI members, please visit our official website: <http://iaoi.pro>.

Join the *iAOI*, the future of dentistry!

How to join iAOI?

Certified members of the Association are expected to complete the following three stages of requirements.

1. Member

Doctors can go to <http://iaoi.pro> to apply for membership to join iAOI. Registered members will have the right to purchase a workbook in preparation for the entry exam.

2. Board eligible

All registered members can take the entry exam. Members will have an exclusive right to purchase a copy of iAOI workbook containing preparation materials for the certification exam. The examinees are expected to answer 100 randomly selected questions out of the 400 ones from the iAOI workbook. Those

who score 70 points or above can become board eligible.

3. Diplomate

Board eligible members are required to present three written case reports, one of which has to be deliberated verbally. Members successfully passing both written and verbal examination will then be certified as Diplomate of iAOI.

4. Ambassador

Diplomates will have the opportunity to be invited to present six ortho-implant combined cases in the iAOI annual meeting. Afterwards, they become Ambassador of iAOI and will be awarded with a special golden plaque as the highest level of recognition in appreciation for their special contribution.



International
Association of
Orthodontists &
Implantologists
國際矯正植牙學會

歡迎至 <http://iaoi.pro> 獲得更多 iAOI 會員權益與專科認證等最新消息。

加入 iAOI， 共創牙科的未來！

如何加入 iAOI？

欲取得國際矯正植牙學會會員資格，需完成下列階段：

1. Member

醫師可以在網站 <http://iaoi.pro/> 直接申請加入會員資格，申請完成的醫師將具有資格索取線上考題題庫或是考題題庫紙本，得用以準備入會考試。

2. Board eligible

所有申請加入會員資格的

醫師始可參加入會考試，參加考試的醫師將從四百題題庫選出的一百道題目作答，以 70 分（含）為通過標準，通過的醫師即可獲得 Board eligible 資格。考試的時間為一個小時。下次考試的時間為年中/年度大會前一週，以線上進行考試。

3. Diplomate

已獲得會員資格者，需要提出三篇案例報告，其中一篇案例需要再做口頭報告，通

過審查後，始可獲得 iAOI 的 Diplomate 資格。三篇案例中，至少須有一篇案例，同時涵蓋矯正與植牙領域。此為單一案例的個案報告。報告人和評論人需在規定的時間內完成報告及講評。每個報告人需在 12 分鐘內報告單一個案。大會會在第十分鐘時響第一次鈴，第十二分鐘到時會直接將麥克風關閉。每個個案報告結束後，全體評論人共有八分鐘可以講評。大會會在第六分鐘時響第一次鈴，第十分鐘到時會直接將麥克風關閉。評論人如果

有額外的意見可以以書面方式提供給報告人。

4. Ambassador

獲得院士資格的醫師，將有機會受邀在 iAOI 年度大會中提出六篇矯正與植牙結合的案例報告。完成報告的醫師，始取得 iAOI Ambassador 的資格，並且獲頒紀念獎牌，以表揚醫師對學會的特別貢獻。

Asymmetric Crowded Class II with Missing First Molars: Space Closure or Implants?

Abstract

A 30-year-old female presented with a Class II malocclusion complicated with severe maxillary anterior crowding, moderate deep-bite and the asymmetric loss of two permanent first molars: lower right (#30) and upper left (#14). The adjacent second molars were rotated and tipped mesially. A third molar was present on the lower right side (#32), but the third molar was missing from the upper left quadrant (#16). The Discrepancy Index (DI) for this asymmetric malocclusion was 16 points. Orthodontics treatment with a full fixed, passive self-ligating (PSL) appliance resulted in closure of the lower right space (area #30), but the missing third molar (#16) required opening space for an implant to replace the missing #14. After aligning the dentition, closing all mandibular space, and opening the implant site, cone-beam computer tomography (CBCT) imaging was utilized to evaluate bone distribution. A titanium fixture was installed in the palatal aspect of the #14 area, with a flapless surgical procedure. Thirteen months after fixture placement, orthodontic treatment was completed and an implant-supported prosthesis was delivered. The overall duration for the entire interdisciplinary treatment was 29 months. Multiple outcome assessment scores documented an excellent result: cast-radiograph evaluation (CRE) 22, dental esthetics 3, implant position 0, and abutment transition 1. (*Int J Orthod Implantol*;40:18-41)

Key words:

Class II canine relationship, missing first molars, molar-incisor hypomineralization, space management, crowding, deep bite, implant-supported prosthesis, flapless implant surgery

History and Etiology

A 30-year-old female with a partially edentulous malocclusion was referred by her general dentist for orthodontics consultation. The chief complaint was a lack of space for an upper left posterior prosthesis (Figs. 1-3). There was no contributory medical history, but the dental evidence was consistent with the early loss of permanent first molars due to molar-incisor hypomineralization (MIH).¹ Following 29 months of treatment, the patient was treated to an optimal result as documented in Figs. 4-6. The pre-treatment and post-treatment cephalometric and panoramic radiographs are shown in Figs. 7 & 8, respectively. Careful examination of the pretreatment radiographs revealed a morphologic asymmetry of the condyle heads and mandibular plane (Fig. 7), which apparently contributed to a cant in the occlusal plane and asymmetric facial form in the frontal view (Fig. 1). Superimposed cephalometric tracings document the dentofacial changes during treatment (Fig. 9).

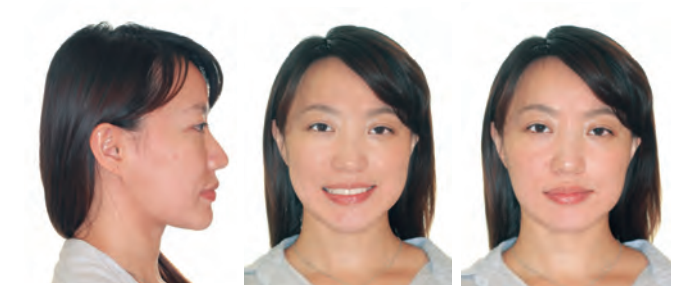Dr. Shih-Wei Lu,
Instructor, Beethoven Orthodontic Course (Left)

Dr. Chris Chang,
*Founder, Beethoven Orthodontic Center
Publisher, International Journal of Orthodontics & Implantology (middle)*

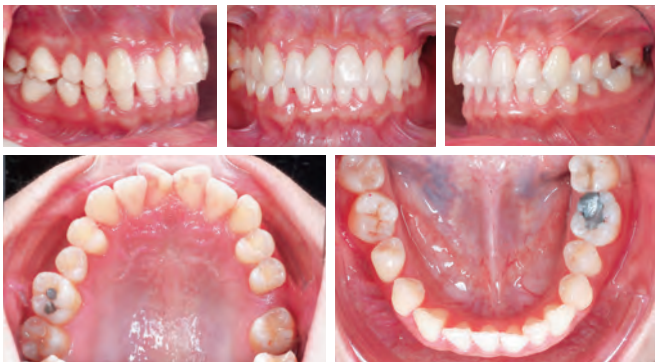W. Eugene Roberts,
Consultant, International Journal of Orthodontics & Implantology (right)



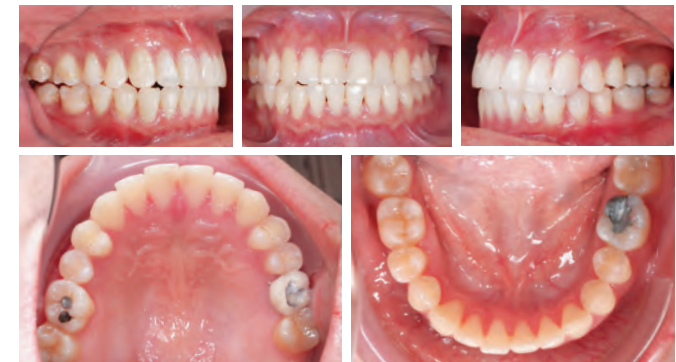■ Fig. 1: Pre-treatment facial photographs



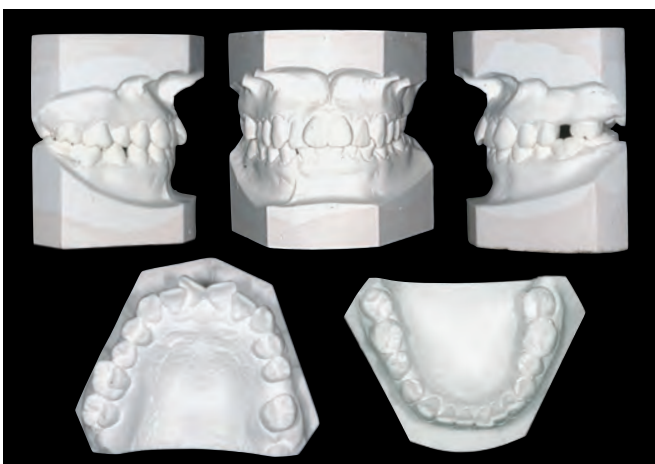■ Fig. 4: Post-treatment facial photographs



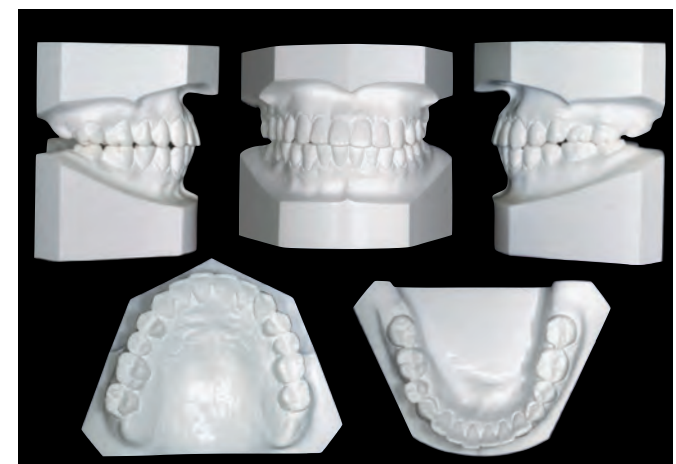■ Fig. 2: Pre-treatment intraoral photographs



■ Fig. 5: Post-treatment intraoral photographs



■ Fig. 3: Pre-treatment study models (casts)



■ Fig. 6: Post-treatment study models (casts)

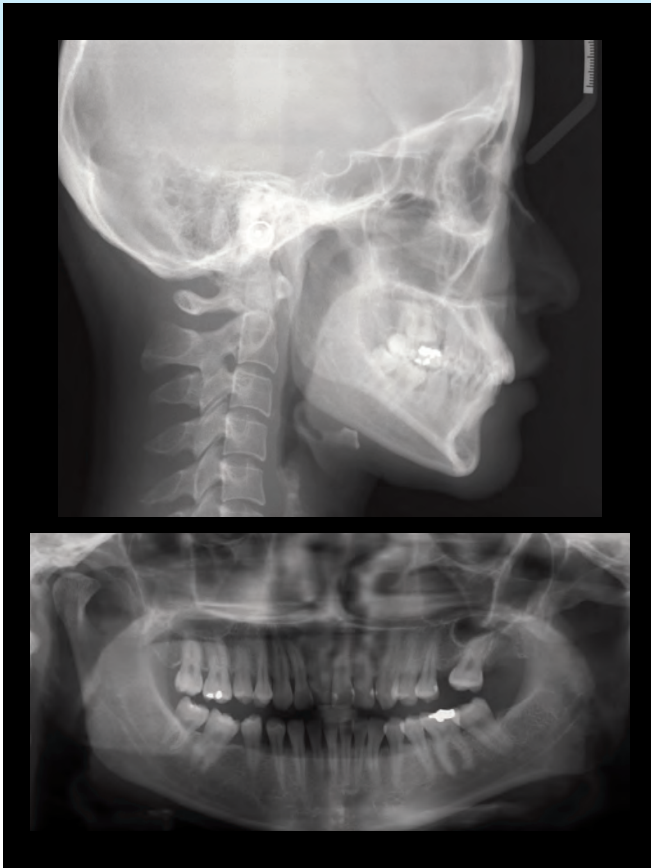


Fig. 7: Pre-treatment lateral cephalometric and panoramic radiographs reveal high mandibular plane, asymmetric superiorly positioned right condylar head, and missing teeth (#14 & 30). Note the root length of #29 was shorter than other teeth.

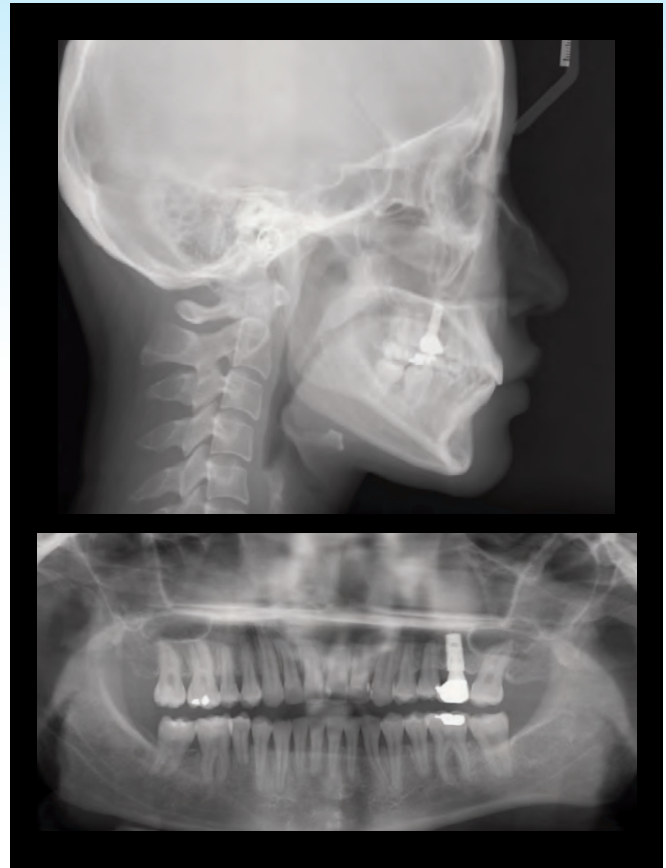


Fig. 8: Post-treatment lateral cephalometric and panoramic radiographs reveal acceptable root angulations and the position of implant-supported prosthesis. The root length of #29 is shorter than it was pre-treatment.

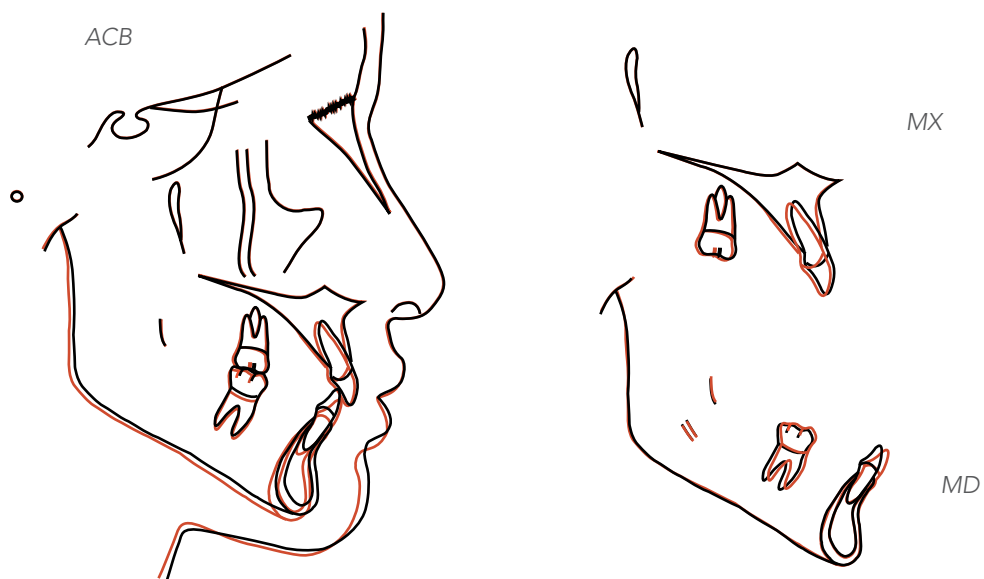


Fig. 9: Cephalometric tracings before (black) and after (red) treatment were superimposed on the anterior cranial base (ACB), maxilla (MX) and mandible (MD).

CEPHALOMETRIC			
SKELETAL ANALYSIS			
	PRE-Tx	POST-Tx	DIFF.
SNA°	80°	80°	0°
SNB°	77°	76°	0°
ANB°	3°	4°	1°
SN-MP°	38°	40°	2°
FMA°	31°	33°	2°
DENTAL ANALYSIS			
U1 TO NA mm	4 mm	3 mm	1 mm
U1 TO SN°	102°	104°	2°
L1 TO NB mm	4 mm	6 mm	2 mm
L1 TO MP°	87°	94°	7°
FACIAL ANALYSIS			
E-LINE UL	-2 mm	-2 mm	0 mm
E-LINE LL	-1 mm	0 mm	1 mm

■ Table 1: Cephalometric summary

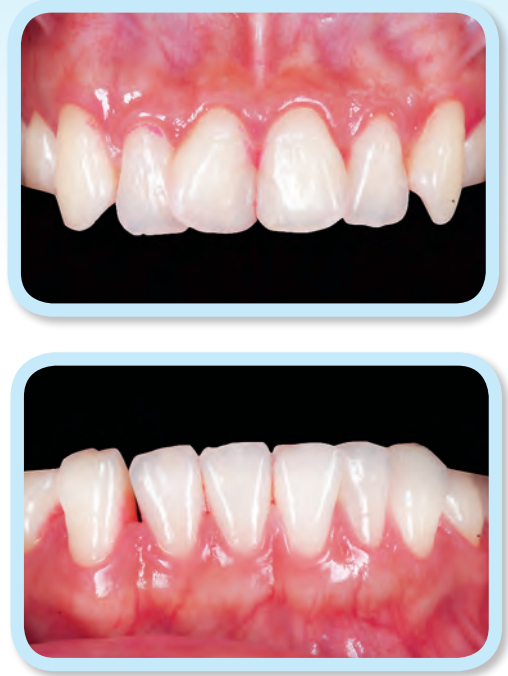Diagnosis

Skeletal:

- Class I (SNA 80°, SNB 77°, ANB 3°)
- High, asymmetric mandibular plane angle (SN-MP 38°), with an enlarged and superiorly positioned right condyle

Dental:

- Angle Classification: Class II canine with asymmetric molar interdigitation due to the loss of #14 and 30
- Incisal relationships: overjet 2mm, overbite ~5mm (Fig. 10)
- Tooth Size to Arch Length Discrepancy: crowding >7mm in the upper anterior, moderate crowding in the lower arch



■ Fig. 10:

Pre-treatment photographs document upper and lower anterior crowding, which increases the possibility for interproximal back triangles after leveling and alignment.

- Missing teeth were the upper left first molar (#14) and lower right first molar (#30)

Radiographic \ Panoramic:

- Short root on the lower right second premolar (Fig. 7)
- Asymmetric shape and size of condylar head: right side is larger and more superiorly positioned

Facial:

- Acceptable profile, modest cheek asymmetry in the frontal plane

The Discrepancy Index (DI) was 16 as shown in the subsequent worksheet.²

Specific Objectives of Treatment

Maxilla:

- A - P: *Maintain*
- Vertical: *Maintain*
- Transverse: *Maintain*

Mandible:

- A - P: *Maintain*
- Vertical: *Maintain*
- Transverse: *Maintain*

Maxillary Dentition:

- A - P: *Align and open space for an implant-supported prosthesis (ISP) in the area of #14*
- Vertical: *Maintain*
- Inter-molar Width: *Maintain*
- Inter-canine Width : *Maintain*
- Buccolingual Inclination: *Maintain*

Mandibular Dentition:

- A - P: *Align and close all spaces*
- Vertical: *Maintain*
- Inter-molar Width: *Maintain*
- Inter-canine Width: *Maintain*
- Buccolingual Inclination: *Maintain*

Facial Esthetics: Maintain

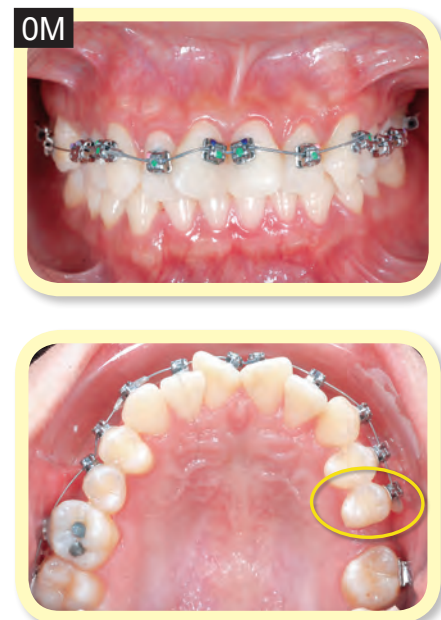Treatment Plan

Non-extraction treatment with a passive self-ligating (PSL) bracket system was indicated.^{2,3} Align the dentition in a Class I occlusion and close all spaces,

except for the upper left quadrant, where the edentulous site will be opened for an ISP in area of #14. Maintain facial form in the frontal and sagittal planes. Use intermaxillary elastics as needed to achieve a Class I interdigitation. At the end of active treatment, deliver clear overlay retainers for both arches.

Appliances and Treatment Progress

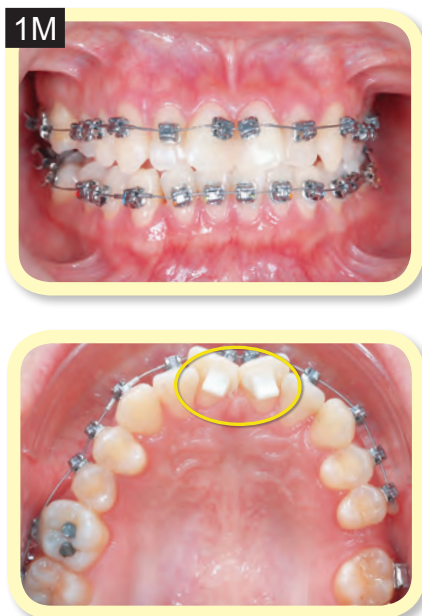The .022" slot Damon Q® bracket system (Ormco, Glendora, CA) was used. The maxillary arch was bonded initially with the PSL appliance, using low torque brackets on the maxillary incisors (Fig. 11). The archwire (.014" CuNiTi) was engaged in all brackets and tubes except for the left second molar (#15),



■ Fig. 11

Low torque brackets were bonded on the upper incisors. The initial .014" CuNiTi archwire terminated at the left upper second premolar (yellow oval) and was not engaged in the tube of tooth #15 because it was likely to be displaced when chewing.

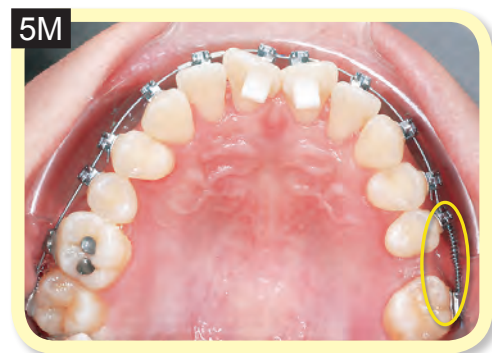which was avoided because the wire was likely to be displaced during normal mastication. After one month of active treatment, the mandibular arch was bonded with standard torque PSL brackets and fitted with an .014" CuNiTi archwire. Bite turbos were placed on both upper central incisors to open the deep bite (Fig. 12). In the 5th month of active treatment, the upper archwire was changed to .018" CuNiTi and engaged in all brackets. An open coil spring was placed between #13 and 15 to create space for an ISP. Note the left side of the upper archwire extended to prevent disengagement with mastication. Drop-in hooks were fitted in the vertical slot of the upper first premolars, and the patient was instructed to wear Class II elastics (Parrot 5/16, 2oz.) bilaterally full time. The elastics extended from the



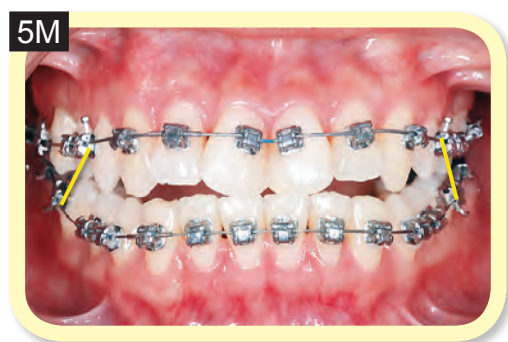■ **Fig. 12:**
Standard torque brackets were bonded on the lower arch and a .014" CuNiTi archwire was fitted. Bite turbos (yellow marker) were placed on the palatal surface of the the upper central incisors to correct the deep bite.

upper first premolars to the most mesial lower molar to correct the sagittal discrepancy (Fig. 13).

Three months later, a rectangular .014x.025" CuNiTi wire was placed in the upper arch and the .018" CuNiTi was fitted in the lower arch. In the 9th month of treatment, interproximal enamel reduction was performed on upper incisors to eliminate the black triangles, and an elastomeric tube was applied



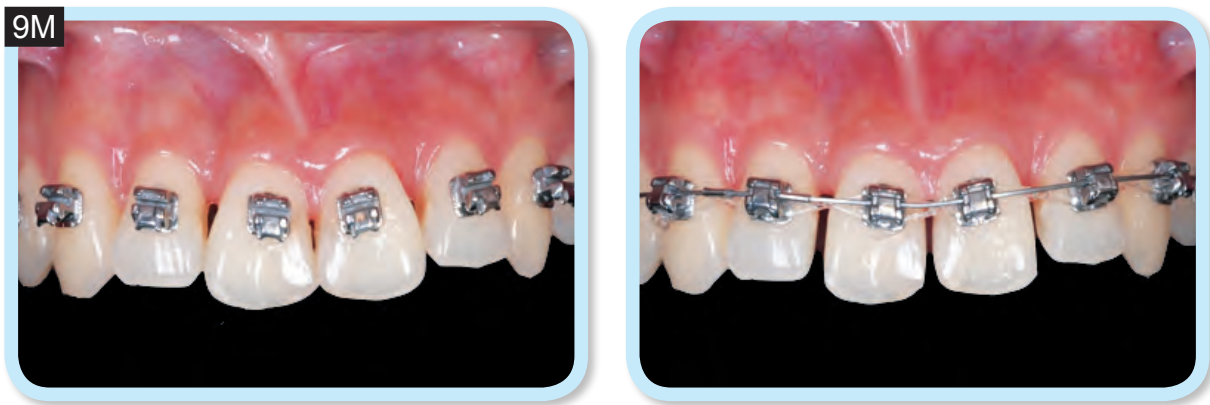■ **Fig. 13-a:**
The upper archwire was changed to .018" CuNiTi and engaged to all brackets. An open coil spring was placed between #13 and #15 (yellow marker) to create space for implant-supported prosthesis.



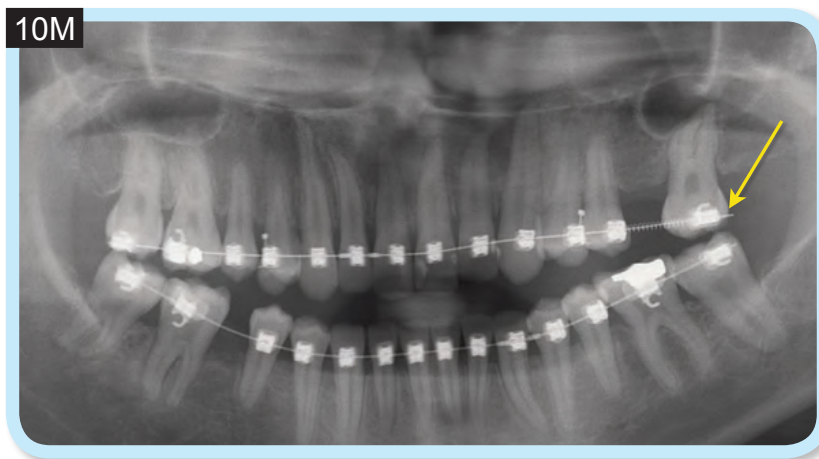
■ **Fig. 13-b:**
Class II elastics (Parrot 5/16, 2oz.) were applied bilaterally, from the upper first premolars to the lower molars (Left: 1st molar; Right: 2nd molar).

to close the space (Fig. 14). One month later, a progress panoramic film was used to evaluate axial inclinations (Fig. 15). The brackets for teeth #3, 5, 6, 11, 20, and 24 were repositioned. Twelve months into treatment, the upper archwire was replaced by .017x.025" low friction TMA, and the anterior segment was ligated with a .012" stainless steel (SS) ligature in a figure-eight pattern.

In the 14th month of active treatment, .016x.025" SS archwires were used for both arches. Lingual buttons were bonded on lower right first premolar and third molar. Elastomeric chains were then attached from first premolar to third molar, on both buccal and lingual surfaces, to close the residual edentulous space in the mandibular arch. Lingual force facilitates the process of space

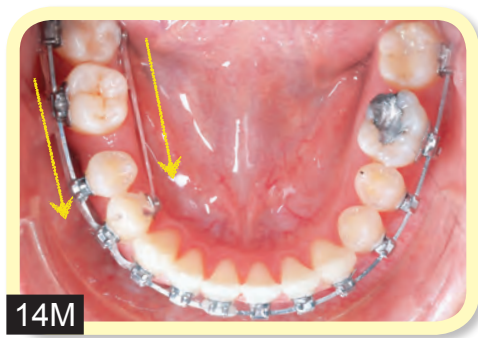


■ Fig. 14: To correct black triangles, interproximal enamel reduction was performed on upper incisors to create space that was closed with elastomeric tube.

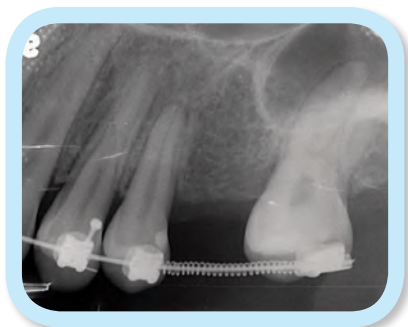
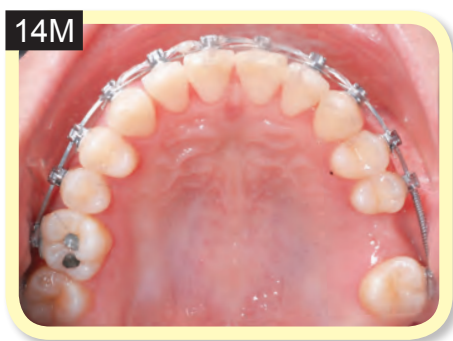

■ Fig. 15: A progress panoramic film to assess axial inclinations shows that the archwire extended beyond the tube on the upper left side (yellow arrow).

closure and prevents the lower third molar from rotating distal-out (Fig. 16-a). The space for the implant site (area #14) was prepared by tipping the upper left second molar distally (Fig. 16-b).



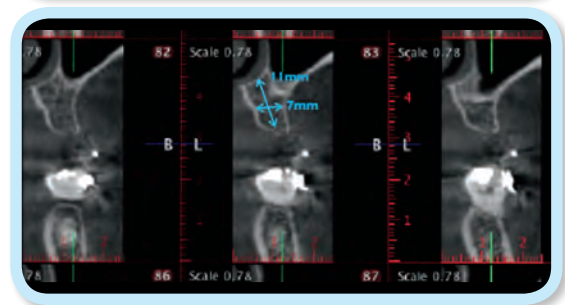
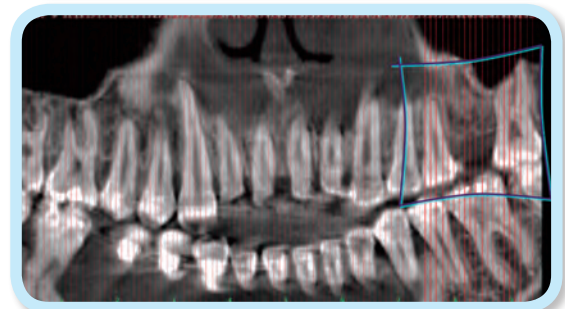
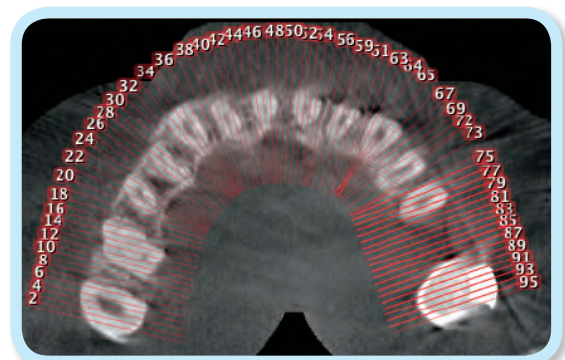
■ Fig. 16-a: Elastomeric chains were attached on the buccal and lingual surfaces to achieve more efficient space closure (yellow arrows) and avoid iatrogenic rotation of the terminal right molar.



■ Fig. 16-b: The implant site has been prepared in the area of tooth #14.

Implant Placement

Before surgery, a three-dimensional cone beam computed tomography (CBCT) image was utilized to evaluate bone density and volume in the implant site. Bone height of 11 mm and buccolingual width of 7 mm was adequate for a 4.3x10.0 mm implant. The anatomic structure of the implant site is shown in Fig. 17. Because of the abundance of soft and

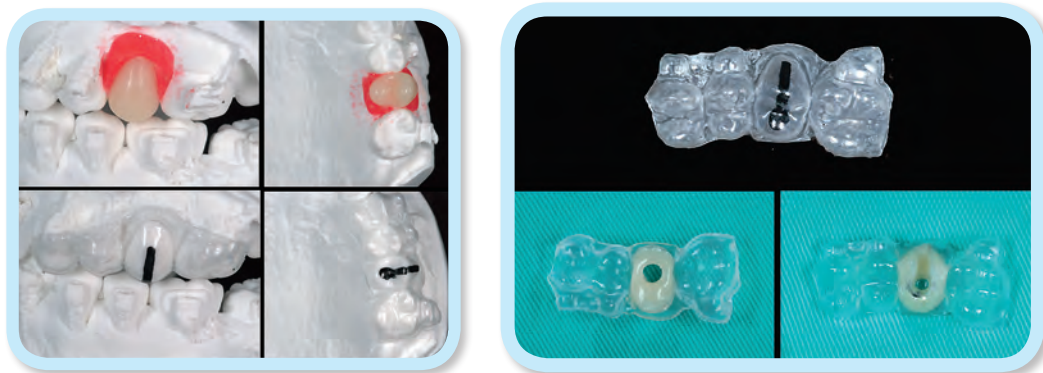


■ Fig. 17: Slices of the CBCT scan demonstrate that the bone height was about 11 mm and bucco-lingual width was 7 mm.

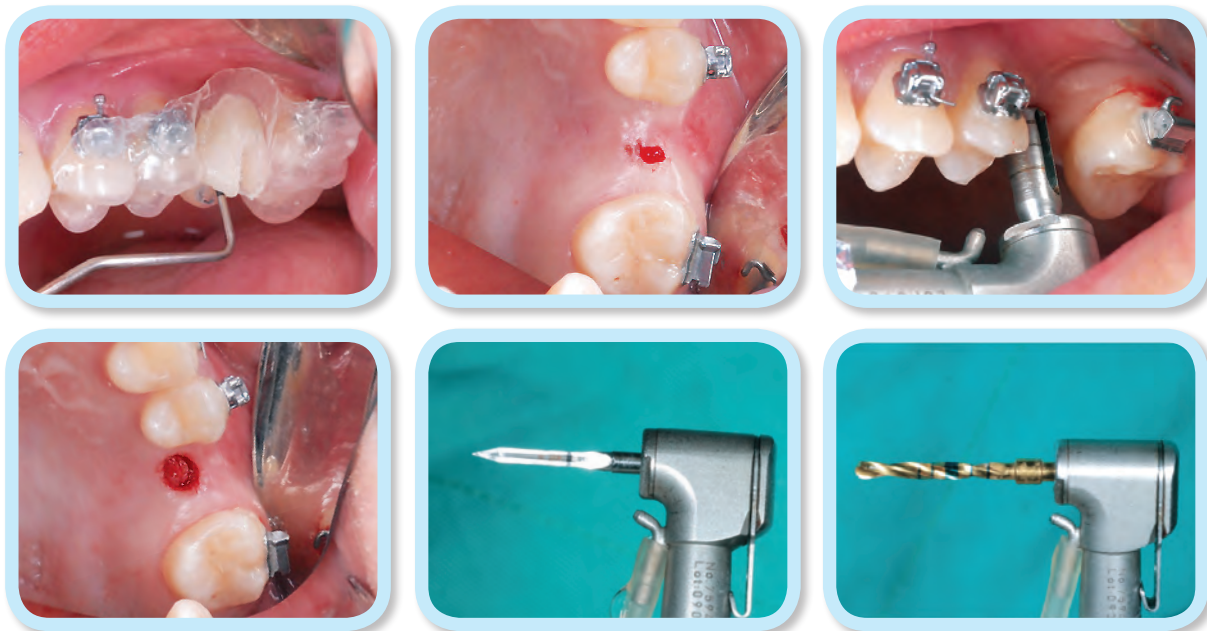
hard tissue imaged on CBCT scan, a flapless implant surgery technique was indicated for the implant placement. A surgical stent was designed following the 2B-3D rule⁴ for precise implant placement in all three dimensions (Fig. 18). To insure adequate bone of the buccal surface of the implant, the stent was

designed for osteotomy penetration on the lingual aspect of the implant site (Fig. 19).

Under local anesthesia, the surgical stent was fitted into position and a periodontal probe marked the position of the future implant. A soft tissue punch



■ Fig. 18: A surgical stent was constructed according to the 2B-3D rule for precise implant placement in all three dimensions.



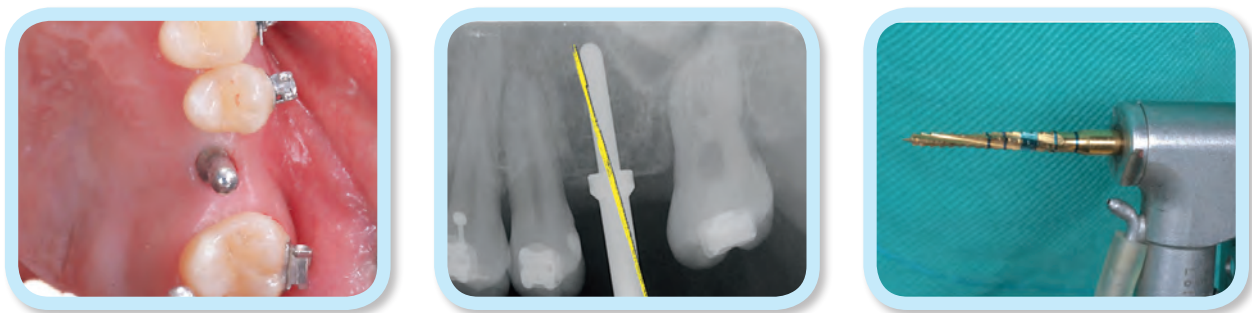■ Fig. 19: The surgical stent was fitted into position and a periodontal probe was used to penetrate the soft tissue to make a bleeding point to serve as a guide for implant position (upper center view). A gingival puncture (Ø4.0mm) was performed by a soft tissue trephine and the core of soft tissue was then detached from the crestal bone with a surgical curette (lower left view). The first lancer drill and the following twist drill are shown in the lower center and left views, respectively.

($\text{\O}4.0\text{mm}$) was utilized to make a circular incision through the gingiva (Fig. 19). The core of soft tissue was detached from the crestal bone with a surgical curette, and the soft tissue thickness was 2.5 mm, as measured with the periodontal probe.

The surgical stent was securely positioned for the initial osteotomy. The first lancer drill penetrated 10 mm in depth (7 mm bone and 3 mm soft tissue). Then the first twist drill was used to enlarge the osteotomy, at the depth established by the lancer drill. A surgical guide pin ($\text{\O}2.0\times 10\text{ mm}$) was placed in the osteotomy, and a periapical radiograph was exposed to evaluate the distance between the sinus floor and the most proximal aspect of the

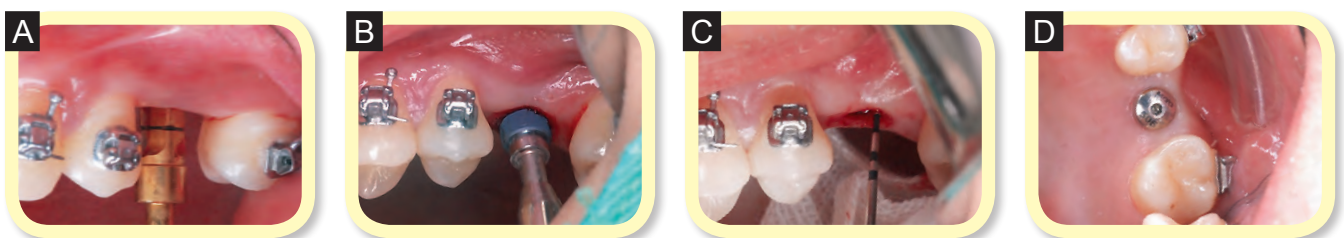
implant site preparation. A periapical radiograph demonstrated that the angulation of surgical guide pin was not parallel to the long axis of the second premolar, so a side-cutting drill (Linderman) was used to correct the direction of the osteotomy (Fig. 20).

Once the orientation was corrected, the osteotomy was completed with twist drills, following the implant manufacturer recommendations. A 4.3x10.0 mm fixture was inserted (Fig. 21) with a rotary motion until the fixture depth was $\sim 3\text{ mm}$ lower than the cervical margin of future prosthesis.⁴ To complete the installation procedure, a 5 mm healing abutment was placed. Post-op radiographs showed that the angulation of the fixture was parallel to the long



■ Fig. 20:

A surgical guide pin (left) was placed and a periapical X-ray (center) was taken to check the position of the osteotomy. A side cutting Linderman drill (left) was used to correct the osteotomy orientation.



■ Fig. 21:

A 4.3x10.0 mm fixture (A) was installed (B). The fixture depth was 3 mm below the cervical margin of future prosthesis, measured with a periodontal probe (C). A 5 mm healing abutment was placed (D).

axis of second premolar, and was several mm away from the floor of the maxillary sinus. CBCT images confirmed that the buccal bone thickness was at least 2 mm, which is desirable for the longterm success of the implant-supported prosthesis (Fig. 22).

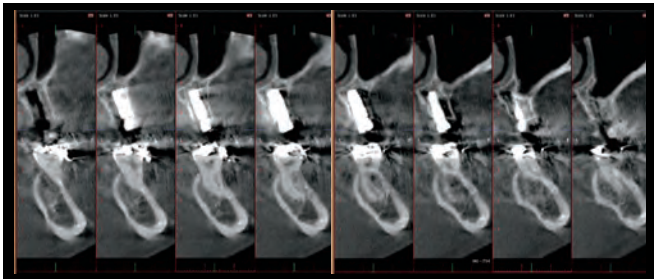
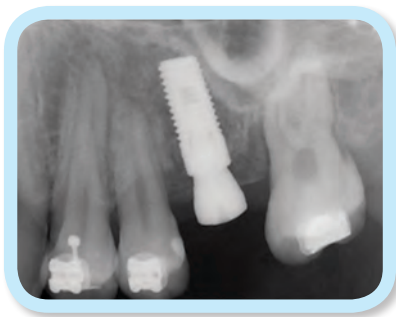

Fig. 22: A post-operative periapical radiograph (left) and CBCT (right) were taken to check the position of the implant, as well as to confirm the integrity of the sinus membranes. The periapical view (left) showed the angulation of the fixture was parallel to the long axis of the second premolar, as planned. The slice view of the CBCT images (right) show that the buccal bone thickness was ≥ 2 mm.

Orthodontic Finishing Stage

Finishing with fixed appliances was accomplished during the post-op healing period before completion of the ISP.⁵ To avoid rotating the second premolar with the compressed coil spring, a light-cured resin stop was installed on the archwire to serve as a stable base for applying the compressive force to the second molar (Fig. 23). In the 16th month

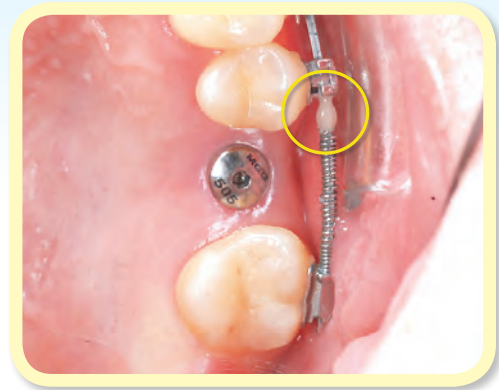
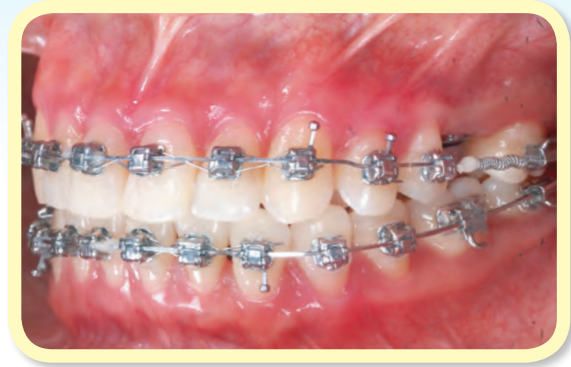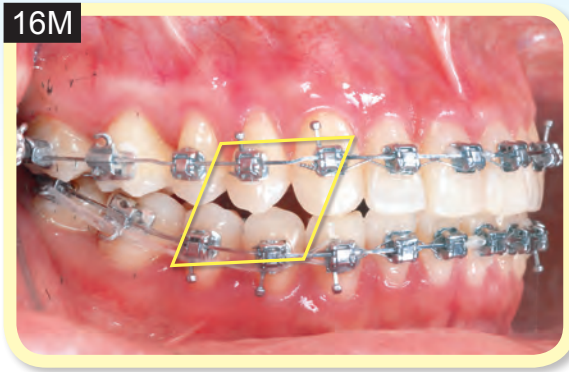


Fig. 23: Light-cured resin (yellow circle) was used as a base on the archwire to produce a compressive load to tilt the second molar distally.

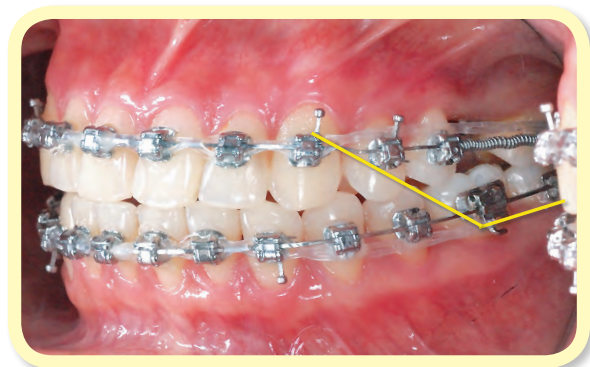
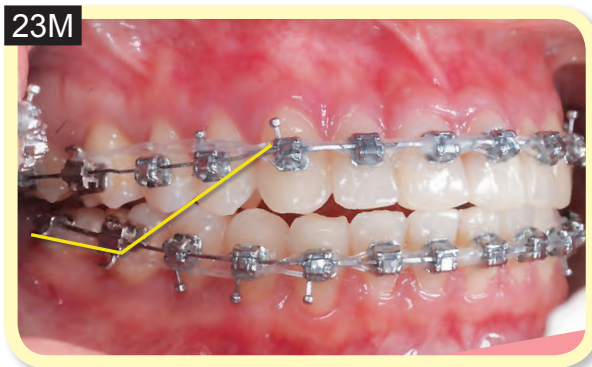
of active treatment, detailed finishing bends of the upper archwire were performed, and the patient was instructed to wear a rhomboid shaped elastic (Fox 1/4, 3.5oz.) on the right side to correct the localized Class II openbite relationship (Fig. 24).⁶ At this point in treatment, the patient's availability for appointments was restricted by frequent trips abroad, and she could only return for treatment about every 6 months.

At 23 months of treatment, interproximal enamel reduction and space closure was performed between the upper central incisors to eliminate black triangles. L-type elastics (Fox 1/4, 3.5oz.) were applied from the upper canines to lower molars bilaterally (Fig. 25). Five months later, a progress panoramic film assessed root angulations (Fig. 26), and brackets were repositioned as needed. In the 29th month of active treatment, all fixed appliances were removed. Upper and lower clear overlay retainers were delivered for both arches.

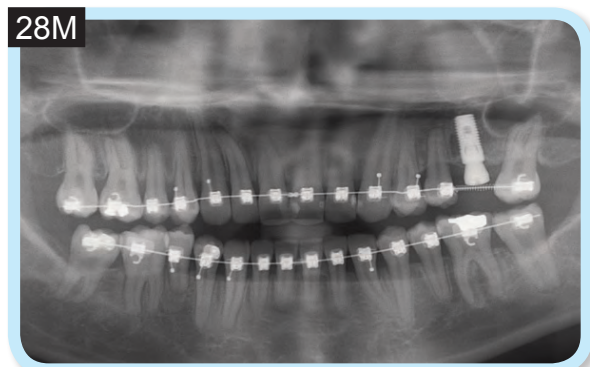
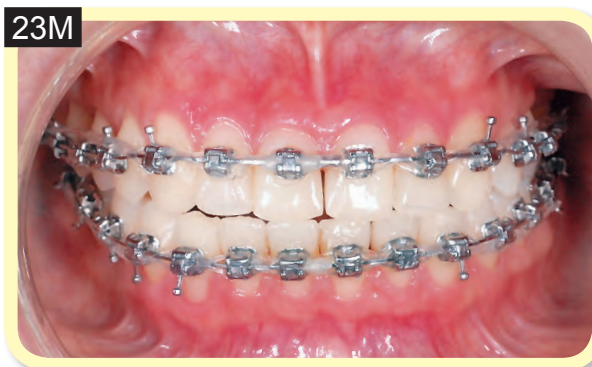

■ Fig. 24:

At sixteen months into treatment (16), detailed finishing bends in the upper archwire were combined with a rhomboid shape elastic (Fox ¼", 3.5oz), as depicted by the yellow rhomboid figure on the right side.



■ Fig. 25-a: At 23 months, L-type elastics (Fox 1/4, 3.5oz.) were applied from the upper canines to lower molars bilaterally.



■ Fig. 25-b:

At 23 months, another interproximal enamel reduction was performed between the upper central incisors to complete the correction of the black triangle.

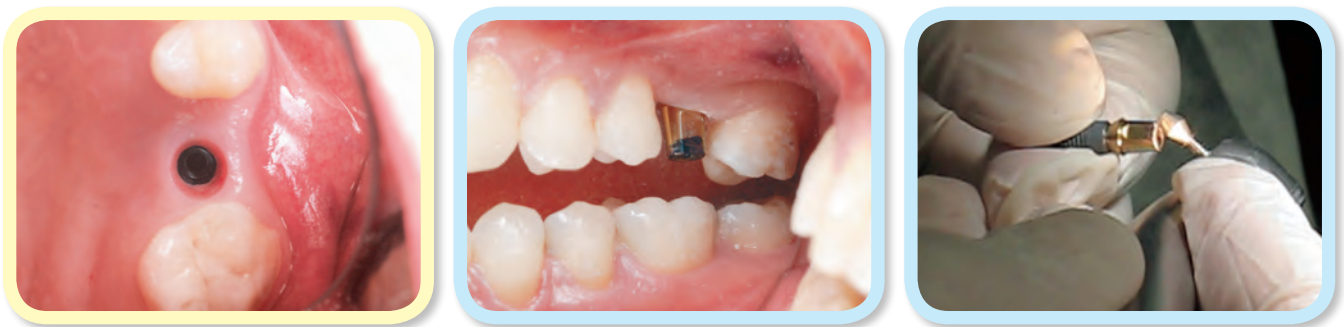■ Fig. 26:

At 28 months, a progress panoramic film was taken to evaluate the root angulations.

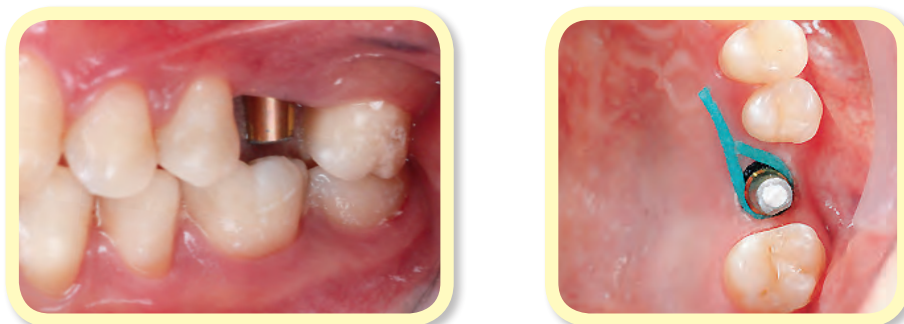
Implant Prosthesis Fabrication

Thirteen months after the implant was placed, the healing abutment was removed, and the surrounding tissue thickness was found to be 3 mm. A 3.0 mm cuff height, multi-post abutment (Ø5.0 mm, 5.2 mm post height and 3.0 mm cuff height) was selected for prosthesis fabrication. The height of the abutment post was adjusted extraorally with a diamond bur, mounted on a high speed hand piece, to provide inter-occlusal clearance for fabrication of the porcelain fused to metal crown (Fig. 27). An abutment level impression technique was chosen.

Before taking the impression, the abutment was torqued 25 N-cm with a torque wrench. A double core packing technique was used to retract the gingiva. The screw access hole for the abutment was then sealed with a small cotton pledget and temporary cement (Fig. 28). A direct impression was made with polyvinyl siloxane, and poured with type IV dental stone. The casts were subsequently articulated with check-bite records. After completion of the final prosthesis, its marginal integrity was verified with a dental explorer and appropriate tightness of the contact area was confirmed with dental floss.

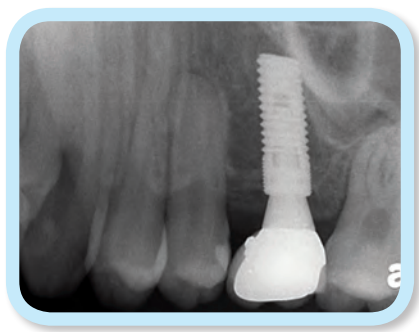


■ **Fig. 27:** A 3.0 mm soft tissue cuff height (left) indicated a 3 mm multi-post abutment (center). The post height was adjusted with a diamond bur mounted on a high speed head piece, to provide 2 mm inter-occlusal clearance for the fabrication of the porcelain fused to metal crown.



■ **Fig. 28:** The height of the abutment was reduced to provide 2 mm of occlusal clearance (left). Double core packing technique was used to retract the gingiva (right).

After clinical adjustment and verification of the fit and occlusion, the definitive crown was luted into place with temporary cement, before the patient went abroad again. The screw access hole was filled with composite resin (Fig. 29).



■ **Fig. 29:**
The final crown was luted into place with temporary cement. The crown contours and occlusal surface were coordinated with the adjacent second molar (a).

Results Achieved

Maxilla:

- A - P: *Maintained*
- Vertical: *Maintained*
- Transverse: *Maintained*

Mandible:

- A - P: *Decreased*
- Vertical: *Increased*
- Transverse: *Maintained*

Maxillary Dentition:

- A - P: *Incisors were retracted slightly*
- Vertical: *Molars and incisors slightly extruded*
- Inter-molar Width: *Maintained*
- Inter-canine Width: *Maintained*

Mandibular Dentition:

- A - P: *Incisors moved anteriorly as their axial inclination was increased*
- Vertical: *Molars extruded and incisors intruded slightly*
- Inter-molar Width: *Maintained*
- Inter-canine Width: *Maintained*

Facial Esthetics:

- An acceptable profile with competent lips was maintained

Retention

The patient was instructed to wear the upper and lower clear overlay retainers full time for the first 6 months and nights only thereafter. Home care and retainer maintenance instructions were provided.

Final Evaluation of Treatment

The crowded, asymmetric malocclusion (Figs. 2 and 3) was corrected to Class I, but there was still a Class II tendency in the right buccal segment. The #30 edentulous space was closed and the #14 space was opened for an implant-supported prosthesis. Although the mandible was rotated posteriorly ~2mm, a pleasing profile with competent lips was achieved. The Cast-Radiograph Evaluation (CRE) score was 22 points.

The major discrepancies were alignment/rotation (4 points), marginal ridges (4 points), occlusal contacts (6 points), occlusal relationships (5 points), and root angulation (3 points). The following deviations from ideal were noted:

- The upper left second premolar and lower right lateral incisor were rotated mesial in, and the lower right second premolar was flared buccally.
- Marginal ridge discrepancies were noted in both the upper and lower buccal segments.
- Occlusal contacts were lacking for three buccal and two palatal cusps.
- The Class II occlusal relationship was not completely corrected on the right side.
- Root angulation problems were observed for the upper left second molar, lower left second premolar, and lower right third molar, that was moved into the second molar position.

A root resorption tendency (Fig. 8) was noted for the lower right second premolar (#29), a tooth that had a short root pre-treatment (Fig. 7). The patient was informed that this problem should be closely evaluated with long term follow-up. Despite a few minor alignment problems as noted in the CRE score, and a slight opening of the bite (Fig. 10), the interdisciplinary outcome for this complex, asymmetric malocclusion was very good.

Discussion

Increasing numbers of orthodontic patients are adults presenting with complex malocclusions, involving missing teeth, caries and/or periodontal disease. The treatment priority is to achieve

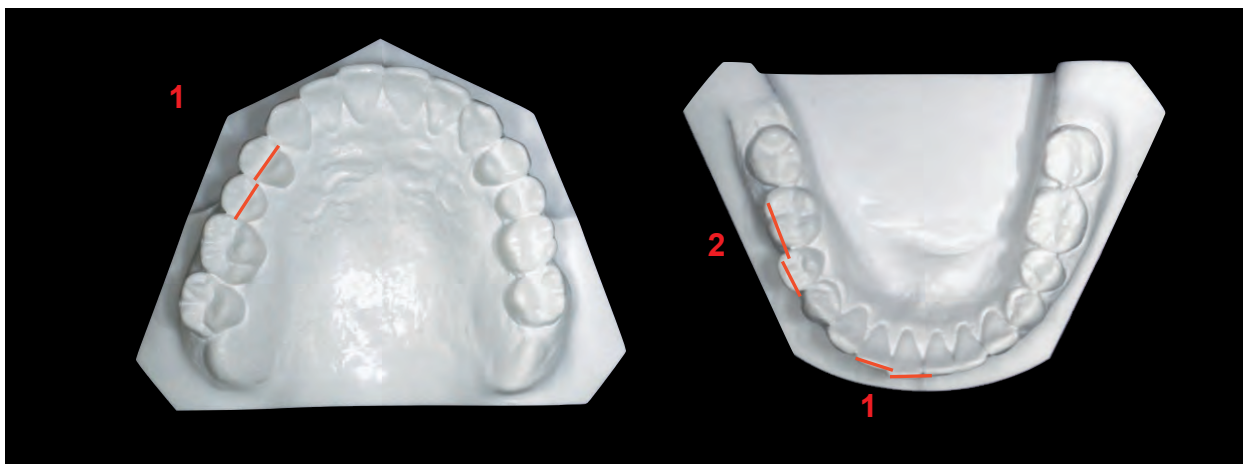
optimal function and esthetics with a minimal prosthetics and treatment time. The present patient presented with a relatively common problem: acquired malocclusion secondary to the asymmetric loss of upper and lower first molars. The etiology for the isolated loss of first molars is often a hypomineralization defect that renders the newly erupted first molars highly susceptible to caries.¹ The problem may involve one or more of the permanent first molars and incisors, and the prevalence is >9% in children sampled all over the world. Incisor defects may be noticed by parents, but the first indication of hypomineralized first molars is often the pain associated with an abscess. The "bombed-out" carious molars are usually untreatable and must be extracted, often only a year to two after eruption. The early loss of first permanent molars usually results in acquired malocclusions (Fig. 7). When second and third molars are retained in an affected quadrant, space closure may be the best option. If only one molar remains, an ISP may be the treatment choice (Fig. 8).

The treatment plan for the current patient was to create space for an upper left single implant-supported prosthesis and close the edentulous space in the lower arch. When creating space, an open coil spring is used to open the extraction site, and the archwire must be a little longer than normal to prevent it from being displaced by mastication (Fig. 15). The wire extending through the terminal molar tube may be an irritation, so a good option is to bond a bead of light-cured resin on the end of the wire.

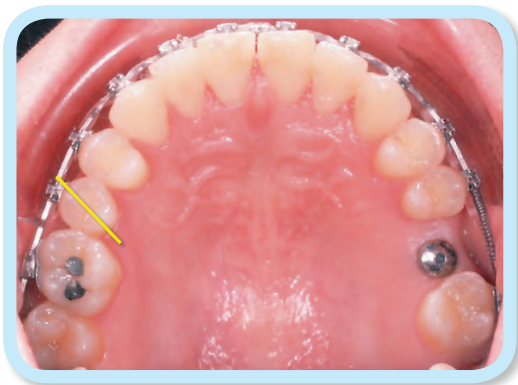When asymmetric spaces are closed, there may be problems with axial inclinations in the buccal segments. When closing large spaces, elastomeric chains on both the buccal and lingual surfaces considerably enhance the efficiency of space closure and helps avoid iatrogenic alignment problems. For instance, applying force only on the buccal surface usually results in distal-out rotation of the terminal molar in the anchorage unit. Another concern with

space closure is excessive retraction of the incisors, resulting in a facial profile compromise. Torque control with incisor bracket selection and/or third order adjustment of archwires are important factors in achieving optimal outcomes.

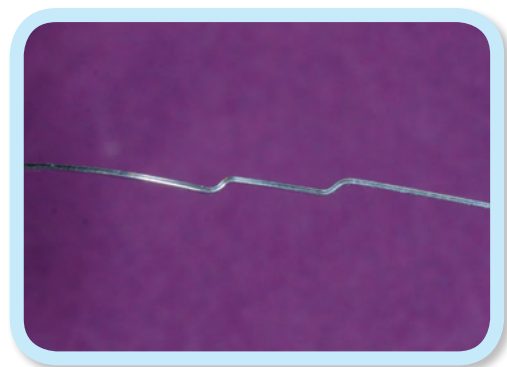The ABO Cast-Radiograph Evaluation (CRE) score was 22 points (Fig. 30). Although this is an excellent final score, some significant deficiencies were noted:



■ Fig. 30: The CRE: Alignment/Rotations were scored at 4 points as indicated by the red lines.



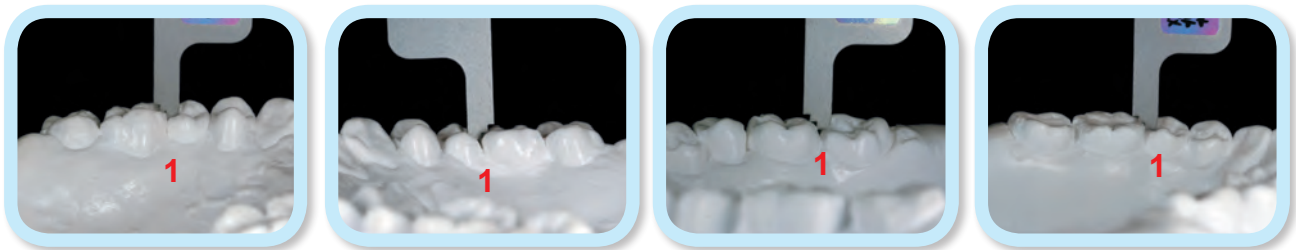■ Fig. 31: The bracket of tooth #4 was not properly positioned relative to the central axis of the tooth (yellow line).



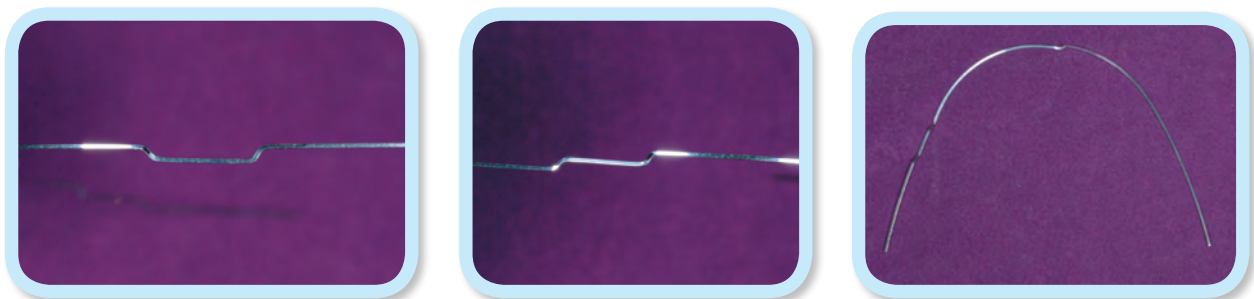
■ Fig. 32: First order (step) bends were used to correct the alignment of #25.

- **Alignment / rotation:** in the 23rd month of treatment a radiograph revealed that the bracket on tooth #4 failed to correct its rotation (Fig. 31), so it was repositioned. Also an archwire adjustment was needed to correct the alignment of tooth #25 (Fig. 32). Tooth #28 had an axial inclination discrepancy, that could be corrected with a cross elastic (*Chipmunk 1/8, 3.5oz.*) from a lingual button on tooth #5 to the bracket of tooth #28.
- **Marginal ridges:** marginal ridge discrepancies (Fig. 33) are best corrected by bracket repositioning and/or archwire adjustment (*detailing*) as shown in Fig. 34.
- **Occlusal contacts:** At the finishing stage, occlusal contacts are best optimized by sectioning the archwire distal to canines bilaterally, and then applying continuous vertical elastics to settle the occlusion.^{7,8}
- **Occlusal relationships:** The right side class II occlusal relationship may have been a residual problem due to asymmetric size and shape of condyles (Figs. 35-36). Condylar morphology is consistent with a burned-out hyperplasia of the right mandibular condyle (Fig. 7). The best solution for the residual Class II problem was interproximal stripping of the lower incisors and then retracting them to create overjet; simultaneously, the buccal segment can be corrected with a unilateral Class II elastic. The latter must be applied judiciously to avoid a cant in the occlusal plane.
- **Root angulation:** Repositioning brackets is the best solution for root angulation and paralleling.

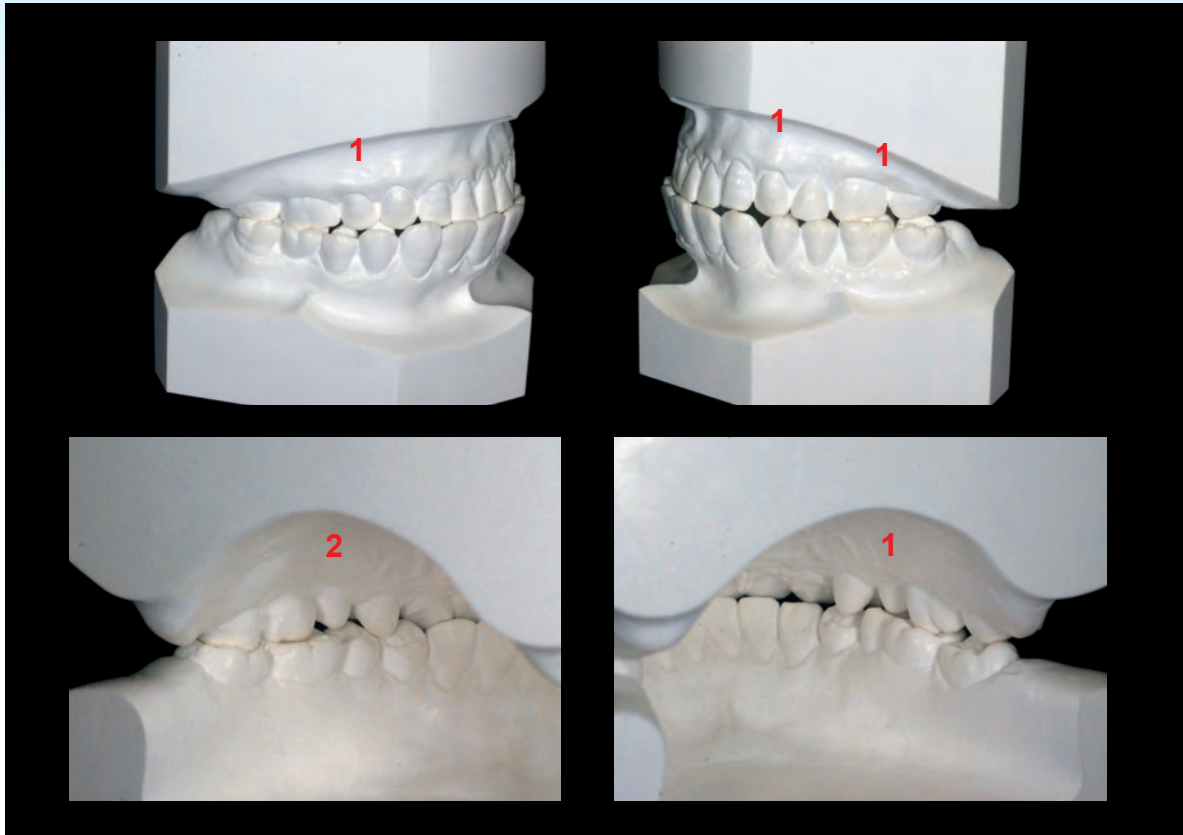
The lower right second premolar had a short root at the start of treatment (Fig. 7), and was even shorter after treatment (Fig. 8). This tooth was apparently



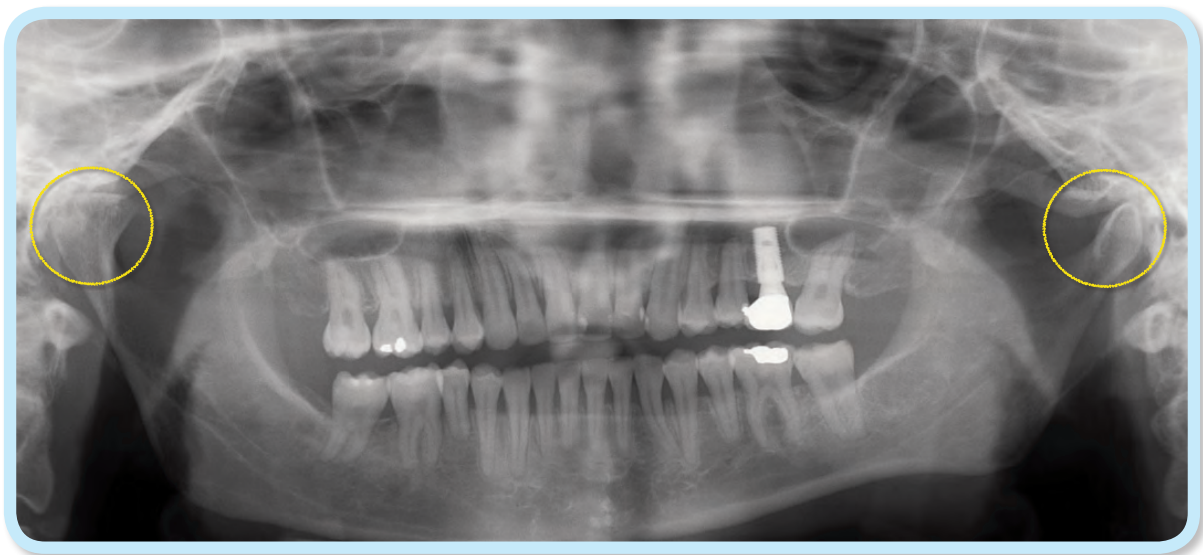
■ Fig. 33: The CRE Four marginal ridge discrepancies were scored 1 point each (red mark) for a total of 4 points.



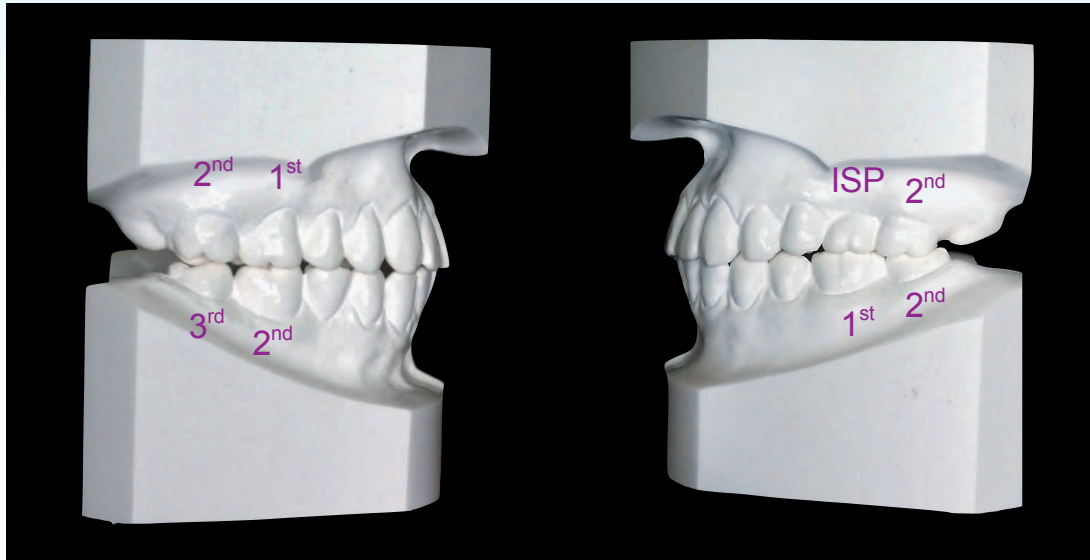
■ Fig. 34: Detailing bends



■ Fig. 35-a and b: The CRE Occlusal contacts was scored 1 or 2 points each (red marks) for a total of 6 points.



■ Fig. 35: The CRE: Root angulation was scored 3 points. Note the asymmetric size and shape of condyles (yellow circles). The root resorption of #29 should be followed up long term.



■ Fig. 36:

The CRE: Occlusal relationships was scored at 5 points because of the Class II interdigitation of all of the maxillary teeth in the right buccal segment. 1st, 2nd, 3rd means ordinal number of molars; ISP means implant-supported prosthesis.

predisposed to root resorption. Orthodontically induced inflammatory root resorption (OIIRR) is a serious sequela of orthodontic treatment. Evidence suggests that comprehensive orthodontic treatment increases the incidence and severity of root resorption.⁹ Numerous investigators have attempted to elucidate factors contributing to and/or causing apical root resorption. The etiologic factors are complex and multifactorial, but the pattern that is emerging is a combination of individual biologic variability, genetic predisposition, and the effect of mechanical factors.^{10,11} Bite turbos may be helpful in controlling root resorption because they tend to decrease occlusal interferences.¹²

It is clear that cortical bone is more resistant to resorption, so it may slow tooth movement and/or result in more root resorption.¹³ However, dense

cortical bone may form within the alveolar process, and it is uncertain how they affect tooth movement. This situation may be encountered in an atrophic extraction site, particularly when a molar or premolar was lost at an early age. It may be difficult to close an atrophic extraction site, and the prevalence of root resorption could increase.¹³ In this regard, the etiology of the progressive root resorption of tooth #29 may be cortical bone resistance when the tooth was rotated (Fig. 8).

Another factor in root resorption is individual biological variation. The root length before treatment was shorter than other comparable teeth, suggesting #29 was prone to root resorption. The rule of thumb indicates that it is better to inform early than to apologize later. In retrospect, the patient should have been informed about the risk of

root resorption prior to treatment. Progressive root resorption may result in an unfavorable crown-root ratio. Regular follow-up of a compromised tooth or teeth is indicated.

Conclusion

Adults may have crowded dentitions, despite multiple missing teeth. This scenario may present challenging asymmetric malocclusions, that are difficult to manage with cost-efficient, comprehensive treatment. Preprosthetic orthodontics to close space and optimize intermaxillary interdigitation is often a good option. Then residual edentulous spaces can be restored with single-tooth replacement, implant-supported prostheses.

References

1. Elfrink MEC, Ten Cate JM, Jaddoe VWV, et al. Deciduous molar hypomineralization and molarincisor hypomineralization. *J Dent Res* 2012;91(6):551-555.
2. Chang CH. Advanced Damon Course No.4,5: DI & CRE Workshop (1)(2). Procast Encyclopedia in Orthodontics. Hsinchu: Newton's A Ltd; 2011.
3. Chang CH. Advanced Damon Course No.1: Extraction Decision-making Tree. Procast Encyclopedia in Orthodontics. Hsinchu: Newton's A Ltd; 2011.
4. Chang CH. The 2B-3D rule for implant planning, placement and restoration. *Int J Ortho Implantol* 2012;27:96-101.
5. Chang CH. Basic Damon Course No.5: Finish Bending. Procast Encyclopedia in Orthodontics. Hsinchu: Newton's A Ltd; 2011.
6. Pitts TR. Begin with the end in minds: Bracket placement and early elastic protocols for smile arc protection. *Clinical Impressions* 2009;17:2-11.
7. Huang S. Tom Pitts' Secrets of Excellent Finishing. *News & Trends in Orthodontics* 2009;14:6-23.
8. Steffen JM, Haltom FT. The five-cent tooth positioner. *J Clin Orthod* 1987;21:528-529.
9. Weltman B, Katherine WL, Fields HW, Shanker S, Kaizar EE. Root resorption associated with orthodontic tooth movement: A systematic review. *Am J Orthod Dentofacial Orthop* 2010;137:462-76.
10. Stenvik A, Mjor IA. Pulp and dentine reactions to experimental tooth intrusion. A histological study of the initial changes. *Am J Orthod* 1970;5:370-85.
11. Sameshima GT, Sinclair PM. Predicting and preventing root resorption: part I. Diagnostic factors. *Am J Orthod Dentofacial Orthop* 2001;119:505-10.
12. Mayes JH. Bite Turbos. New levels of bite-opening acceleration. *Clinical Impression* 1997;6:15-17.
13. Proffit WR, Fields HW, Sarver DM. Contemporary orthodontics 4th ed. 2007;9:357-362.



Discrepancy Index Worksheet

TOTAL D.I. SCORE 16

OVERJET

- 0 mm. (edge-to-edge) =
- 1 – 3 mm. = 0 pts.
- 3.1 – 5 mm. = 2 pts.
- 5.1 – 7 mm. = 3 pts.
- 7.1 – 9 mm. = 4 pts.
- > 9 mm. = 5 pts.

Negative OJ (x-bite) 1 pt. per mm. per tooth =

Total = 0

OVERBITE

- 0 – 3 mm. = 0 pts.
- 3.1 – 5 mm. = 2 pts.
- 5.1 – 7 mm. = 3 pts.
- Impinging (100%) = 5 pts.

Total = 2

ANTERIOR OPEN BITE

0 mm. (edge-to-edge), 1 pt. per tooth
then 1 pt. per additional full mm. per tooth

Total = 0

LATERAL OPEN BITE

2 pts. per mm. per tooth

Total = 0

CROWDING (only one arch)

- 1 – 3 mm. = 1 pt.
- 3.1 – 5 mm. = 2 pts.
- 5.1 – 7 mm. = 4 pts.
- > 7 mm. = 7 pts.

Total = 7

OCCLUSION

- Class I to end on = 0 pts.
- End on Class II or III = 2 pts. per side 2 pts.
- Full Class II or III = 4 pts. per side pts.
- Beyond Class II or III = 1 pt. per mm. pts.
additional

Total = 2

LINGUAL POSTERIOR X-BITE

1 pt. per tooth Total = 0

BUCCAL POSTERIOR X-BITE

2 pts. per tooth Total = 0

CEPHALOMETRICS (See Instructions)

ANB $\geq 6^\circ$ or $\leq -2^\circ$ = 4 pts.

Each degree $< -2^\circ$ _____ x 1 pt. = _____

Each degree $> 6^\circ$ _____ x 1 pt. = _____

SN-MP

$\geq 38^\circ$ = 2 pts.

Each degree $> 38^\circ$ _____ x 2 pts. = _____

$\leq 26^\circ$ = 1 pt.

Each degree $< 26^\circ$ _____ x 1 pt. = _____

1 to MP $\geq 99^\circ$ = 1 pt.

Each degree $> 99^\circ$ _____ x 1 pt. = _____

Total = 2

OTHER (See Instructions)

- Supernumerary teeth _____ x 1 pt. = _____
- Ankylosis of perm. teeth _____ x 2 pts. = _____
- Anomalous morphology _____ x 2 pts. = _____
- Impaction (except 3rd molars) _____ x 2 pts. = _____
- Midline discrepancy (≥ 3 mm) _____ @ 2 pts. = _____
- Missing teeth (except 3rd molars) 2 x 1 pts. = 2
- Missing teeth, congenital _____ x 2 pts. = _____
- Spacing (4 or more, per arch) _____ x 2 pts. = _____
- Spacing (Mx cent. diastema ≥ 2 mm) _____ @ 2 pts. = _____
- Tooth transposition _____ x 2 pts. = _____
- Skeletal asymmetry (nonsurgical tx) _____ @ 3 pts. = _____
- Addl. treatment complexities _____ x 2 pts. = _____

Identify:

Total = 2

IMPLANT SITE

- Lip line : Low (0 pt), Medium (1 pt), High (2 pts) = _____
- Gingival biotype : Low-scalloped, thick (0 pt), Medium-scalloped, medium-thick (1 pt), High-scalloped, thin (2 pts) = _____ 1
- Shape of tooth crowns : Rectangular (0 pt), Triangular (2 pts) = _____
- Bone level at adjacent teeth : ≤ 5 mm to contact point (0 pt), 5.5 to 6.5 mm to contact point (1 pt), ≥ 7 mm to contact point (2 pts) = _____
- Bone anatomy of alveolar crest : H&V sufficient (0 pt), Deficient H, allow simultaneous augment (1 pt), Deficient H, require prior grafting (2 pts), Deficient V or Both H&V (3 pts) = _____
- Soft tissue anatomy : Intact (0 pt), Defective (2 pts) = _____
- Infection at implant site : None (0 pt), Chronic (1 pt), Acute (2 pts) = _____

Total = 1

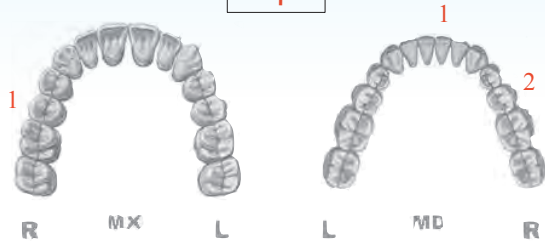
Cast-Radiograph Evaluation

Case # Patient

Total Score: **22**

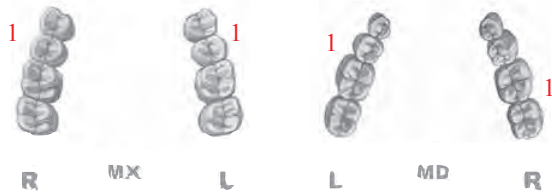
Alignment/Rotations

4



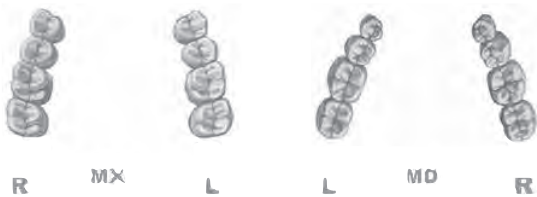
Marginal Ridges

4



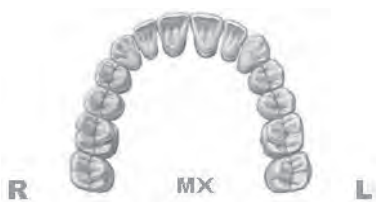Buccolingual Inclination

0



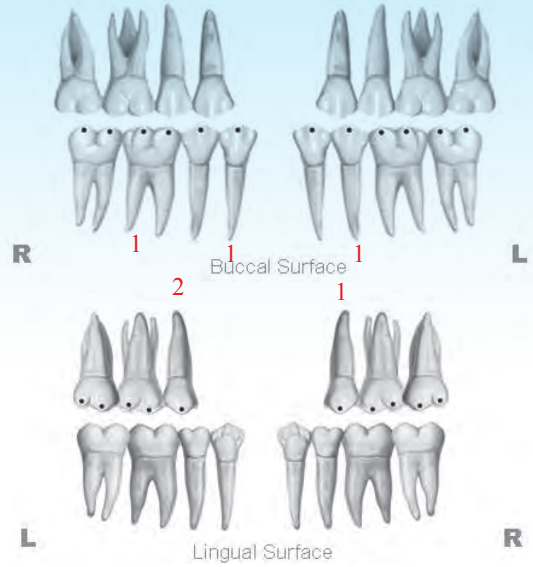
Overjet

0



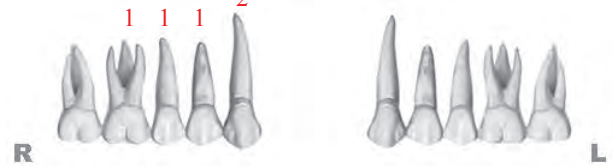Occlusal Contacts

6



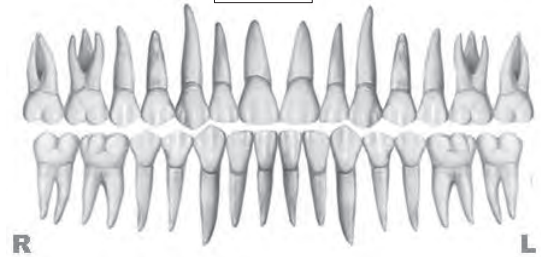
Occlusal Relationships

5



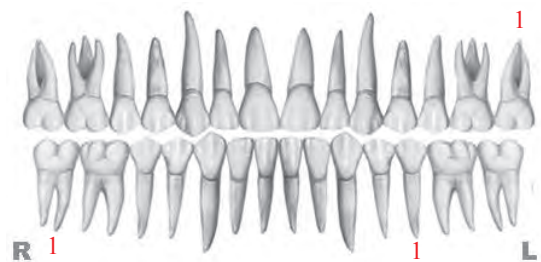
Interproximal Contacts

0



Root Angulation

3

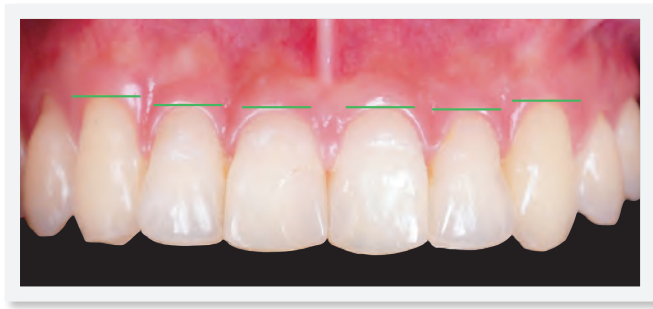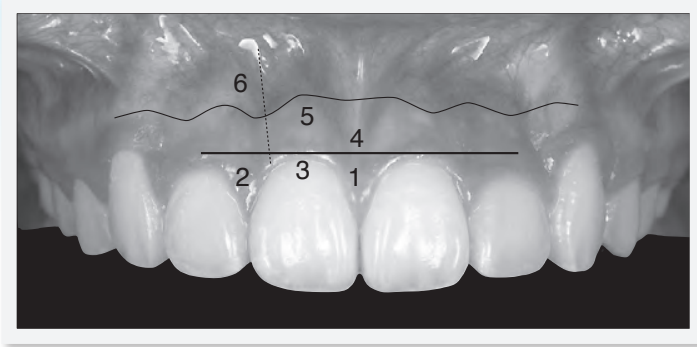


INSTRUCTIONS: Place score beside each deficient tooth and enter total score for each parameter in the white box. Mark extracted teeth with "X". Second molars should be in occlusion.

IBOI Pink & White Esthetic Score (Before Surgical Crown Lengthening)

Total Score: = 3

1. Pink Esthetic Score

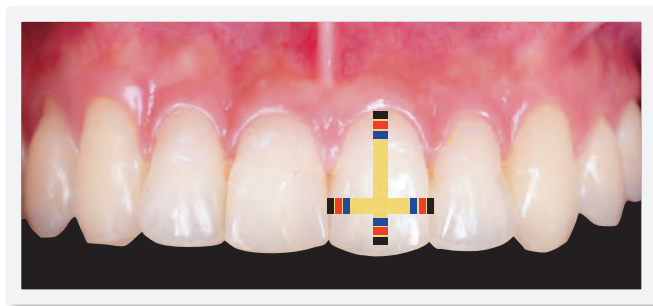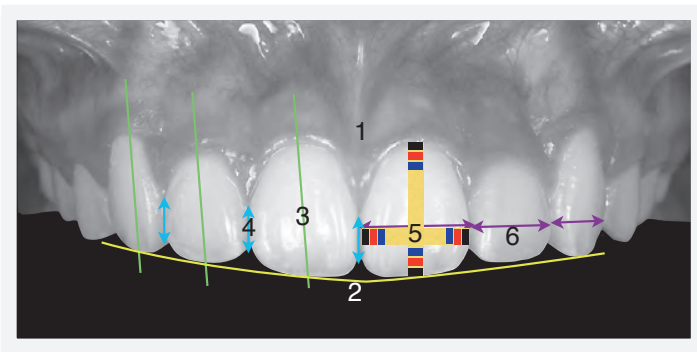


1. M & D Papilla	0	1	2
2. Distal Papilla	0	1	2
3. Curvature of Gingival Margin	0	1	2
4. Level of Gingival Margin	0	1	2
5. Root Convexity (Torque)	0	1	2
6. Scar Formation	0	1	2

Total = 1

1. M & D Papilla	0	1	2
2. Keratinized Gingiva	0	1	2
3. Curvature of Gingival Margin	0	1	2
4. Level of Gingival Margin	0	1	2
5. Root Convexity (Torque)	0	1	2
6. Scar Formation	0	1	2

2. White Esthetic Score (for Micro-esthetics)



1. Midline	0	1	2
2. Incisor Curve	0	1	2
3. Axial Inclination (5°, 8°, 10°)	0	1	2
4. Contact Area (50%, 40%, 30%)	0	1	2
5. Tooth Proportion (1:0.8)	0	1	2
6. Tooth to Tooth Proportion	0	1	2

Total = 2



1. Midline	0	1	2
2. Incisor Curve	0	1	2
3. Axial Inclination (5°, 8°, 10°)	0	1	2
4. Contact Area (50%, 40%, 30%)	0	1	2
5. Tooth Proportion (1:0.8)	0	1	2
6. Tooth to Tooth Proportion	0	1	2

Implant-Abutment Transition & Position Analysis

3. Implant Position

Implant Position

1. M-D	2. B-L	3. Depth	4. Angulation	5. Distance to tooth
Center	2mm	3mm	Max. 15°	≥ 1.5mm

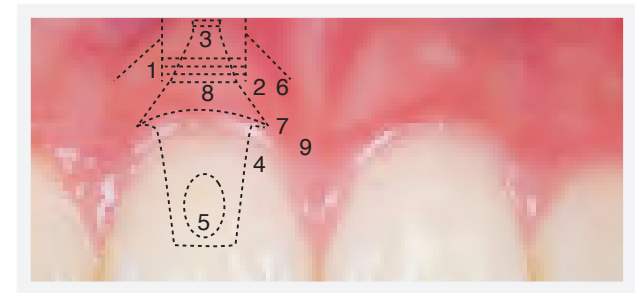



Total = 0

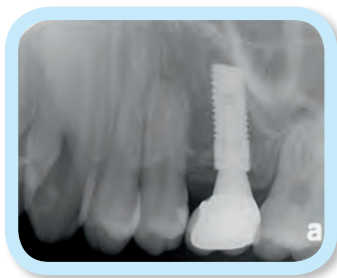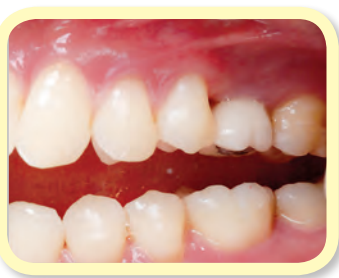- | | | | |
|---------------------------------|---|---|---|
| 1. M & D (Center) | 0 | 1 | 2 |
| 2. B & L (Buccal 2 mm) | 0 | 1 | 2 |
| 3. Depth (3 mm) | 0 | 1 | 2 |
| 4. Angulation (Max. 15°) | 0 | 1 | 2 |
| 5. Distance to Adjacent Anatomy | 0 | 1 | 2 |

- | | | | |
|---------------------------------|---|---|---|
| 1. M & D (Center) | 0 | 1 | 2 |
| 2. B & L (Buccal 2 mm) | 0 | 1 | 2 |
| 3. Depth (3 mm) | 0 | 1 | 2 |
| 4. Angulation (Max. 15°) | 0 | 1 | 2 |
| 5. Distance to Adjacent Anatomy | 0 | 1 | 2 |

4. Abutment transition Contour



E : external connection,
 I : internal connection,
 S : screw type,
 C : cement type,
 P : palatal/central,
 B : buccal



Total = 1

- | | | | | |
|------------------------------|---|---|---|-----|
| 1. Fixture Cervical Design | N | Y | | |
| 2. Platform Switch | N | Y | | |
| 3. I-A Connection Type | E | I | | |
| 4. Abutment Selection | S | C | | |
| 5. Screw Hole Position | P | B | | |
| 6. Marginal Bone Loss | N | Y | 0 | 1 2 |
| 7. Modified Gingival Contour | N | Y | 0 | 1 2 |
| 8. Gingival Height | N | Y | 0 | 1 2 |
| 9. Crown margin fitness | N | Y | 0 | 1 2 |

- | | | | | |
|------------------------------|---|---|---|---|
| 1. Fixture Cervical Design | N | Y | | |
| 2. Platform Switch | N | Y | | |
| 3. I-A Connection Type | E | I | | |
| 4. Abutment Selection | S | C | | |
| 5. Screw Hole Position | P | B | | |
| 6. Marginal Bone Loss | N | Y | 0 | 1 2 |
| 7. Modified Gingival Contour | N | Y | 0 | 1 2 |
| 8. Gingival Height | N | Y | 0 | 1 2 |
| 9. Crown margin fitness | N | Y | 0 | 1 2 |

International



Dental Clinic Established 1996

Beethoven

Workshop

session 1: 04/26-29, 2016 (Full)

session 2: 10/18-21, 2016 @Taiwan



Damon, OBS & VISTA

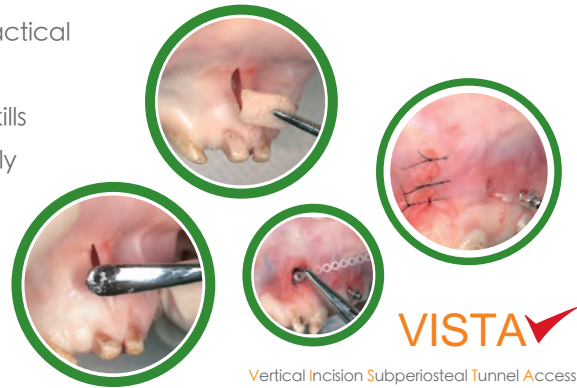

lecture
hands-on
work-shop
surgeries
OBS



Class III
mini screws
chair-side
observation
Damon

Since 2009, Beethoven International Damon, OBS & VISTA Workshop has received over 350 participants from more than 30 countries. This three-day advanced hands-on course combines practical lectures and in-office clinical learning and has attracted orthodontic practitioners worldwide to strengthen their skills and knowledge in the Damon System, TADs and minimally invasive surgeries. In addition to clinical development, participants will be exposed to clinic management and staff training of a world-class orthodontic centre. The optional Keynote workshop will help improve your ability to master professional digital communication. Come join us and be part of a community of excellence.



Dr. Chris Chang

CEO, Beethoven Orthodontic and Implant Group. He received his PhD in bone physiology and Certificate in Orthodontics from Indiana University in 1996. As publisher of *International Journal of Orthodontics & Implantology*, he has been actively involved in the design and application of orthodontic bone screws.



Dr. John Lin

President of the Jin-Jong Lin Orthodontic Clinic. Dr. Lin received his MS. from Marquette University and is an internationally renowned lecturer. He's also the author of *Creative Orthodontics* and consultant to *International Journal of Orthodontics & Implantology*.

THE LECTURERS



Day 123 USD 2,600 Early bird rate: \$200 off by 2016/2/26, 8/18

Day 4 USD 500 Early bird rate: \$100 off by 2016/2/26, 8/18

For more information and registration, visit

<http://iworkshop.beethoven.tw>



course@newtonsa.com.tw
+886-3-5735676 #217 Bella



Dr. David Nissan
Mexico

"More than I expected"



Dr. Lee Hye Jin Serena
Argentina

"Dr. Chris shared his knowledges in details and made the difficult cases look simple."



Dr. Sunish T Daniel
Dubai

"The workshop, all and all was an wholesome experience and I would definitely recommend this course to my friends."



Dr. Joanna Lim
Singapore

"Truly inspirational"



Prof. Dr. Paulo Fernandes Retto
Portugal

"Dr. Angle would be glad to know that contemporary orthodontics has a professional as Chris Chang!"



Dr. Amir EDaly
Australia

"Amazing experience"



Dr. Chen Yehong
Malaysia

"The best & smartest choice ever"



Dr. Alejandro Ramirez
Spain

"The best workshop in the world"



Course Schedule

Day 1 Chair-side observation

Day 2 Lecture,
Model workshop,
Chair-side observation

Day 3 VISTA Lecture,
Lecture by Dr. John Lin,
VISTA workshop

Day 4 Keynote workshop 

VISTA

This 4-hour hands-on surgical workshop features minimally invasive procedures for impactions and soft tissue enhancement.

Topics include:

1. VISTA for Screw Placement
2. VISTA for Connective Tissue Graft
3. Suture Techniques

Keynote



Dr. Rungsi Thavarungkul, Thailand
Lecturer, Advanced Keynote Workshop

"If you think this is a computer course that will show you step-by-step how to use the application, please reconsider. If you want to improve communication in your practice, and with patients, this 8-hour course is definitely worth it."

Nonsurgical Treatment of Anterior Open Bite Malocclusion

Abstract

This case report describes the nonsurgical treatment of a 31-years-old female presenting with a chief complaint of anterior open bite malocclusion. A clinical exam revealed that there were spaces between her lower anterior teeth. Orthodontics was indicated to align and level the maxillary dentition and close the mandibular spaces. Anterior early light short elastic (2 oz) was used to solve the open bite problem. Miniscrews in the infrazygomatic crests was applied to retract the upper and lower dentition and intrude the upper posterior segment. It improved her lip profile and reduced the mandibular angle. Class III elastics were used to correct the negative overjet and continuous intermaxillary elastics were prescribed to settle the final occlusion. A marked improvement in anterior open bite correction and occlusal function was achieved. (Int J Orthod Implantol;40:44-63)

Key words:

Anterior open bite malocclusion, early light short elastics, Angle Class I molar relationship, mandibular midline shifted, Damon self-ligating brackets, OrthoBoneScrew, extra-alveolar miniscrews, infrazygomatic crests (IZC), class III elastics, negative overjet, continuous intermaxillary elastics.

History and Etiology

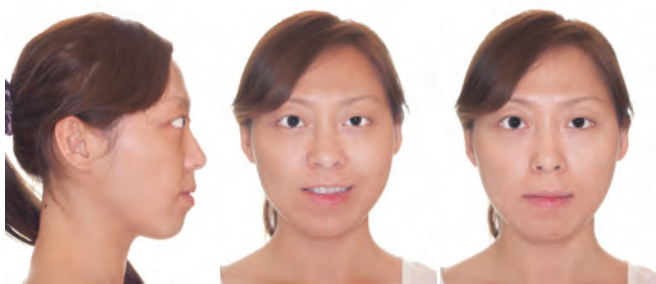A 31-years-old female was referred by her dentist for orthodontic consultation (Fig. 1). Her chief concern was the spaces between her lower teeth (Figs. 2-3). There were no contributory medical problems. A clinical exam revealed that the excess space in the mandibular region was associated with a mandibular midline deviation that was 1.5 mm to the right. The patient had a bilateral Class I molar relationship with a 1.5-2.0 mm open bite from the maxillary right lateral incisor to the left canine (Fig. 2). Her oral hygiene was excellent. A tongue thrust swallowing pattern was noted, which is a common compensation for patients with an anterior open bite. The primary etiology of her anterior open bite appears to be an interincisal posture of the tip of her tongue.

The patient was treated to a pleasing result as shown in Figures 4-9. The cephalometric and panoramic radiographs document the pre-treatment condition (Fig. 7) and the post-treatment results (Fig. 8). The superimposed cephalometric tracings before and after treatment are shown in Fig. 9. The correction of this difficult malocclusion was facilitated by assessing progress records, that were collected about 6 months prior to the anticipated finish.¹

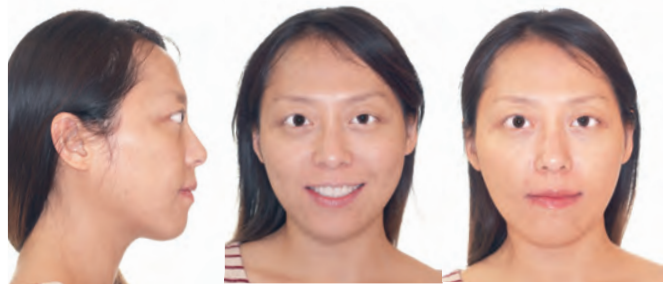Dr. Ming-Jen Chang,
Lecturer, Beethoven Orthodontic Course (Left)

Dr. Chris Chang,
Founder, Beethoven Orthodontic Center
Publisher, International Journal of Orthodontics & Implantology (middle)

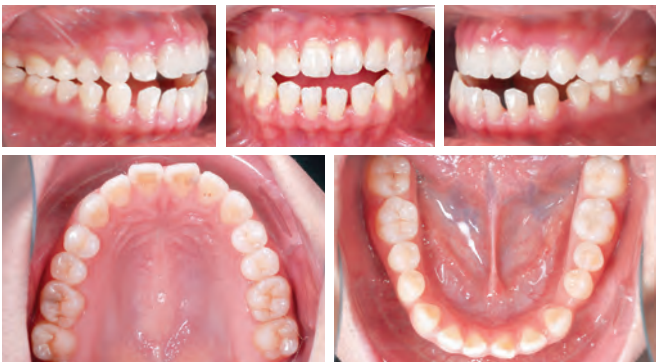W. Eugene Roberts,
Consultant, International Journal of Orthodontics & Implantology (right)



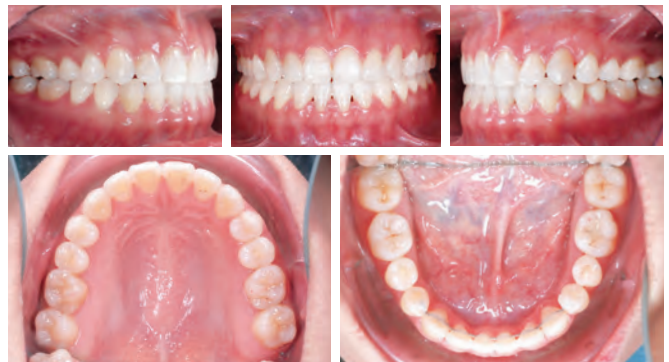■ Fig. 1: Pre-treatment facial photographs



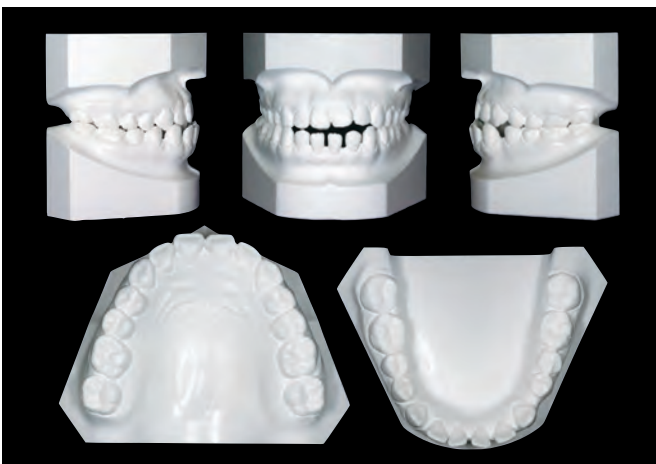■ Fig. 4: Post-treatment facial photographs



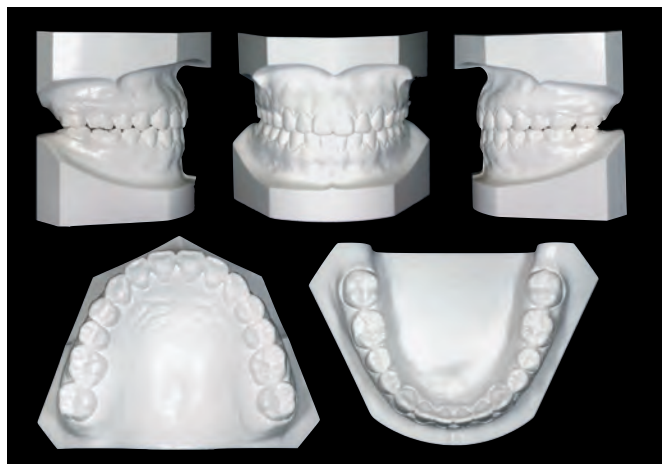■ Fig. 2: Pre-treatment intraoral photographs



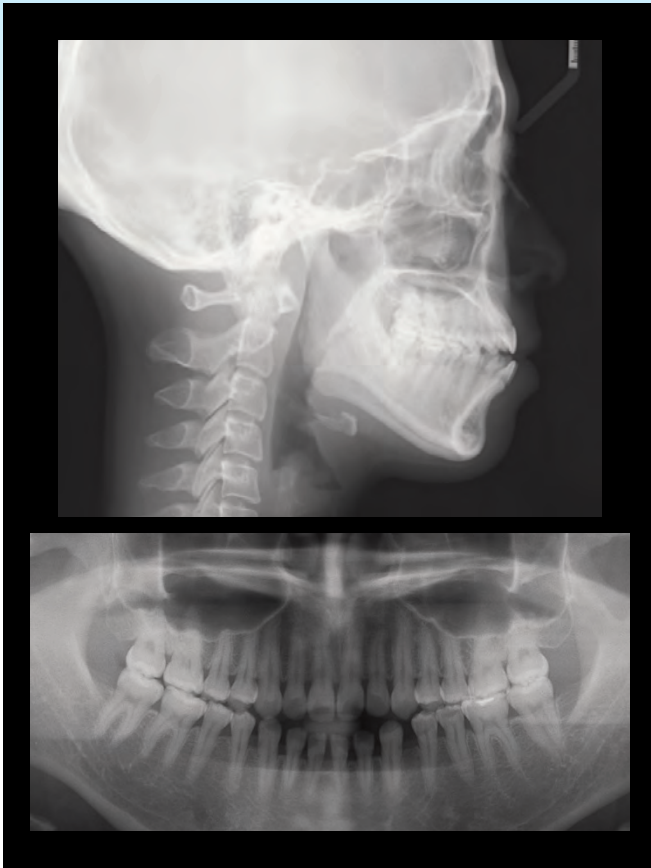
■ Fig. 5: Post-treatment intraoral photographs



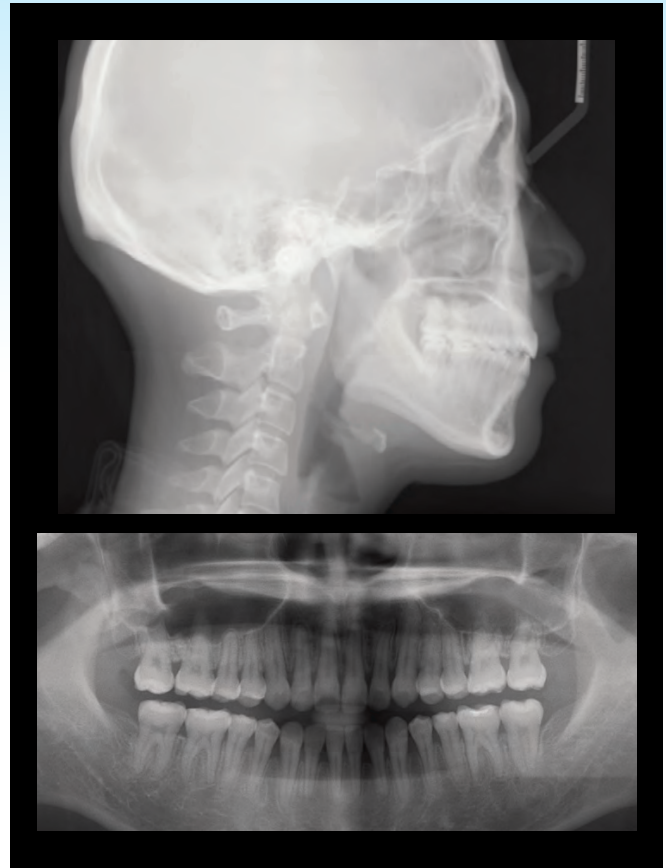
■ Fig. 3: Pre-treatment study models (casts)



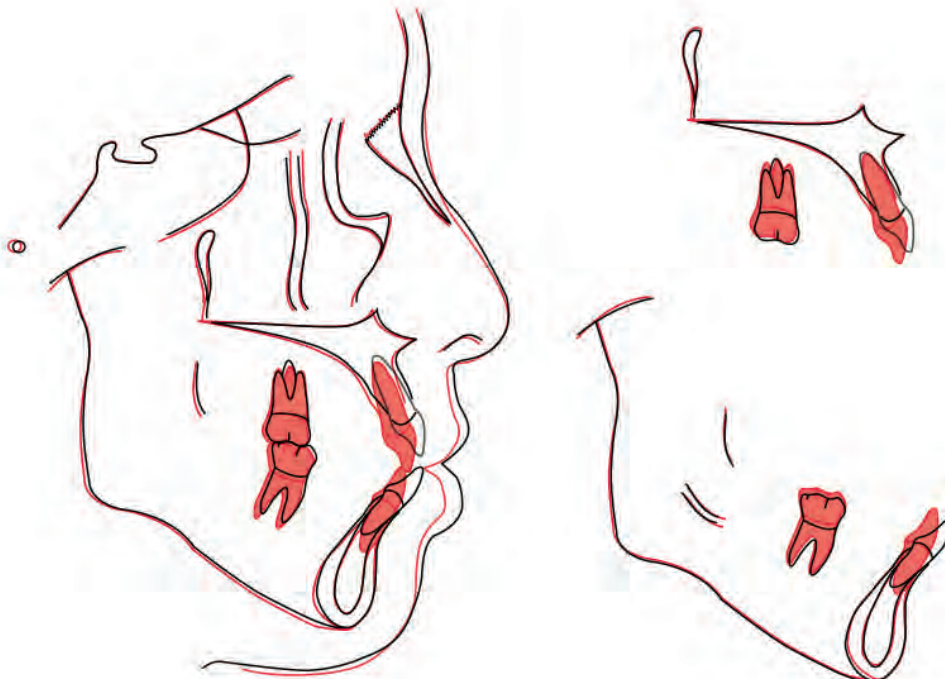
■ Fig. 6: Post-treatment study models (casts)



■ Fig. 7: Pre-treatment cephalometric and panoramic radiographs



■ Fig. 8: Post-treatment cephalometric and panoramic radiographs



■ Fig. 9: Superimposed tracings: Upper and lower incisors were retracted. The upper molars were distalized by miniscrews which were inserted into the infrazygomatic crests (IZC). Significant lip retraction was achieved due to the whole arch distalization. Very little growth was found.

Diagnosis

Facial:

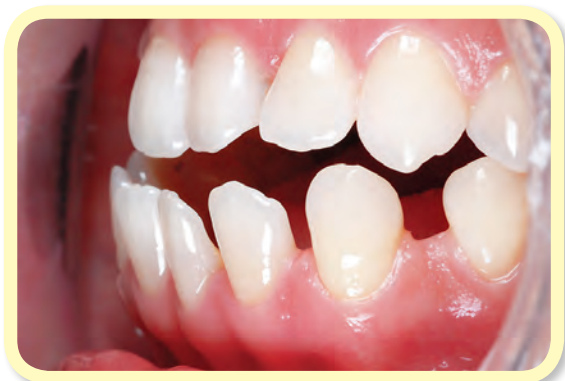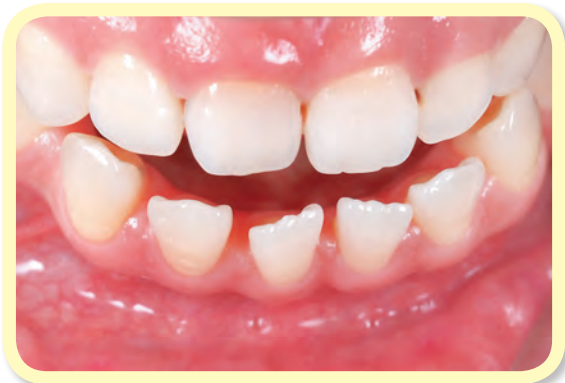- Bimaxillary lip protrusion
- Chin deviates 3mm to the right side

Skeletal:

- Skeletal Class I (SNA 79°, SNB 77°, ANB 2°)
- High mandibular plane angle (SN-MP 36°, FMA 29°)

Dental:

- Angle Classification: *bilateral Class I molar relationship*
- Incisal relationships: *overjet -2 mm, openbite of ~2 mm, and proclined lower incisors (IMPA=106°) (Fig. 10).*



■ Fig. 10:

-2 mm overjet and 2 mm open bite, proclined lower incisors (IMPA=106°)

- Tooth Size Arch Length Discrepancy: *maxillary arch 0 mm, mandibular arch -11 mm*
- Crossbite right canines and first premolars

Radiographic\Panoramic:

- Asymmetric mandible (Fig. 7)

Radiographic\Other:

- Low alveolar bone height in mandibular anterior region

The ABO Discrepancy Index (DI) was 34 as shown in the subsequent worksheet.

Specific Objectives of Treatment

Maxilla:

- A - P: *Maintain*
- Vertical: *Maintain*
- Transverse: *Expand to correct posterior crossbite*

Mandible:

- A - P: *Retract*
- Vertical: *Maintain*
- Transverse: *Maintain*

Maxillary Dentition:

- A - P: *Molars: Retract incisors*
- Vertical: *Extrude incisors*
- Inter-molar Width: *Maintain*
- Inter-canine Width: *Maintain*
- Buccolingual Inclination: *Maintain*

Mandibular Dentition:

- A - P: *Maintain molars and retract incisors*

- Vertical: *Maintain*
- Inter-molar Width: *Maintain*
- Inter-canine Width: *Decrease to correct crossbite*
- Buccolingual Inclination: *Maintain*

Facial Esthetics:

- Correct the lip protrusion.

Other:

- Retract the entire upper and lower dentition to correct the protrusive profile.

Treatment Plan

A non-extraction treatment with a full fixed orthodontic appliance was indicated to align and level the maxillary dentition and close the mandibular anterior spaces. Anterior early light short elastics (2 oz) were planned to resolve the anterior open bite.

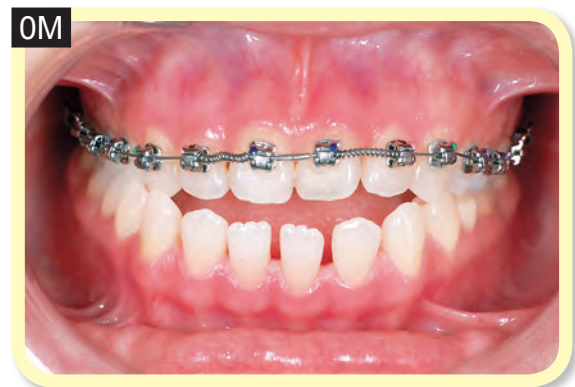Two maxillary extra-alveolar miniscrews will be used to retract the upper and lower dentition to improve the lip profile, as well as to control the upper posterior segment extrusion due to use of Class III elastics. The final occlusion will be detailed with bracket repositioning, archwire adjustment and intermaxillary elastics as needed.

The corrected dentition will be retained with lower anterior fixed retainer as well as clear overlay retainers for both arches. Tongue and muscle training will be reinforced during treatment as well as during the retention period.

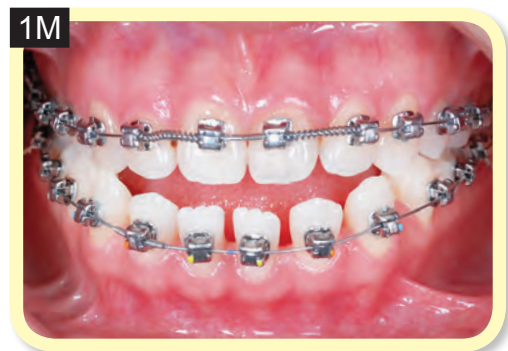Appliances and Treatment Progress

A .022" slot Damon Q® bracket system (Ormco) was used with standard torque brackets on all incisors. The maxillary arch was bonded and .014" CuNiTi archwire was fitted. Open coil springs were placed bilaterally between the central and lateral incisors, to open spaces for restoration of carious lesions on the distal surfaces of both central incisors (Fig. 11).

After one month of initial alignment and leveling in



■ Fig. 11: The maxillary arch was bonded with standard torque brackets in the anterior segment and open coil springs were placed bilaterally between the central incisors and lateral incisors to open spaces for restoration of the distal caries on the two central incisors. A .014 CuNiTi archwire was inserted.



■ Fig. 12: The mandibular arch was bonded with standard torque brackets and fitted with a .014 CuNiTi archwire.

the maxillary arch, the mandibular arch was bonded with standard torque brackets and fitted with a .014" CuNiTi archwire (Fig. 12). The patient was instructed to wear Class III elastics (*Parrot 5/16, 2oz.*) bilaterally full time, from the lower canine to the upper 1st molar to correct the negative overjet.

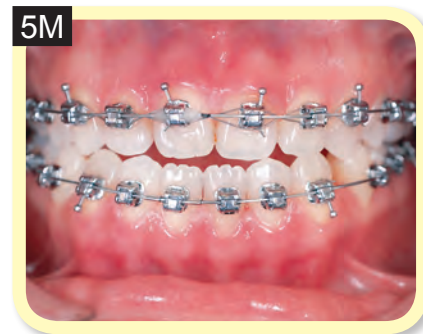Four months after the initiation of treatment, a rectangular .014x.025" CuNiTi wire was placed in the maxillary arch. Drop in hooks were inserted into the brackets of the upper central incisors and lower canines. Early light elastics (*Ostrich 3/4, 2oz.*) were used from the lower canines to the upper central incisors to correct the anterior open bite.

One month later, a .017x.025" low friction TMA archwire, expanded in the posterior, was used on the maxillary arch, and the anterior segment was ligated with a figure-eight tie with a .012" stainless steel ligature. A .014x.025" CuNiTi archwire was fitted for the mandibular arch (Fig. 13). The lower archwire was replaced with a .016x.025" SS.

Eight months after the initiation of treatment, a .019x.025" SS archwire was used on the maxillary arch. After the negative overjet was corrected,

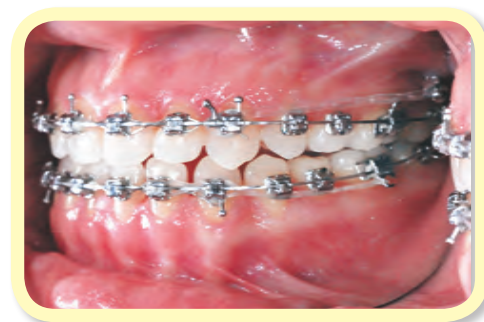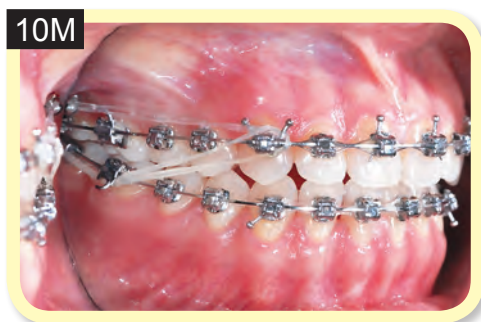
Class II elastics (*Fox 1/4, 3.5oz.*) were worn bilaterally from the upper canine to the lower 1st molar. The following month, the 1.5 mm maxillary midline deviation to the right was addressed by increasing the force of the Class II elastics (*Bear 1/4, 4.5oz.*) and extending the range of action to the lower 2nd molar on the right side.

In the 10th month, two extra-alveolar bone screws (*2x12 mm OrthoBoneScrew[®], Newton's A, Ltd., Hsinchu, Taiwan*) were inserted bilaterally into the infrazygomatic crest (IZC). Elastometric chains were attached from the upper right and left canines to the screws (Fig. 14) to retract the maxillary anterior



■ Fig. 13:

A .017x.025" TMA archwire was used on the maxillary arch; the maxillary anterior segment was ligated with a figure-eight tie of an .012" stainless steel ligature. A .014x.025" CuNiTi archwire was used on the mandibular arch.



■ Fig. 14:

In the 10th month, two miniscrews (*2x12 mm OrthoBoneScrew[®], Newton's A, Ltd., Hsinchu, Taiwan*) were inserted into both infrazygomatic crests. The elastometric chains were attached from the upper right and left canines to the screws.

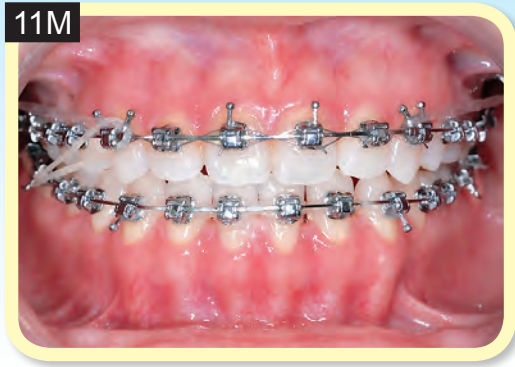

Fig. 15:
The lower midline shift 1mm to right side was noticed. The Class II elastics were kept on the right side only to correct the midline shift.

segment. One month later, a 1mm lower midline shift to the right side was still evident, therefore Class II elastics were maintained on the right side only, for correction of the midline (Fig. 15).

After 13 months of active treatment, interim-treatment records were collected to evaluate the treatment progress and to plan the future treatment (Figs. 16-19).

Interim-Treatment Progress

Maxilla:

- A - P: *Maintained*
- Vertical: *Maintained*
- Transverse: *Maintained*

Mandible:

- A - P: *Maintained*
- Vertical: *Slightly Increased*
- Transverse: *Maintained*

Maxillary Dentition:

- A - P :
 - a. Molars: *Maintained*
 - b. Incisors: *Extruded*
- Vertical:

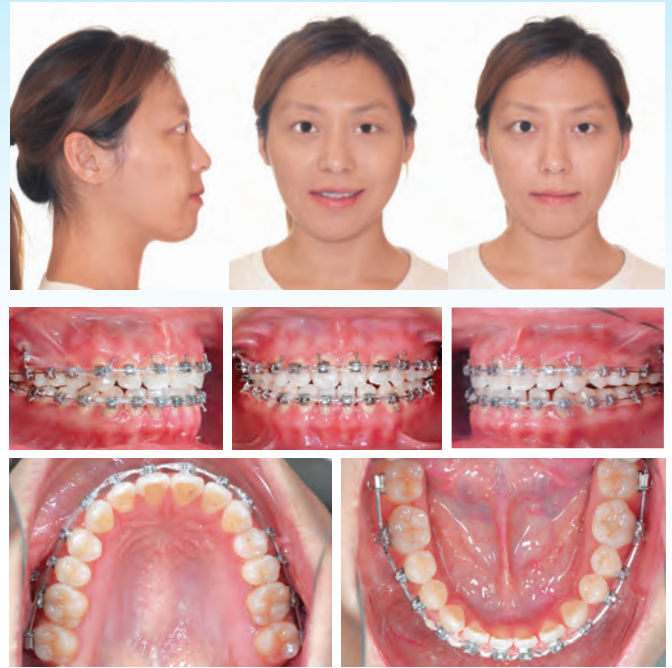

Fig. 16: Interim-treatment facial and intraoral photographs.

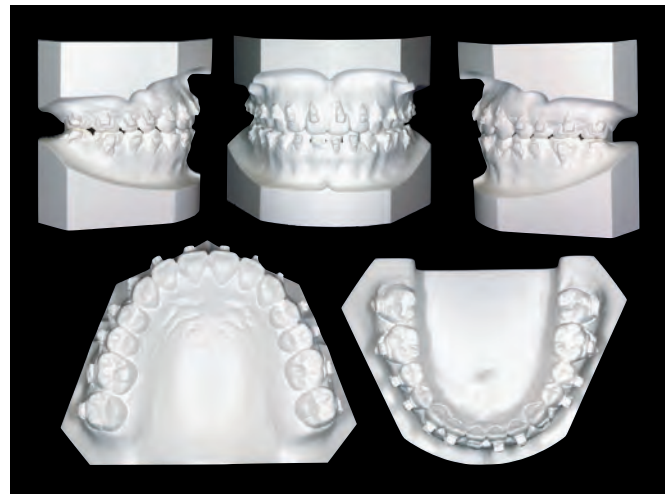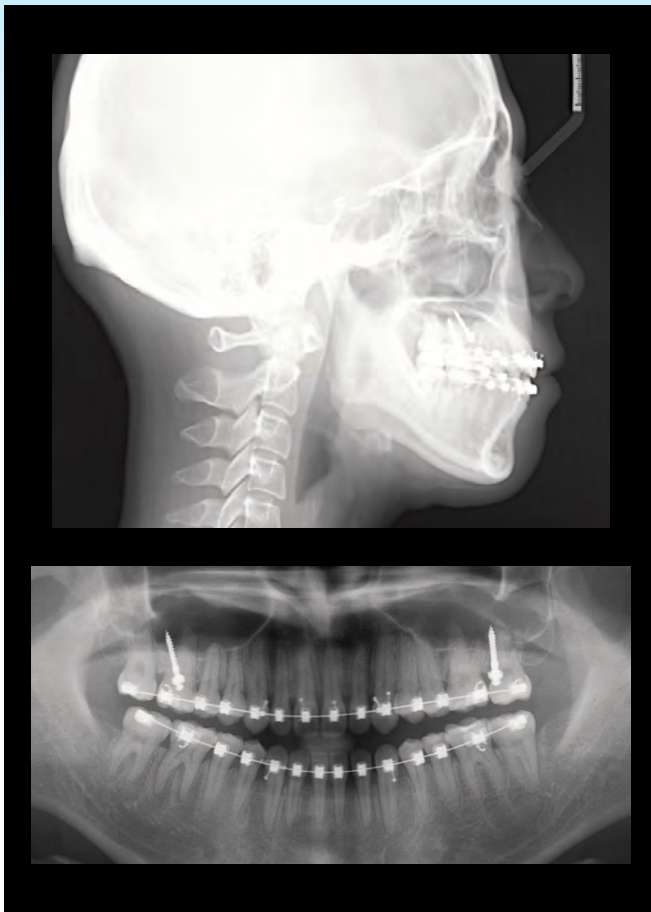


Fig. 17: Interim-treatment study models.

- a. Molars: *Maintained*
- b. Incisors: *Extruded*
- Inter-molar Width: *Expanded*
- Inter-canine Width: *Constricted*
- Buccolingual Inclination: *Maintained*

Mandibular Dentition:

- A - P:
 - a. Molars: *Maintained*
 - b. Incisors: *Extruded*

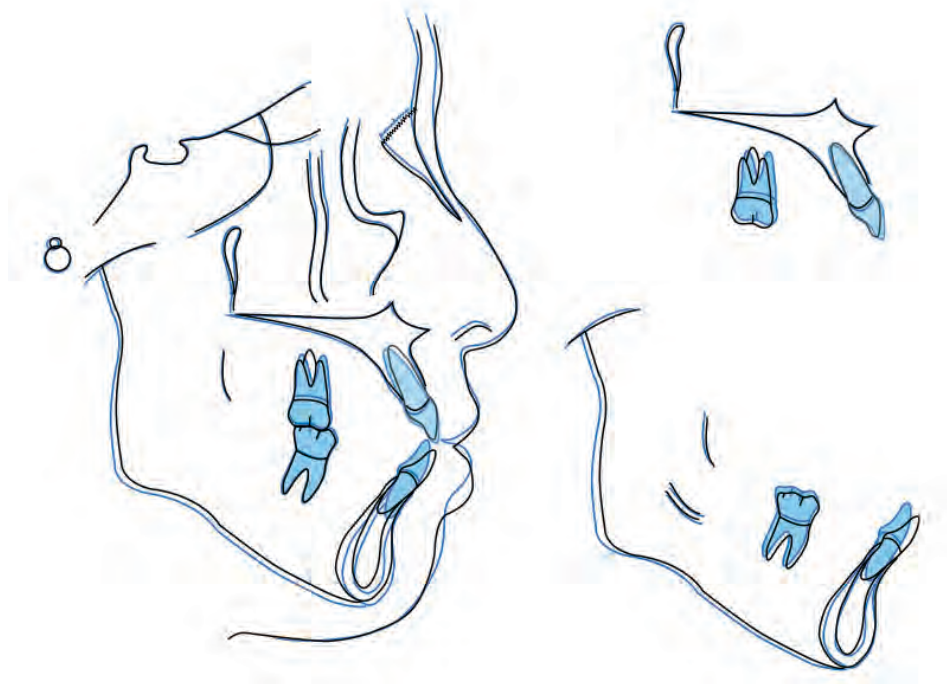


■ Fig. 18: Interim-treatment cephalometric and panoramic radiographs

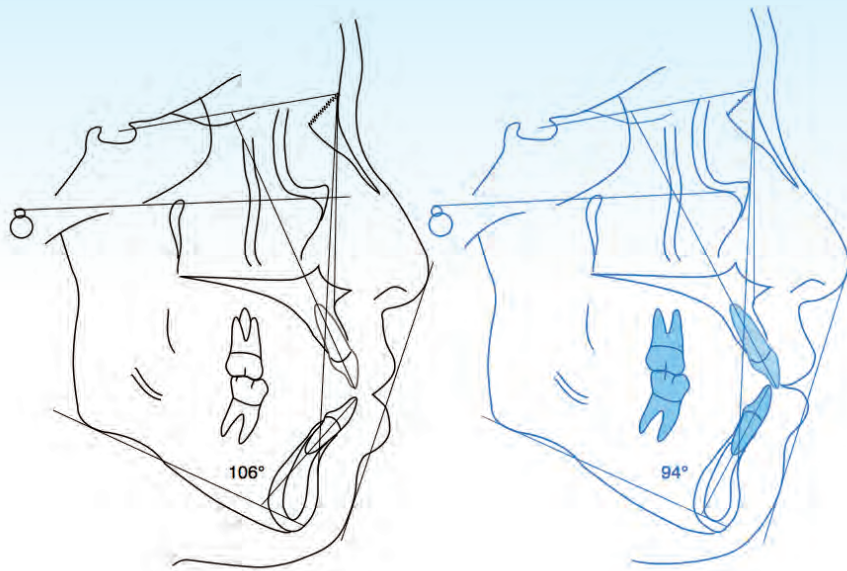
- Vertical:
 - Molars: *Extruded*
 - Incisors: *Extruded*
- Inter-molar Width: *Expanded*
- Inter-canine Width: *Constricted*
- Buccolingual Inclination: *Lingual Tipping*

Anticipated Future Treatment

The interim-treatment assessment revealed that the open bite, spacing and protrusive lower lip had all been improved (Fig. 16). The axial inclination of the lower incisors had been reduced from 106° to 94° (Fig. 20). IZC Miniscrews will be used to further correct the deviated midline and lip protrusion. A progress Cast-Radiograph Evaluation (CRE) score is routinely used about six months before debonding to check for alignment discrepancies (Figs. 21-24). This is a proven method for improving treatment quality.¹ A detailed correction plan was generated based on this CRE score.



■ Fig. 19: Superimposed tracings: Flaring of the lower incisors had been reduced from 106° to 94°.



■ Fig. 20: Flaring of the lower incisors had been reduced from 106° to 94°.

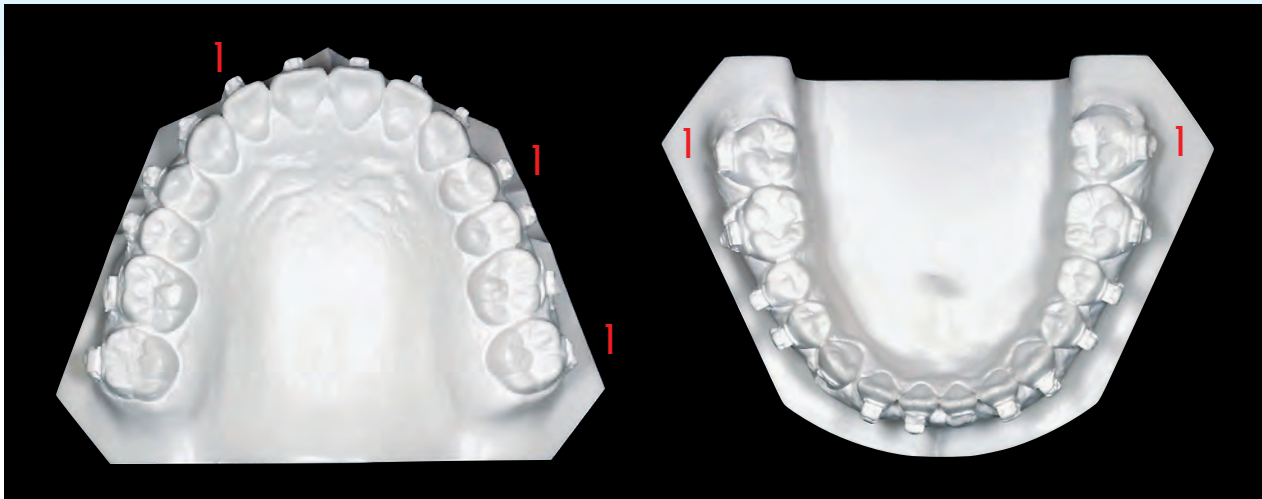
Panoramic radiography was used to check the angulation of the dentition in order to reposition brackets (Fig. 25). Then, the precise “to do list” was formulated to achieve an optimal finish with about 6 more months of treatment. The to do list was based on a progress CRE score of 40:

1. Detailed bending to correct rotations (Fig. 21).
2. Bond lingual buttons on lower 2nd molars and apply criss-cross elastics to correct lingual tipping of the lower 2nd molars and buccal flaring of the upper right 2nd molar (Fig. 22).
3. Retract the upper anterior segment with Class II elastics to reduce the overjet (Fig. 23).
4. IZC miniscrews to be utilized for correction of the deviated midline.
5. Interproximal reduction of lower anterior segment is indicated to reduce black triangles.
6. Arch coordination is needed to improve occlusal relationships and contacts (Fig. 24).

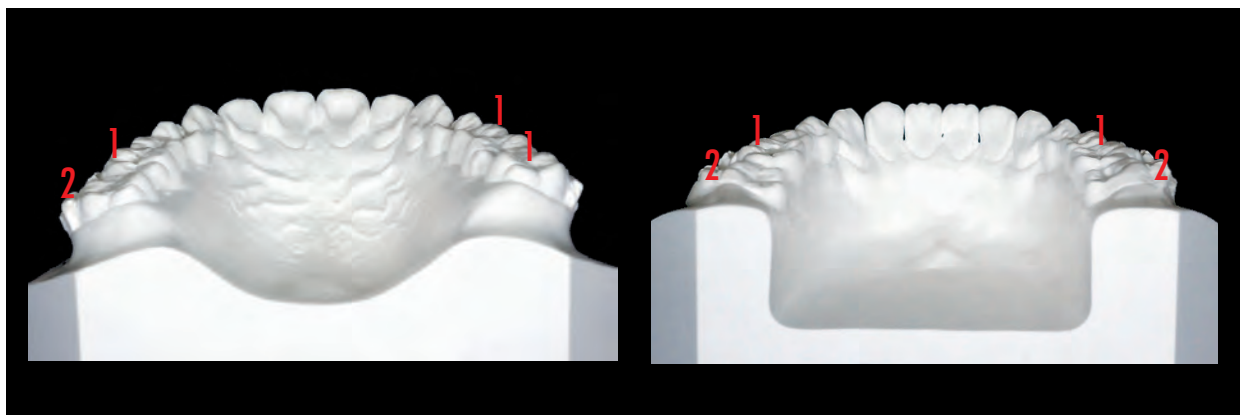
The interproximal contact of lower anterior teeth were stripped to reduce the black triangles (Fig. 26). The midline shift was closely monitored throughout treatment and in the 16th month of progress, the dental midline was corrected to an acceptable position (Fig. 27) and the bone screws were removed one month later. The elastics force to correct the anterior openbite was decreased (*Giraffe 3/4, 3.5oz.*) and Class II elastics (*Fox 1/4, 3.5oz.*) were maintained bilaterally to retract the upper anterior segment to reduce the overjet.

In the 21st month, lingual buttons were bonded on the lower left canine and 1st premolar (Fig. 28) to help close a 1mm space between them. Additionally, triangle elastics (*Chipmunk 1/8, 3.5oz.*) were attached from the upper left canine to the two lingual buttons to improve the occlusal contact (Fig. 29).

Twenty-six months after the initiation of treatment, two torquing springs were placed on each upper



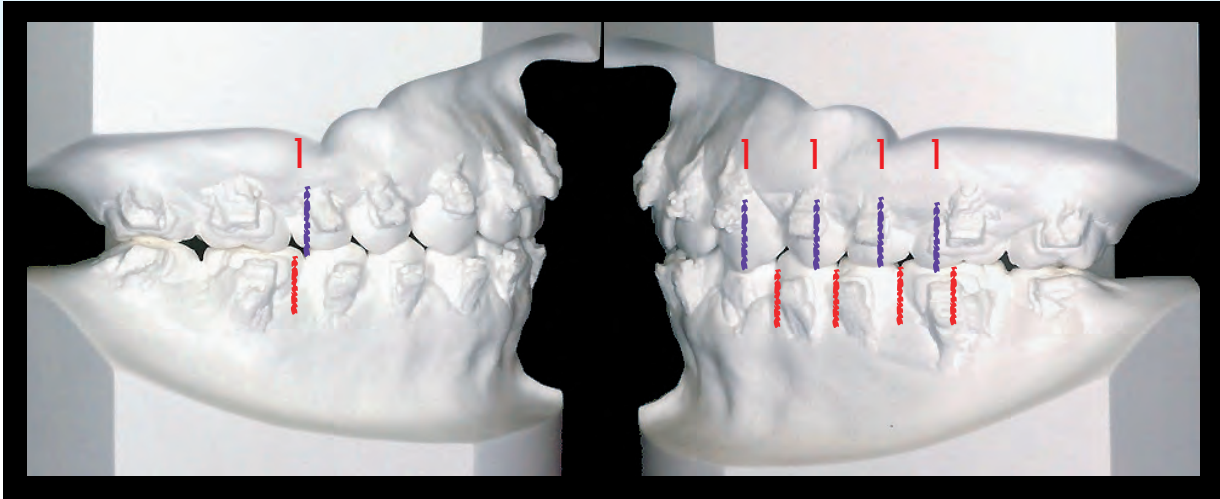
■ Fig. 21: The interim-treatment CRE: Alignment/Rotations was 5.



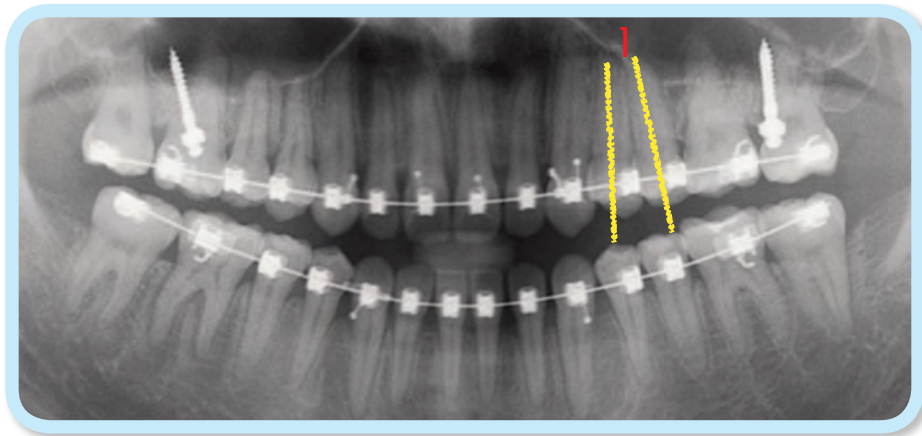
■ Fig. 22: The interim-treatment CRE: Buccolingual inclination was 11.



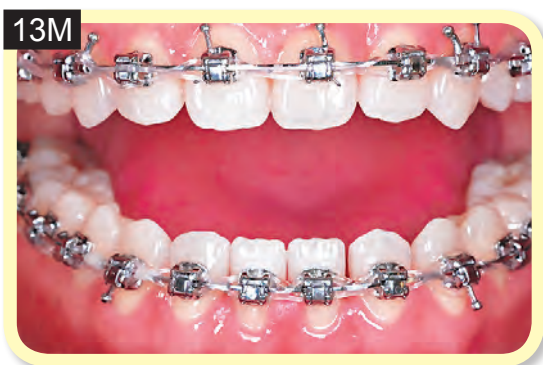■ Fig. 23: The interim-treatment CRE: Overjet was 8.



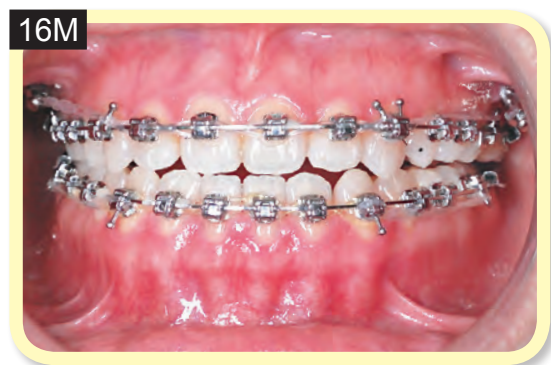■ Fig. 24: The interim-treatment CRE: Occlusal relationships was 5.



■ Fig. 25: The interim-treatment CRE: Root angulation was 1.



■ Fig. 26: The interproximal contact of lower anterior teeth were stripped to reduce the black triangles.



■ Fig. 27: In the 16th month of treatment, the dental midline was set to an acceptable position.

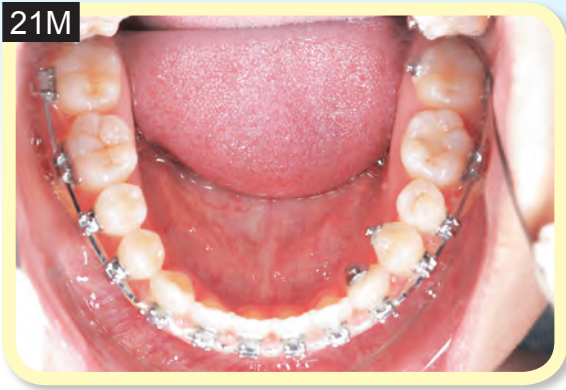

Fig. 28:
Two lingual buttons were bonded on the lower left canine and 1st premolar.

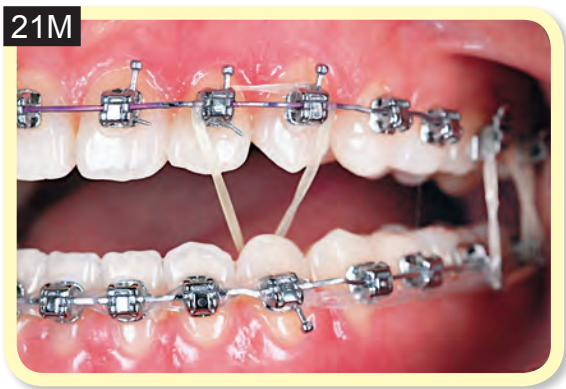

Fig. 29:
The triangle elastics (Chipmunk 1/8, 3.5oz.) were attached from the upper left canine to these two lingual buttons to improve the occlusal contact.

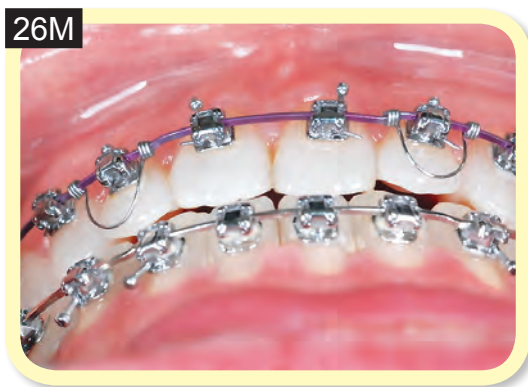

Fig. 30:
Two torquing springs were placed bilaterally on the upper lateral incisors to move the crown palatally.

lateral incisor to move the crowns palatally, as the maxillary arch was leveled (Fig. 30). The archwire was sectioned distally to the bilateral upper 2nd premolar. The posterior segments were removed and continuous intermaxillary elastics (*Giraffe, Chipmunk, Kangaroo*) were prescribed to settle the occlusion (Fig. 31).

After 27 months of active treatment, all appliances were removed.

Results Achieved

Maxilla:

- A - P: *Retracted*
- Vertical: *Maintained*
- Transverse: *Maintained*

Mandible:

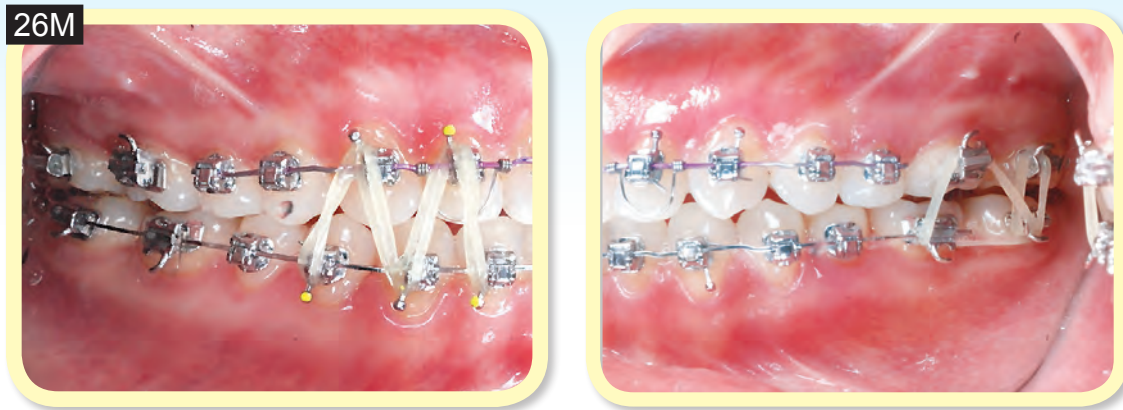
- A - P: *Maintained*
- Vertical: *Maintained*
- Transverse: *Maintained*

Maxillary Dentition:

- A - P: *Incisors retracted, slight retraction of the molars*
- Vertical: *Incisors extruded*
- Transverse:
 - Inter-molar Width: *Increased*
 - Inter-canine Width: *Maintained*

Mandibular Dentition:

- A - P: *Incisors retracted*
- Vertical: *Molars and incisors extruded*



■ Fig. 31:

The archwire was sectioned distally to the upper 2nd premolar on both sides. The posterior segments were removed. Continuous intermaxillary elastics were prescribed to settle the occlusion.

- Transverse:

Inter-molar Width: *Increased*

Inter-canine Width: *Decreased*

Facial Esthetics:

- Upper and lower lips were retracted, consistent with an optimal facial form.

Retention

An anterior mandibular fixed retainer was bonded on all teeth from canine to canine. Upper and lower clear overlay retainers were delivered. The patient was instructed to wear them full time for the first 6 months and nights only thereafter. The patient was instructed on home care and maintenance of the retainers as well as muscle exercises.

Final Evaluation of Treatment

The ABO Cast-Radiograph Evaluation score was 20 points. There are major discrepancies in two categories: alignment/rotation (4 points) and occlusal contacts (8 points).

Alignment and restorative recontouring of the upper anterior incisors, and closure of lower spaces helped to resolve the patient’s chief complaints. The excessive spaces of the lower dentition were eliminated, but long-term retention will be necessary to prevent relapse.

Overall, there was significant improvement in both dental esthetics and occlusion. The profile was treated to an appropriate result with no esthetic problems.

Discussion

Anterior open bite has a multifactorial etiology comprising of genetically inherited skeletal pattern, soft tissue posture and inter-incisal habits, such as digit-sucking. To formulate an appropriate treatment plan, an accurate diagnosis is essential. Developmental open bites may resolve completely during the transition from mixed to permanent dentition, if the etiology is corrected, i. e. digit-

sucking habit and/or inter-incisal lip posture. More severe open bites, sometimes extending back to the terminal molars, rarely resolve spontaneously, so they often require complex orthodontic treatment, involving active molar intrusion or orthognathic surgery. However, major surgery has associated risks such as pain, swelling, bruising, altered nerve sensation which may be manifest as permanent anesthesia. In addition, there are significant costs, as well as the additional risk of general anesthesia.²

Wearing the elastics as instructed, and spontaneous correction of aberrant lip posture, were the keys to correcting the patient's anterior open bite. Using light elastics where applicable early in the treatment for correcting A/P, vertical and transverse problems is an important tool for improving treatment quality and enhancing the efficiency of the appliance system.³ Anterior early elastics with light force are optimal because there is a reduced tendency for excessive distal tipping of the incisors. Since there is no evidence of a contributing habit, the etiology of the anterior openbite is probably interincisal tongue posture. The use of light early elastics provides vertical force and serves as a reminder for the patient to retract the tongue gradually as the incisors extrude. However, it is important for the patient to understand their responsibility for correcting the tongue posture and maintaining. Achieving longterm success depends on correction of the etiology.

Stepovich⁴ concluded that spaces of 10 mm or more can be closed in adults, but retaining the closed spaces was difficult. For the present patient, an

anterior mandibular fixed retainer was bonded on all teeth from canine to canine to prevent the space from reopening.

Orthodontists strive to achieve a good functional occlusion. However, a tooth's position in the arch is determined by a combination of eruptive force, functional contact, and anatomy. Cusps and inclined planes aid in mastication and are guides for achieving optimal occlusal contact. Therefore, controlled settling accomplishes the same natural purpose as when teeth initially erupt.⁵

Anterior segment retraction with miniscrew anchorage is a noncompliant mechanism for improving the facial profile that exceeds the potential for all other approaches such as headgear combined with a transpalatal arch.⁶⁻⁷ Miniscrews have a high success rate of approximately 90% and they provided sufficient anchorage immediately after placement surgery for any orthodontic tooth movement. In addition, miniscrews placed without a mucoperiosteal incision or flap surgery significantly reduce the patient's pain and discomfort after implantation.⁶⁻⁸

It is very important for the orthodontist to educate the patient regarding the correct use of elastics because treatment results are dependent on patient cooperation. Latex elastics fail to maintain a continuous force and are therefore inferior to Niti springs in that regard.⁹

The maxillary and mandibular posterior teeth were retracted with extra-alveolar miniscrew implants

retracted with extra-alveolar miniscrew implants (2 mm in diameter and 12 mm long). En masse movement of the entire dentition after anterior tooth alignment reduced the treatment time and maximized the overall efficiency of the correction. The miniscrew implants were maintained firmly throughout the treatment and were able to provide excellent anchorage for retraction of the entire dentition.

The Pink & White esthetic score worksheet list below provides a broad array of clinical parameters for evaluation of patients with esthetics concerns.¹⁰

Conclusion

Overall, extra-alveolar miniscrews outperform all other forms of traditional mechanics for treating patients with severe malocclusions. Wearing the elastics as instructed was the key to correcting the patient’s anterior open bite. The discrepancies in occlusal contacts could have been improved by using more up and down elastics, but the additional mechanics would have increased treatment time.

Muscle exercises (*myofunctional therapy*) played an important role in the open bite correction. The dental protrusion was corrected with extra-alveolar miniscrew anchorage to retract the entire dentition. The long-term stability for this corrected malocclusion may be challenging, so the patient will be closely monitored with respect to soft tissue posture and recurrence of the open bite.

CEPHALOMETRIC				
SKELETAL ANALYSIS				
	PRE-Tx	Progress	POST-Tx	DIFF.
SNA°	79°	79°	78°	1°
SNB°	77°	77°	76°	1°
ANB°	2°	2°	2°	0°
SN-MP°	36°	36°	36.5°	0.5°
FMA°	29°	29°	29.5°	0.5°
DENTAL ANALYSIS				
U1 TO NA mm	6 mm	6 mm	4.5 mm	1.5 mm
U1 TO SN°	106°	108°	104°	4°
L1 TO NB mm	10 mm	8 mm	6.5 mm	3.5 mm
L1 TO MP°	106°	94°	90°	16°
FACIAL ANALYSIS				
E-LINE UL	-1 mm	-1.5 mm	-2.5 mm	1.5 mm
E-LINE LL	3 mm	1 mm	-0.5 mm	3.5 mm

■ Table 1: Cephalometric summary

In conclusion, this case demonstrates that open bite correction can be achieved with simple mechanics and muscle exercises to control the etiology. This difficult malocclusion (*DI=34*) was treated to an acceptable result (*CRE=20*). The patient and the clinician were pleased with the treatment result.

Acknowledgment

Thanks to Mr. Paul Head for proofreading this article.

References

1. Sandler PJ, Madahar AK, Murray A. Anterior open bite: aetiology and management. *Dent Update* 2011;38(8):522-524, 527-528, 531-532.
2. Kozlowski J. Honing Damon System Mechanics for the Ultimate in Efficiency and Excellence. *Clin Impressions* 2008;16:23-28.
3. Stepovitch Ml. A clinical study on closing edentulous spaces in the mandible. *Angle Ortho* 1979;49:227-33.
4. Steffen JM, Haltom FT. The five-cent tooth positioner. *J Clin Orthod* 1987;21:528-529.
5. Kuroda S, Yamada K, Deguchi T, Kyung HM, and Teruko TY. Class II malocclusion treated with miniscrew anchorage: Comparison with traditional orthodontic mechanics outcomes. *Am J Orthod Dentofacial Orthop* 2009;135:302-9.
6. Kuroda S, Yamada K, Deguchi T, Kyung HM, Teruko TY. Clinical use of miniscrew implants as orthodontic anchorage: Success rates and postoperative discomfort . *Am J Orthod Dentofacial Orthop* 2007;131:9-15.
7. Singh VP, et al. Elastics in orthodontics. *Health Renaissance* 2012;10(1):49-56.
8. Park HS, et al. Nonextraction Treatment with Microscrew Implants. *Angle Orthod* 2004;74:539-549.
9. Su B. IBOI Pink & White Esthetic Score. *Int J Orthod Implantol* 2012;28:80-85.
10. Chang CH. Advanced Damon Course No. 8: Excellence in Finishing, Beethoven Podcast Encyclopedia in Orthodontics [podcast]. Hsinchu: Newton's A Ltd; 2011.
11. Chang CH. Advanced Damon Course No. 4,5 : DI & CRE Workshop (1)(2), Beethoven Podcast Encyclopedia in Orthodontics [podcast]. Hsinchu: Newton's A Ltd; 2011.
12. Pitts T. The Secrets of Excellent Finishing. *News & Trends in Orthod* 2009 Apr;14:6-23.
13. Chang CH. Basic Damon Course No.5: Finish Bending, Beethoven Podcast Encyclopedia in Orthodontics [podcast]. Hsinchu: Newton's A Ltd; 2011.



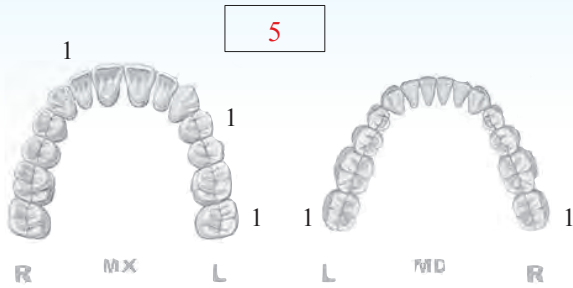
Cast-Radiograph Evaluation

Interim-Treatment Progress

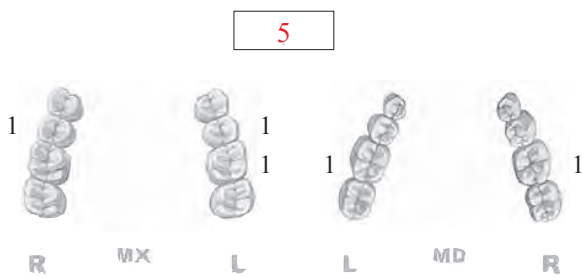
Case # 1 Patient

Total Score: **40**

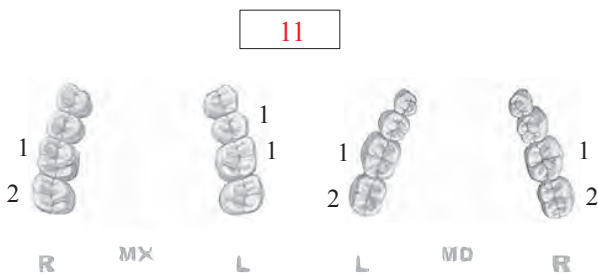
Alignment/Rotations



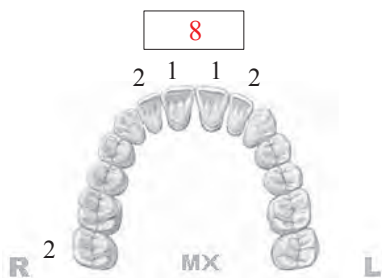Marginal Ridges



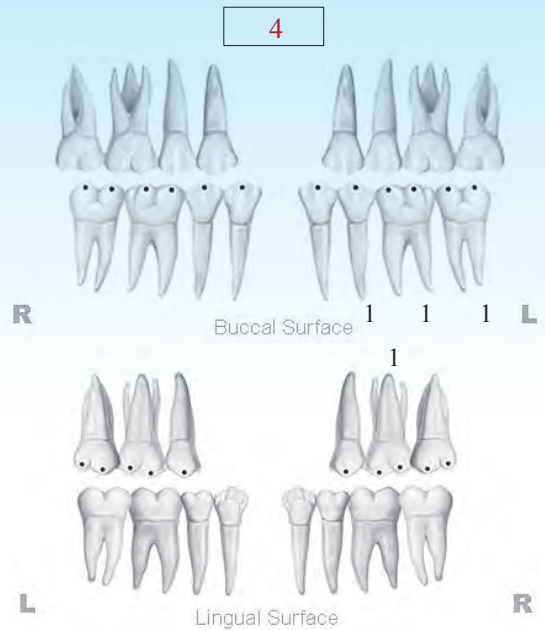
Buccolingual Inclination



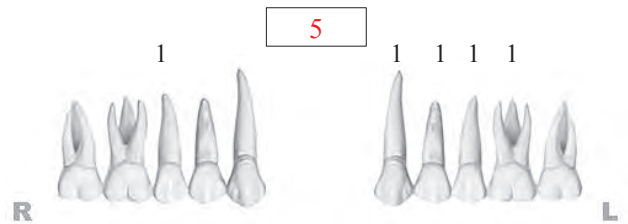
Overjet



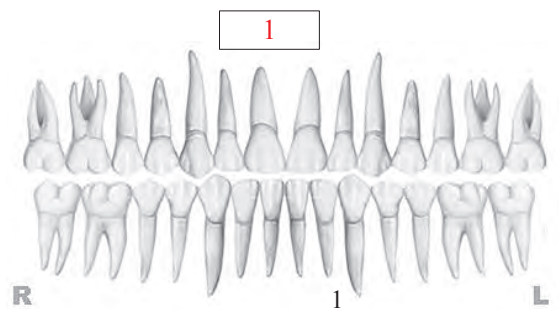
Occlusal Contacts



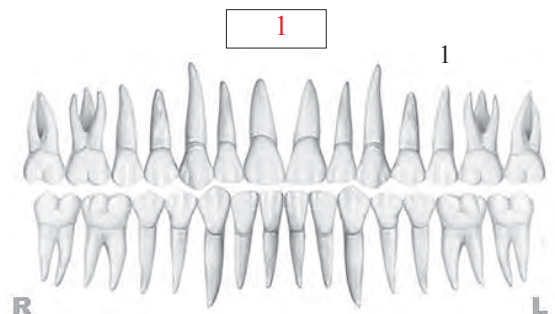
Occlusal Relationships



Interproximal Contacts



Root Angulation



INSTRUCTIONS: Place score beside each deficient tooth and enter total score for each parameter in the white box. Mark extracted teeth with "X". Second molars should be in occlusion.

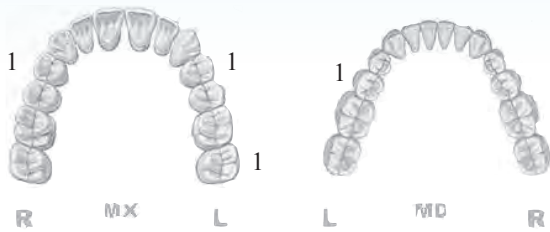
Cast-Radiograph Evaluation

Case # 1 Patient

Total Score: **20**

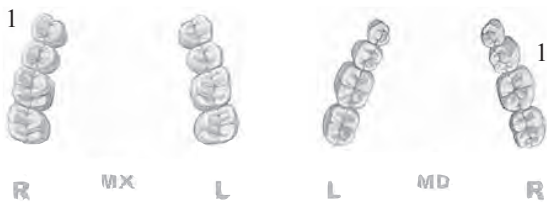
Alignment/Rotations

4



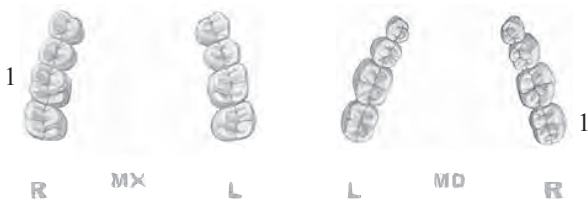
Marginal Ridges

2



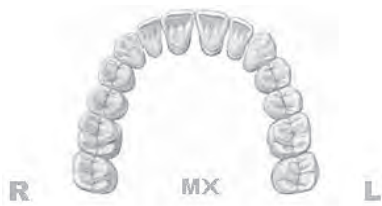Buccolingual Inclination

2



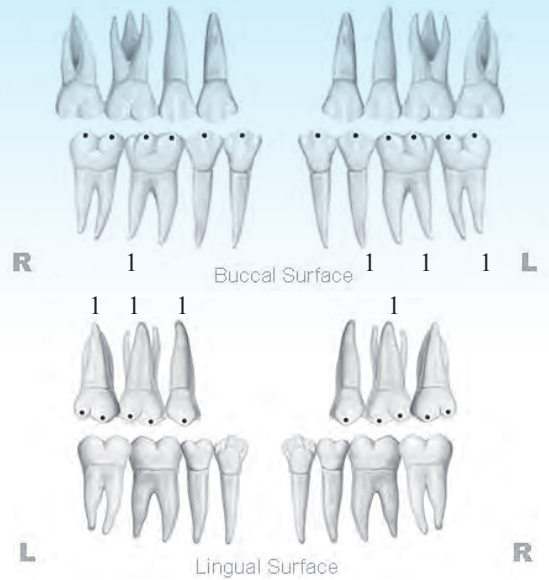
Overjet

0



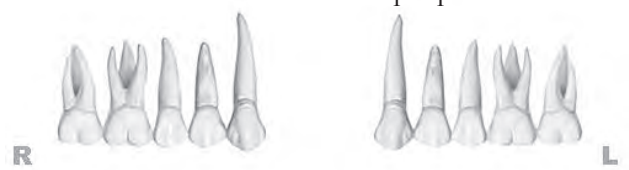Occlusal Contacts

8



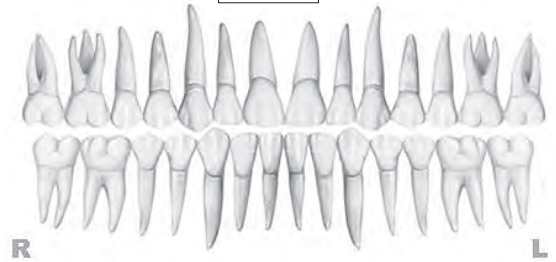
Occlusal Relationships

2



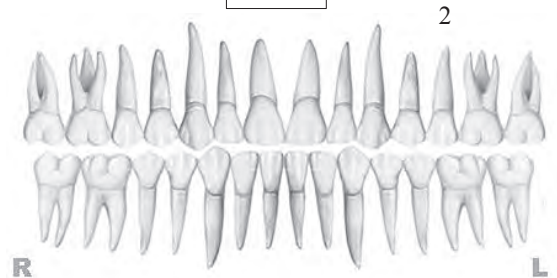
Interproximal Contacts

0



Root Angulation

2

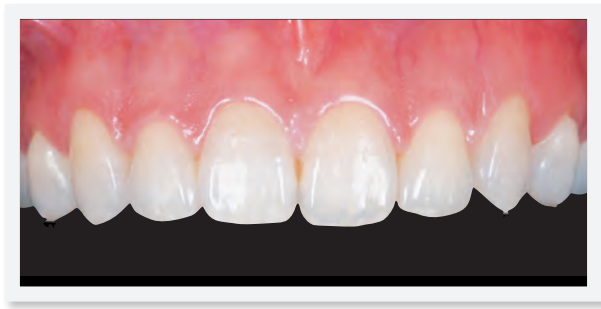
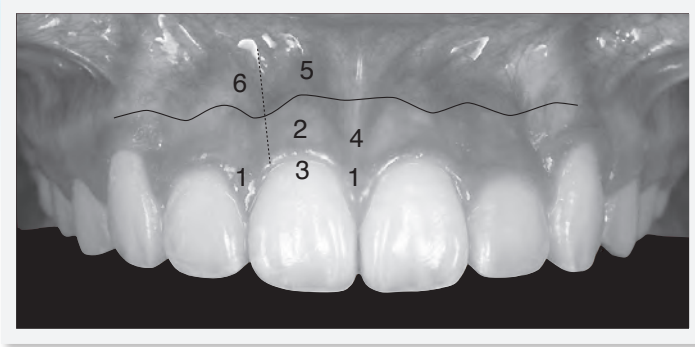


INSTRUCTIONS: Place score beside each deficient tooth and enter total score for each parameter in the white box. Mark extracted teeth with "X". Second molars should be in occlusion.

IBOI Pink & White Esthetic Score (Before Surgical Crown Lengthening)

Total Score: = 2

1. Pink Esthetic Score

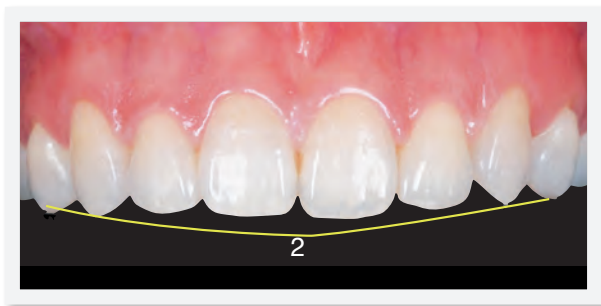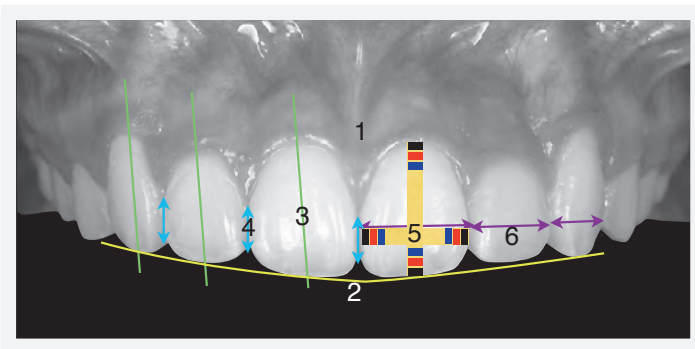


1. M & D Papillae	0	1	2
2. Keratinized Gingiva	0	1	2
3. Curvature of Gingival Margin	0	1	2
4. Level of Gingival Margin	0	1	2
5. Root Convexity (Torque)	0	1	2
6. Scar Formation	0	1	2

Total = 0

1. M & D Papilla	0	1	2
2. Keratinized Gingiva	0	1	2
3. Curvature of Gingival Margin	0	1	2
4. Level of Gingival Margin	0	1	2
5. Root Convexity (Torque)	0	1	2
6. Scar Formation	0	1	2

2. White Esthetic Score (for Micro-esthetics)



1. Midline	0	1	2
2. Incisor Curve	0	1	2
3. Axial Inclination (5°, 8°, 10°)	0	1	2
4. Contact Area (50%, 40%, 30%)	0	1	2
5. Tooth Proportion (1:0.8)	0	1	2
6. Tooth to Tooth Proportion	0	1	2

Total = 2

1. Midline	0	1	2
2. Incisor Curve	0	1	2
3. Axial Inclination (5°, 8°, 10°)	0	1	2
4. Contact Area (50%, 40%, 30%)	0	1	2
5. Tooth Proportion (1:0.8)	0	1	2
6. Tooth to Tooth Proportion	0	1	2

Animation & Illustration Workshop
Advanced Keynote Workshop

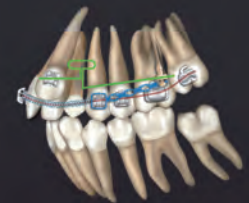2016 10/22-24 (Sat-Mon) 09:00-17:00



Effective dental presentation in today's digital world requires not only clear clinical photos but also diagrams and animation to engage the audience. Moreover, these visual tools are excellent aids to make your presentation unique and memorable. In this workshop Dr. Rungsi will share his dental illustration experiences and demonstrate step by step how to create an illustration from an initial sketch to a finished piece. Active participation and completion of workshop assignments are required for workshop participants.

Topics:

- 1 Design illustration in Keynote.
- 2 Showcase your own drawing with stunning animation in Keynote.
- 3 Animation composition.



Lecturer:
Dr. Rungsi Thavarungkul,
Thailand

Early Bird

by **2016/08/05**

Newton's A course@newtonsa.com.tw

Requirements: Mac computer with OSX 10.11.X; Keynote 6.X (the latest)



2016 Keynote Workshop

高效簡報學習法

K123

看過太多充滿複雜文字和圖表的幻燈片，聽過就忘了的演講嗎？Keynote系列課程教你如何利用Mac內建軟體Keynote，製作出令人目眩神迷、印象深刻的電腦簡報。透過小班教學，貼身指導，務必讓你在課程中輕鬆掌握Keynote的簡報技巧。

K1

簡報聖經

2016.07.14



Keynote 101

K2

DR. KOKICH

2016.08.04

10大演講秘訣

K3

STEVE JOBS

2016.09.15

令人目眩神迷的演講技巧

K456

ADVANCED KEYNOTE

Speaker: Dr. Rungsi

2016.10.22 - 24

K456



講師：
Dr. Rungsi Thavarungkul

數位化潮流下的牙科簡報，不僅需要清晰的臨床照片，也需要精確的圖表和流暢的動畫來吸引觀眾，而優秀的視覺化工具更使您的演講獨樹一格且令人難忘。Keynote 456課程中，**Dr. Rungsi**將分享他利用Keynote軟體繪製精美牙科插圖的經驗，並一步步教會您如何從構想和草圖創建出令人驚艷的成果。跟隨簡報美學大師的腳步，您也可以秀出創意、站上世界舞台！

報名2016課程即贈送2015及2016課程視訊。

- 名額有限，以繳費順序為依據。
- 舊生享特惠優惠價，限額6名。
- 若取消報名，7/22前退款將扣除10%行政手續費，7/23後扣除30%行政手續費。

Skeletal Class III Malocclusion with Canine Transposition and Facial Asymmetry

History and Etiology

A 13-year-6-month-old male presented with a chief complaint of prognathic mandible (Figs. 1-3). There was no other contributory medical or dental history. The etiology was hereditary tendency for prognathic mandible with eruption of the maxillary central incisors into crossbite, which resulted in a functional shift of 4mm anterior and 3mm to the left. Clinical exam indicated transposition of the permanent right maxillary canine and premolar, general crowding and anterior crossbite (Fig. 2). Extraction of all four first premolars was proposed to correct the canine transposition and create space for retraction of lower anterior dentition. The patient was treated to an acceptable result as documented in Figs. 4-9.

Diagnosis

In centric occlusion, a severe dental asymmetry was noted: Class III molar on the right side, Class I molar on the left side, and an intermaxillary midline discrepancy of ~7mm. There was a concave profile and asymmetrical facial form with the mandible deviated to the left. Relative to the facial midline, the upper dental midline was 2 mm to the right, while the lower dental midline was 5 mm to the left. The

anterior crossbite extended from the right lateral incisor to the left 2nd premolar. Cephalometric and panoramic radiographs (Fig. 7), as well as anterior segment photographs (Fig. 10) document the complexity of the malocclusion.

Skeletal:

- Skeletal Class III ($SNA\ 70^\circ$, $SNB\ 75^\circ$, $ANB\ -5^\circ$)
- Mandibular plane angle ($SN-MP\ 37^\circ$, $FMA\ 29^\circ$)

Dental:

- Functional shift 4mm anteriorly and 3mm to the left
- Class III on the right and Class I molar relationship on the left.
- Maximum overbite 3 mm
- Maximum overjet -3 mm
- Severe crowding of ~10 mm in the upper arch and 7 mm in the lower arch
- Right maxillary canine blocked-out and transposed with the adjacent 1st premolar

The ABO Discrepancy Index (DI) was 46 points as shown in the subsequent worksheet.

Dr. Wei Ming-Wei,
Resident, Beethoven Orthodontic Course (Left)

Dr. Chris Chang,
Founder, Beethoven Orthodontic Center
Publisher, International Journal of Orthodontics & Implantology (middle)

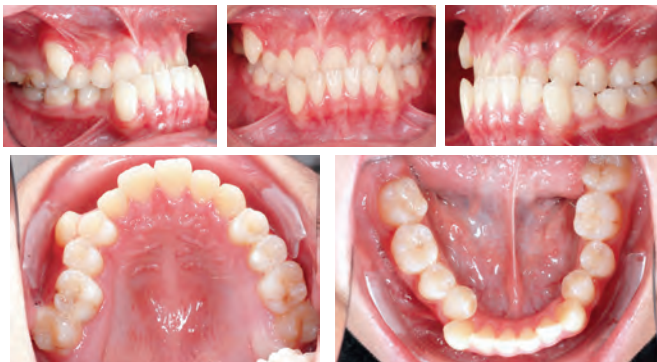W. Eugene Roberts,
Consultant, International Journal of Orthodontics & Implantology (right)



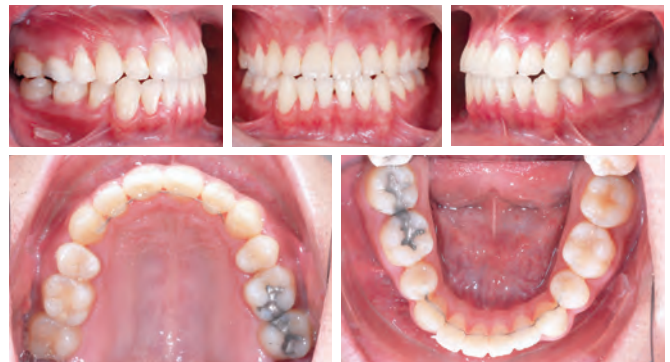■ Fig. 1: Pre-treatment facial photographs



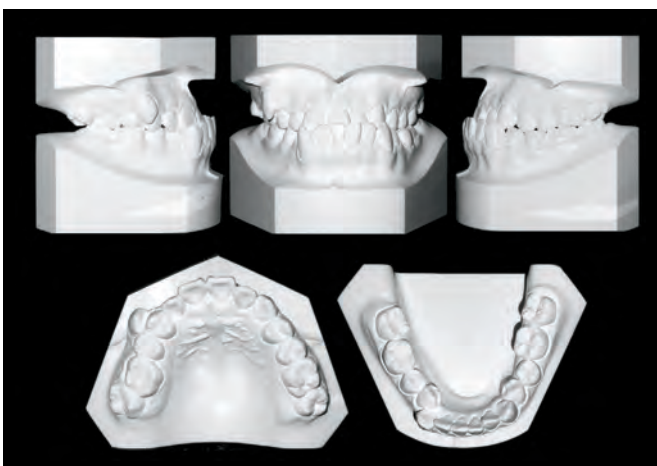■ Fig. 4: Post-treatment facial photographs



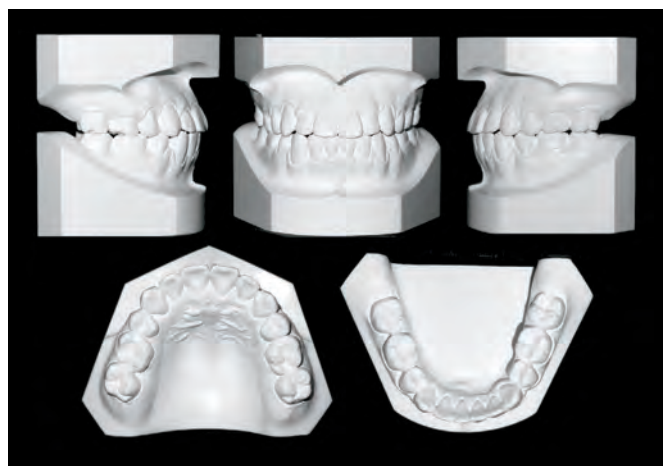■ Fig. 2: Pre-treatment intraoral photographs



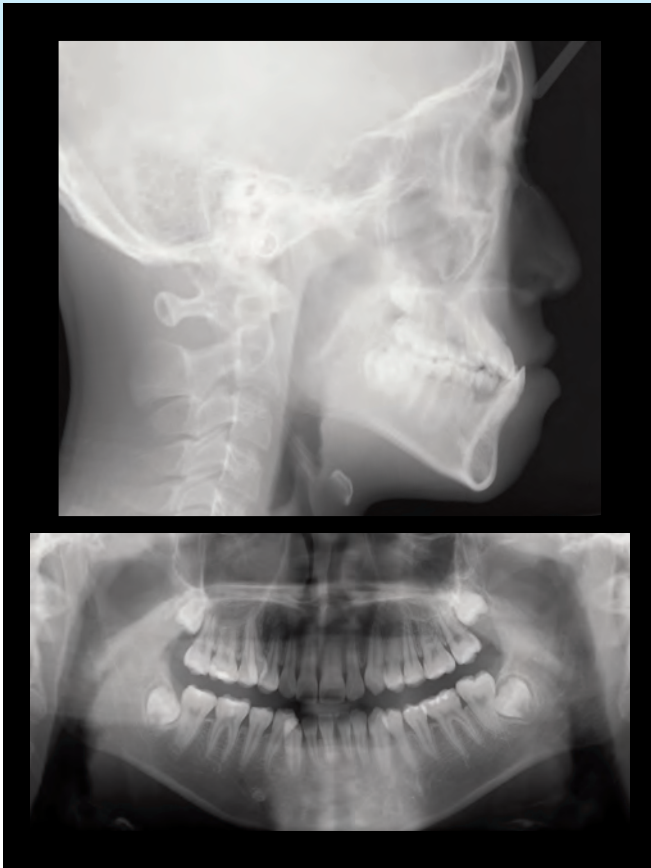
■ Fig. 5: Post-treatment intraoral photographs



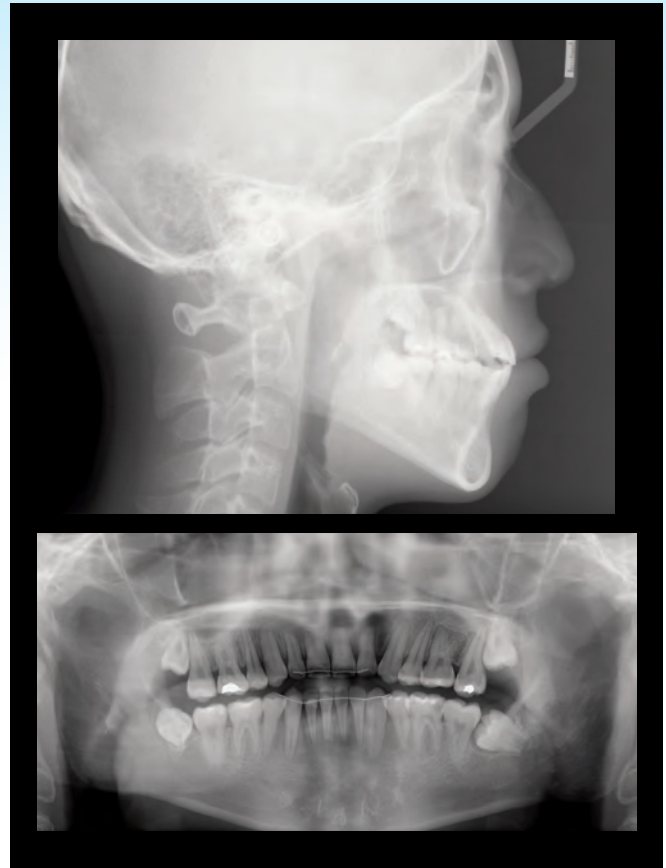
■ Fig. 3: Pre-treatment study models (casts)



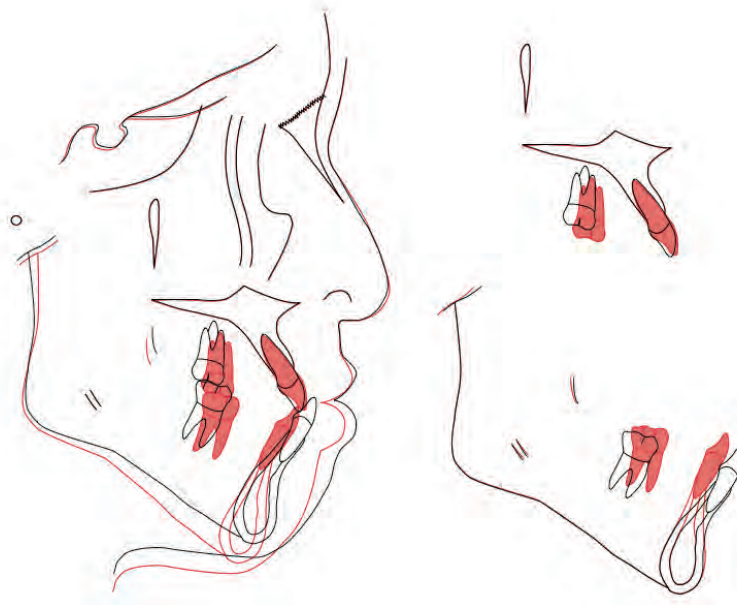
■ Fig. 6:
Post-treatment study models (casts) reveal modest expansion in both arches.



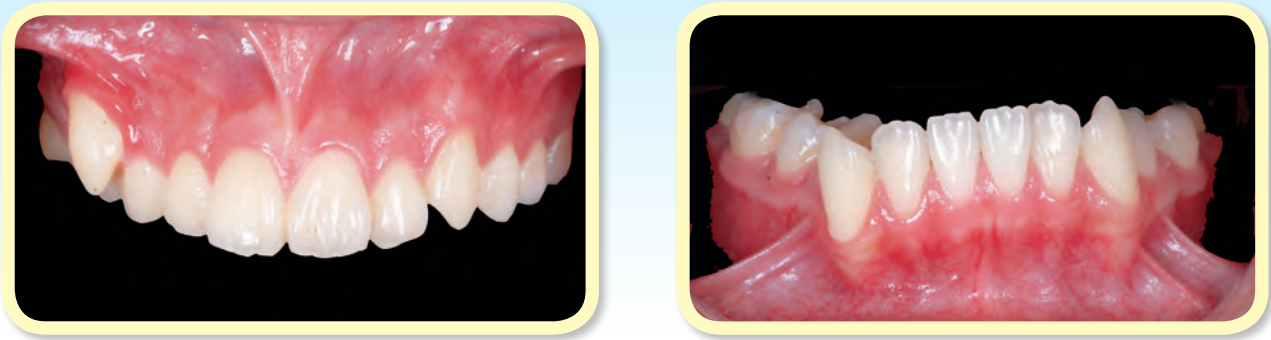■ **Fig. 7:**
Pre-treatment panoramic and cephalometric radiographs



■ **Fig. 8:**
Post-treatment panoramic and cephalometric radiographs



■ **Fig. 9:**
Superimposed tracings. Reasonable mesial drift of molars and retraction of incisors were found in this extraction case. Overjet correction due to maxillary incisors uprighting. Well controlled torque of the lower incisors were noticed.



■ Fig. 10: Close-up views of the right maxillary canine-premolar transposition and canting of the lower occlusal plane.

Specific Objectives of Treatment

Maxilla (all three planes):

- A - P: *Maintain*
- Vertical: *Maintain*
- Transverse: *Expand to coordinate with lower arch*

Mandible (all three planes):

- A - P: *Maintain*
- Vertical: *Posterior rotation to open the vertical dimension of occlusion*
- Transverse: *Maintain*

Maxillary Dentition:

- A - P: *Maintain*
- Vertical: *Extrusion of molars*
- Inter-molar Width: *Maintain*

Mandibular Dentition:

- A - P: *Retraction of anterior teeth*
- Vertical: *Extrusion with increased vertical dimension of occlusion*
- Inter-molar / Inter-canine Width: *Maintain*

Facial Esthetics:

- Posterior movement of chin point and lower lip

Treatment Plan

All four 1st premolars were extracted to create space to align the transposed right maxillary canine, as well as to retract the protruded lower anterior segment, to correct the crossbite (Fig. 11). Anterior bite turbos were bonded on the lingual surfaces of the mandibular central incisors and the left lateral incisor to open the bite for crossbite correction. Early light short Class III elastics were used in the initial stage of treatment to assist crossbite correction (Fig. 12).

After the crossbite correction and alignment of the maxillary anterior segment, a torquing auxiliary was indicated for the maxillary right canine. A mandibular pre-torqued rectangular NiTi wire, with vertical elastics were used to flatten and align the arch (Fig. 13). A mandibular anterior torquing auxiliary and asymmetric intermaxillary elastics (*Class III right, Class II left*) were applied (Figs. 14-15). Vertical elastics were used to produce the final occlusion (Fig. 16). The fixed appliances were removed and the

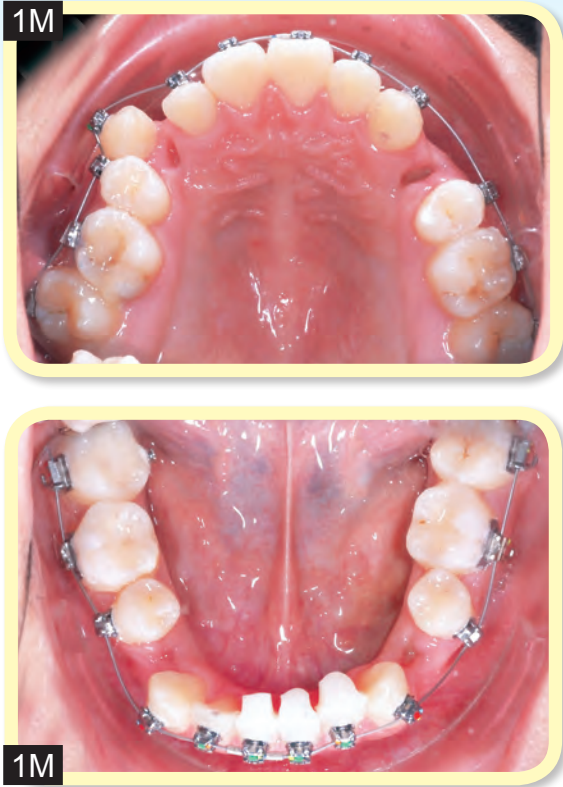


Fig. 11: Premolars were extracted in the initial treatment. Anterior bite turbos were boned on the lower arch for bite opening.

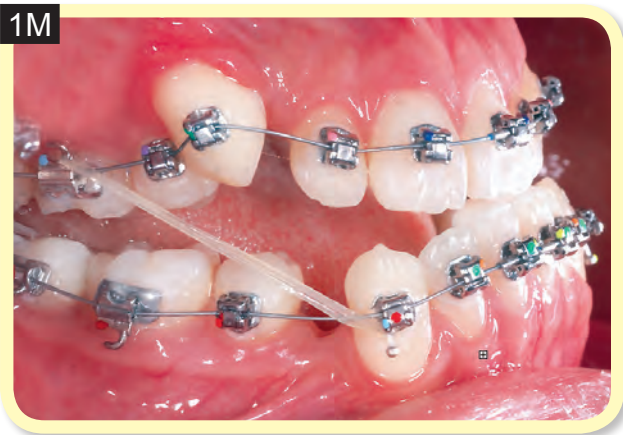

Fig. 12: Class III elastic provided horizontal and vertical forces to improve canting in the lower arch and to facilitate early correction of Class III relation.

CEPHALOMETRIC			
SKELETAL ANALYSIS			
	PRE-Tx	POST-Tx	DIFF.
SNA°	70°	70°	0°
SNB°	75°	73.5°	1.5°
ANB°	-5°	-3.5°	1.5°
SN-MP°	37°	42°	5°
FMA°	29°	34°	5°
DENTAL ANALYSIS			
U1 TO NAm	9 mm	11 mm	2 mm
U1 TO SN°	116°	120°	4°
L1 TO NBmm	6 mm	4.5 mm	1.5 mm
L1 TO MP°	89°	87.5°	1.5°
FACIAL ANALYSIS			
E-LINE UL	-2 mm	-1 mm	1 mm
E-LINE LL	2.5 mm	2 mm	0.5 mm

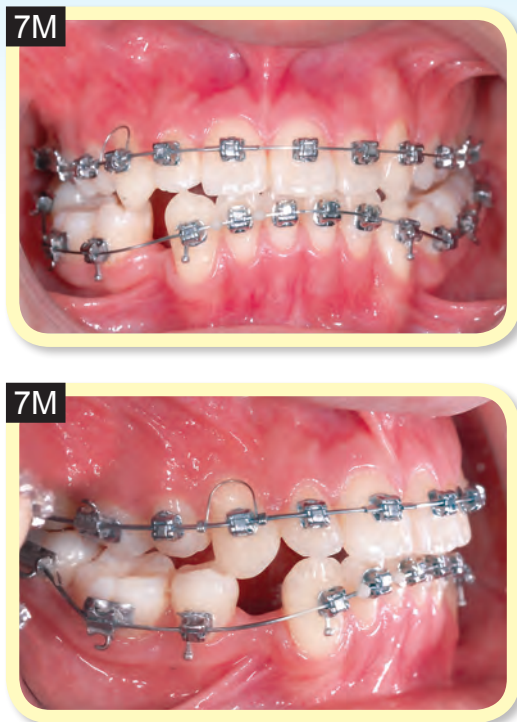■ Table 1: Cephalometric summary

corrected dentition was retained with fixed anterior retainers (Mx 3-3, Md 5-5) that were bonded to each tooth in both arches (Fig. 5).

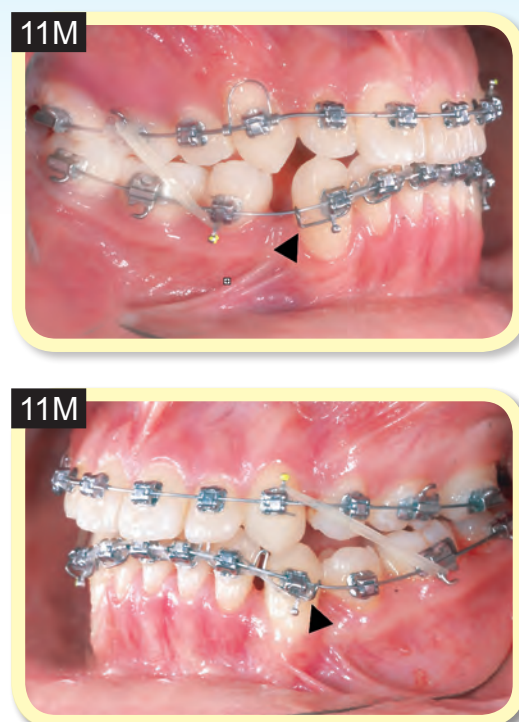
Appliances and Treatment Progress

A .022" Damon Q® bracket system (Ormco) was used. The maxillary arch was bonded with standard torque brackets, and low torque brackets reversed were selected for the lower anterior teeth to counter the force of Class III elastics (Fig. 12).

After seven months of active treatment, the right maxillary canine was aligned into the arch. Positive overjet was achieved and the canting of the lower occlusal-plane (Fig. 10) was improved (Fig. 13). Anterior



■ **Fig. 13:**
7th month of treatment. leveling of right maxillary canine and the lower-occlusal plane canting were improved. Positive overjet was also achieved.

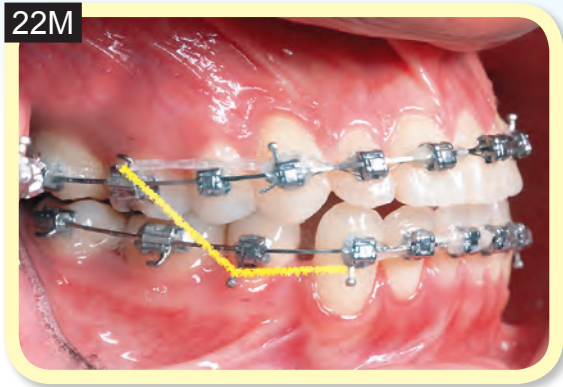


■ **Fig. 14:**
Asymmetrical elastics and a pre-torque NiTi wire were introduced in the 11th month of treatment. (Arrow: lower 3-3 ART)

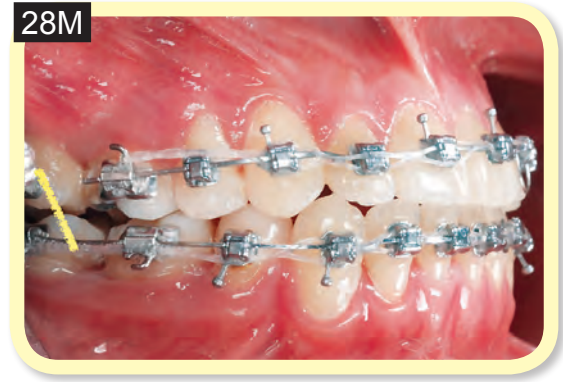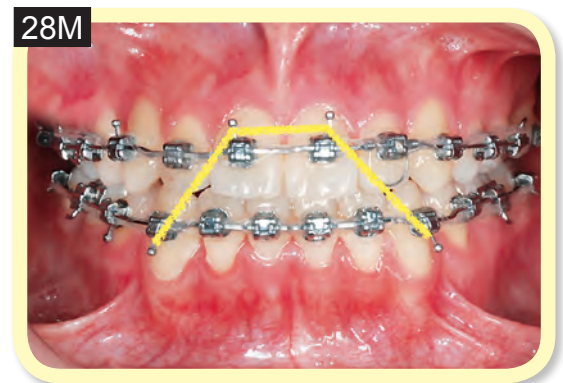
root torque springs (ART) were placed on both the lower anterior teeth and right maxillary canine for early torque control (Figs. 13-14). After eleven months of active treatment, maxillary space was closed, but the excessive Curve of Spee of the lower arch and the midline deviation were still evident. Clockwise rotation of the mandible corrected the severe Class III relationship on the right side to Class I, but the slight Class III on the left evolved into a Class II molar relationship. A .016x.025" pre-torqued NiTi wire with asymmetrical elastics were used to flatten the Curve of Spee and correct the molar relationship in this stage of treatment (Fig. 14).

From the 12-20 months of treatment, a Class III L-shape elastic from the right mandibular canine, and coursing under the 2nd premolar bracket to the right maxillary 1st molar was used for space closure and settling of the posterior occlusion (Fig. 15). Seven months were required to correct the asymmetric molar relationships.

In the last two months of treatment, elastics were applied to settle the occlusion: upside down U shape elastics in the anterior and a vertical elastics in the second molar area bilaterally were applied to settle the final occlusion (Fig. 16). After 29 months of active treatment, all appliances were removed.



■ **Fig. 15:**
A L-shape Class III vector elastic was utilized for space closure, settling posterior bite and better interdigitation.



■ **Fig. 16:**
Elastics used at the end of treatment to settle occlusion.

Results Achieved

Maxilla (all three planes):

- A - P: *Maintained*
- Vertical: *Maintained*
- Transverse: *Maintained*

Mandible (all three planes):

- A - P: *Retracted*
- Vertical: *Mild clockwise rotation to increase the vertical dimension*
- Transverse: *Maintained*

Maxillary Dentition:

- A - P: *Flaring of the incisors*
- Vertical: *Molar extrusion and mesial movement*
- Inter-molar / Inter-canine Width: *Maintained*

Mandibular Dentition:

- A - P: *Flaring of the incisors*
- Vertical: *Molar extrusion and mesial movement*
- Inter-molar / Inter-canine Width: *Maintained*

Facial Esthetics:

- *Retraction of the lower lip and chin point*

Retention

Fixed retainers were bonded on all maxillary incisors and from second premolar to second premolar in the mandibular arch. An upper clear overlay retainer was delivered. The patient was instructed

to wear it full time for the first 6 months and nights only thereafter. Instructions in home care and maintenance of retainers were provided.

Final Evaluation of Treatment

The ABO Cast-Radiograph Evaluation score was 22 points. The major discrepancies were in the lingual occlusal contacts and alignment/rotation. Deviation of the lower dental midline was decreased to 1 mm to the left of the maxillary midline. The transposed canine was well aligned, and the gingiva texture was healthy (*Fig. 5*).

Collectively, molar extrusion and mandible clockwise rotation improved the facial profile. The Class III molar relation was corrected. Overall, this Class III asymmetric malocclusion was treated to an appropriate facial and dental result. The roots of the maxillary incisors were out of focus on the post-treatment panoramic radiograph, but it appears that there was significant root resorption of both maxillary central incisors and the left lateral incisor. The latter may have been due to the occlusal stress of the premature contact with the anterior bite turbos during crossbite correction.

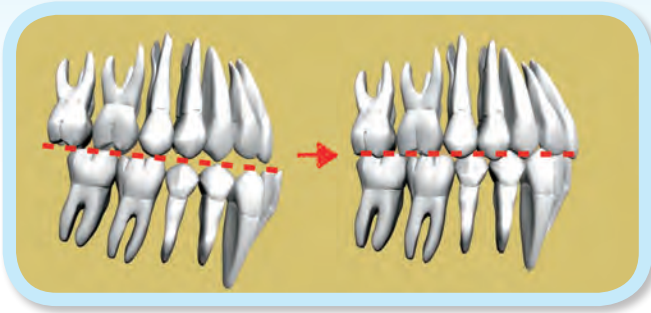
Discussion

Surgical correction is routinely indicated for asymmetrical Class III malocclusions because of a questionable prognosis for orthodontics only management of large skeletal discrepancies and

unsatisfactory esthetic outcomes.¹ However, if there is a substantial functional shift, the asymmetrical profile and mandibular shift are accentuated.² Increasing lower facial height and correcting the functional shift are more readily achieved with non-surgical treatment. Carefully considering the pros and cons of conventional and surgical treatment are important elements of diagnosis and treatment planning.

Growth potential warrants additional consideration if a patient exhibits signs of mandibular overgrowth. In the present case, although the mandibular prognathism was noted at the beginning of treatment, little or no further increase in mandibular length was noted during treatment. Baccetti³ provided an assessment method for determining skeletal maturation by evaluating the cervical vertebrae in routine lateral cephalograms. For the present case, skeletal maturation exceeded CS 5, indicating a mature skeletal pattern, suitable for treatment as an adult. There were additional indicators favoring non-surgical orthodontic options: 1) the chief complaint was mandibular prognathism without consideration of facial asymmetry, 2) reduced lower facial height, 3) obtuse nasolabial angle, 4) negative overjet less than 4mm,⁴ and 5) a moderate Class III molar relationship with a discrepancy that was less than a molar's width.⁵

A conservative treatment approach was selected which consisted of a camouflage dental correction (*Fig. 17*) with counter-clockwise rotation of occlusal

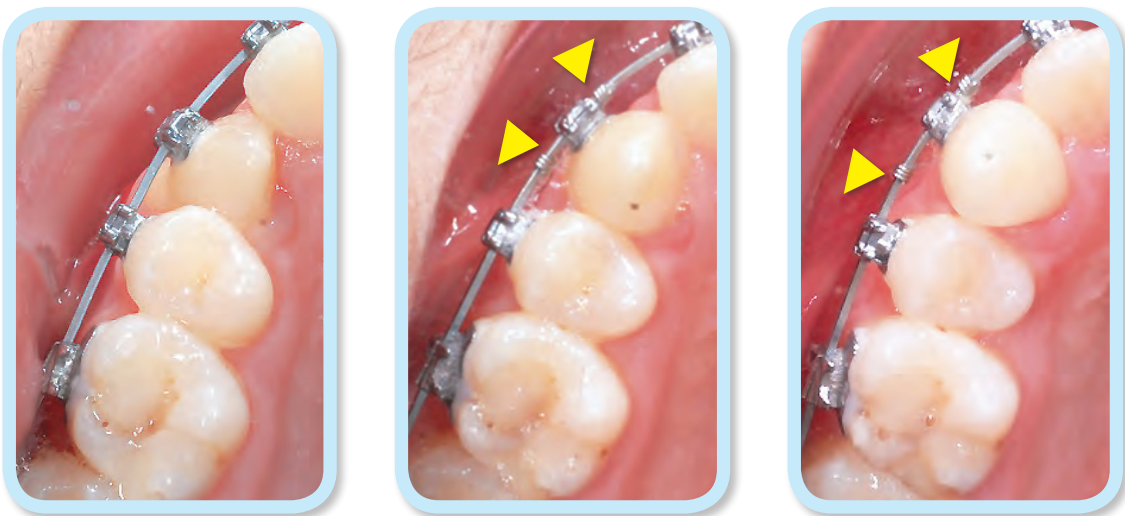


■ **Fig. 17:**
Camouflage dental correction with counter-clockwise rotation of the occlusal plane.

plane. Downward and backward rotation of the chin point, in conjunction with molar extrusion and increased lower facial height, produced a more harmonious lateral facial profile. Predictable dental changes included proclination of the maxillary incisors and retroclination of the mandibular incisors. Torque control was essential in camouflage treatment in order to prevent further periodontal problems. Lost control of anterior teeth might

compromise long-term stability, particularly in extraction cases.⁶ Early usage of ARTs and the pretorqued NiTi wire on the lower arch delivered a continuous light force, as opposed to a heavy interruptive force from a twisted rectangular wire at a later stage in treatment. As the transposed right maxillary canine was moved mesially, an ART spring was used to correct the axial inclination (Fig. 18). Higher torque canine brackets would have been more favorable for the present case (Fig. 12).

Anterior or posterior placement of bite turbos can be used for bite opening. For the present patient, molar extrusion and clockwise rotation of the mandible were part of the treatment plan, so anterior bite turbos were appropriate for this purpose. With bite turbos and early light short elastics (*Class III vector*), the anterior crossbite was corrected within seven months. Short Class III

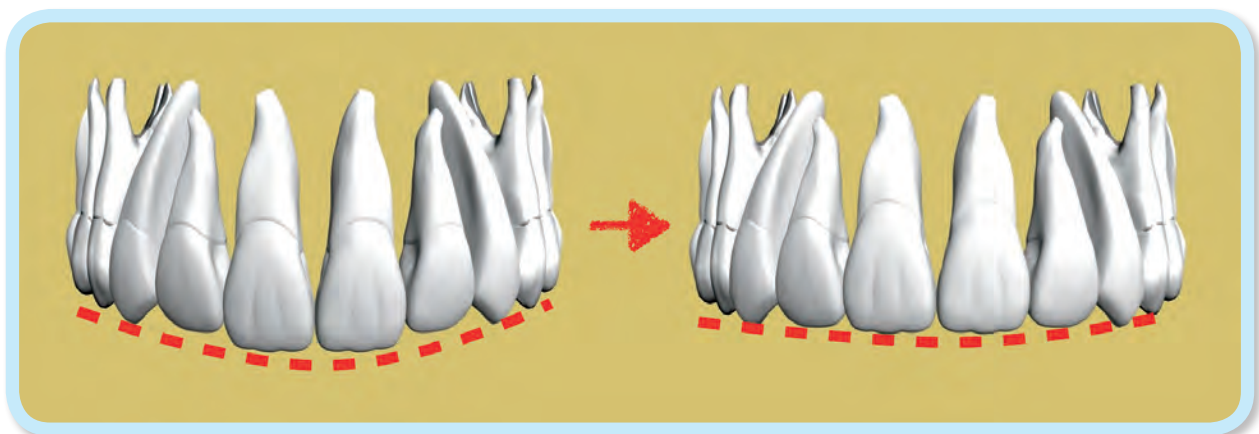


■ **Fig. 18:**
Early torque control in right maxillary canine contributed good torque express in the middle of treatment. (Arrow: root torque spring)

elastics on the right side also provided an extrusion force for the infra-occlusion right mandibular canine and redirected the displaced mandible to return to its normal position. This approach would not be appropriate for patients with a true severe skeletal asymmetry and large discrepancy in ramus height. Carefully monitoring of the treatment response is critical for success. For instance, incisal occlusal stress due to anterior bite turbos may contribute to the root resorption of the maxillary incisors in some patients. A progress radiograph six months into treatment would have been appropriate because the root of the left maxillary central incisor appears to be moderately resorbed prior to treatment (Fig. 7). Fortunately, the panoramic radiograph at the end of treatment showed no significant progression of maxillary incisal root resorption (Fig. 8).

Temporary anchorage devices (TADs), placed lateral to the alveolar processes (*mandibular buccal shelves, infrazygomatic crests*) are a break-through for

treatment of Class III malocclusions.^{5,7} The stationary anchorage of TADs facilitate retraction of the entire lower arch, without proclination (*anterior tipping*) of maxillary incisors⁷ or deterioration of smile arc, two common problems with Class III elastics (Fig. 19).^{5,8} For many Asians, the major contributory factor for Class III malocclusion is mandibular prognathism with normal mid-face development.⁹ TADs provide reliable anchorage for Class III treatment without creating the undesirable effects seen with intermaxillary elastics. For the present patient, the application of TADs was considered, but discarded because of the acceptable upper lip prominence (Fig. 20), and the transposition of the maxillary right canine and first premolar. Nonextraction treatment of the transposition with TAD anchorage would have been very difficult. Since extraction of the maxillary left first premolar was necessary, the most expedient approach was to remove all four first premolars, and treat the patient with conventional mechanics.



■ Fig. 19:

Flattening of smile arc after Class III correction is a common side effect in traditional interarch Class III mechanics.

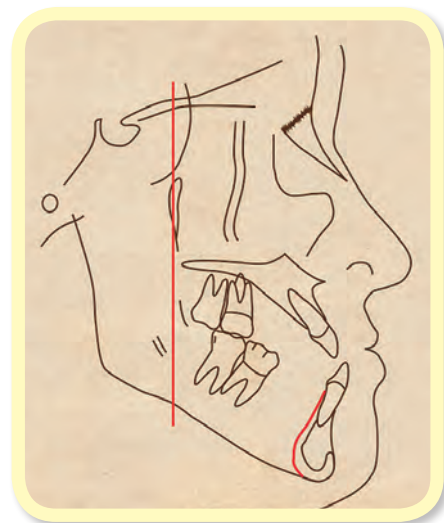
As mentioned previously, smile arc preservation is crucial for an esthetic result with Class III cases.¹⁰ Ackerman reported that 40% of routine orthodontics corrections show a deterioration in smile arc.¹¹ The nature of Class III mechanics include molar extrusion, counter-clockwise rotation of the occlusal plane⁸ (Fig. 17), and torque change in incisors of both arches. These side effects further challenge smile arc preservation during Class III (Fig. 19) treatment. Restrictive usage of Class III elastics, in combination with Class II elastics and TADs in the mandible, can effectively enhance the smile arc.⁷ However, the biomechanical boundary remains definitive, regardless of the treatment methods.¹² As proposed by Kondo,^{13, 14} the anterior limit for incisor retraction is the posterior border of the symphysis, while the PM or ramus line is the posterior limit for arch retraction (Fig. 21).

Asymmetrical correction is complex, and often involves various mechanics, including intra-arch

auxiliaries¹⁵ and multiple loops, for realigning and coordinating the arch.¹⁶ These special mechanics are often associated with undesirable side effects like compromised molar angulation to meet occlusal goals at the end of treatment.¹⁷ Low friction, self-ligating brackets with special elastics configurations simplify this challenge significantly. Although the 4mm midline deviation, that was evident after correction of the functional shift, was not completely corrected for the present patient, but the result was satisfactory. The CRE score was 22, with most of the points deducted for inadequate third order correction of the maxillary posterior segments, which is reflected in the scores for buccolingual inclination (4 points) and lingual cusp contacts (3 points). More buccal root torque in the maxillary buccal segments and additional detailing with wire bending in the finishing stage would have improved the final result.¹⁸



■ Fig. 20:
An acceptable upper lip profile without TADs anchorage.



■ Fig. 21:
Anterior and posterior boundary of the whole arch distalization in the mandible.

Conclusion

Skeletal Class III treatment with camouflage orthodontics presents significant clinical challenges. The treatment is further complicated with Asian patients who present with hereditary etiology and severe crowding. Orthopedic treatment with rapid maxillary expansion, a facemask or a chin cap show varying degrees of success, due to different protocols and case selection.^{19, 20} With the help of self-ligating brackets, bite turbos, and a properly designed force system, clinicians can now deliver relatively efficient extraction treatment that achieves a satisfactory result. However, the progress of treatment should be carefully monitored to control potential complications.

Acknowledgment

Thanks to Ms. Tzu Han Huang for proofreading this article.

References

- Proffit WR, White RP Jr. Who needs surgical-orthodontic treatment? *Int J Adult Orthodon Orthognath Surg* 1990;5(2):81-9.
- Gazit-Rappaport T, Weinreb M, Gazit E. Quantitative evaluation of lip symmetry in functional asymmetry. *Eur J Orthod* 2003;25(5):443-50.
- Baccetti T, Franchi L, McNamara JA Jr. The cervical vertebral maturation (CVM) method for assessment of optimal treatment timing in dentofacial orthopedics. *Sem Orthod* 2005;11:119-129.
- Tseng YC. Treatment of adult Class III malocclusions with orthodontic therapy or orthognathic surgery: receiver operating characteristic analysis. *Am J Orthod Dentofacial Orthop* 2011;139(5):485-93.
- Lin JJ. Treatment of Severe Class III with Buccal Shelf Mini-Screws. *News & Trends in Orthodontics* 2010;18:4-13.
- Zachrisson BU. Important aspects of long-term stability. *J Clin Orthod* 1997;31(9):562-83.
- Huang CC, Chang C, Roberts WE. A Severe Skeletal Class III Open Bite Malocclusion Treated with Non-surgical Approach. *International Journal of Orthodontics & Implantology* 2011;24:28-36.
- Proffit WR, Fields HW, Sarver DM. *Contemporary orthodontics*, 4th ed. St.Louis: Mosby; 2007. p. 591-592.
- Chang HP. Components of Class III malocclusion in Chinese. *Kaohsiung J. Med. Sci* 1985;1:144-155.
- Sarver DM. The importance of incisor positioning in the esthetic smile: the smile arc. *Am J Orthod Dentofacial Orthop* 2001;120(2):98-111.
- Ackerman J, Ackerman MB, Brensinger CM, Landis JR. A morphometric analysis of the posed smile. *Clin Orthod Res* 1998;1:2-11.
- Handelman CS. The anterior alveolus: its importance in limiting orthodontic treatment and its influence on the occurrence of iatrogenic sequelae. *Angle Orthod* 1996;66(2):95-109.
- Kondo E. Nonsurgical nonextraction treatment of skeletal Class III open bite: Its long-term stability. *Am J orthod Dentofacial Orthop* 2000;117:267-287.
- Kondo E. Nonsurgical and nonextraction treatment of a skeletal Class III patient with severe prognathic mandible: long-term stability. *World J Orthod* 2001;2:115-126.
- van Steenberghe E, Nanda R. Biomechanics of orthodontic correction of dental asymmetries. *Am J Orthod Dentofacial Orthop* 1995;107(6):618-24.
- Lee CY, Liow E. Correction of the Mandibular Dental Midline Deviation through Asymmetric Activation of the MEAW Technique. *J. Taiwan Assoc Orthod.* 2009;17(3): 32-28.
- Shroff B, Siegel SM. Treatment of patients with asymmetries using asymmetric mechanics. *Semin Orthod* 1998;4(3):165-79.
- Chang CH. Basic Damon Course No. 5: Finish Bending., Podcast Encyclopedia in Orthodontics. Hsinchu: Newton's A Ltd; 2011.
- Toffol LD. Orthopedic treatment outcomes in Class III malocclusion. A systematic review. *Angle Orthod* 2008;78(3):561-73.
- Sugawara J, Asano T. Long-term effects of chin cap therapy on skeletal profile in mandibular prognathism. *Am J Orthod Dentofacial Orthop* 1990 Aug;98(2):127-33.



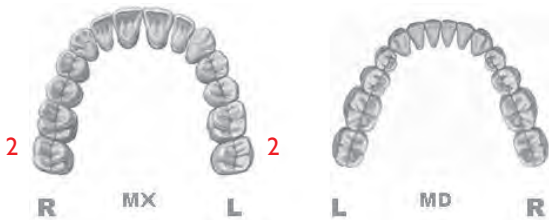
Cast-Radiograph Evaluation

Total CRE Score

22

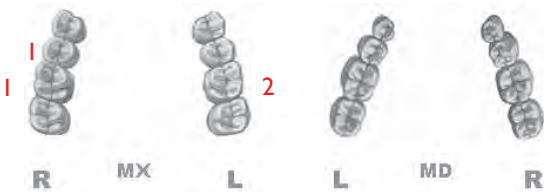
Alignment/Rotations

4



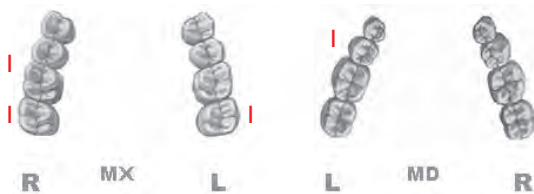
Marginal Ridges

4



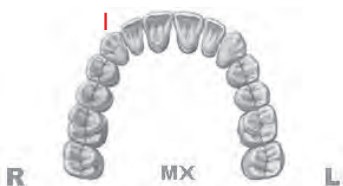Buccolingual Inclination

4



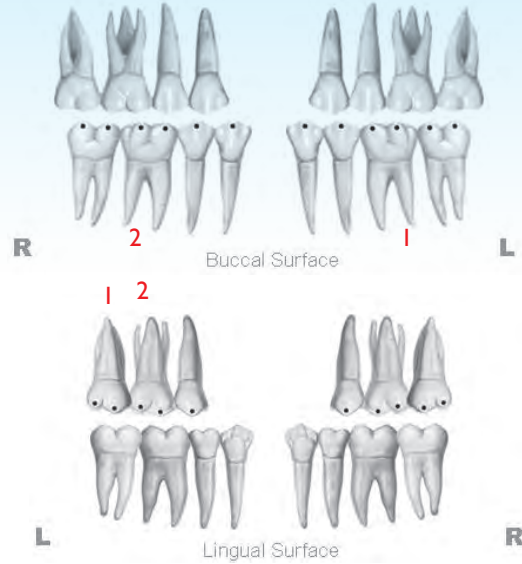
Overjet

1



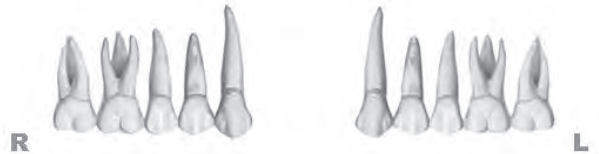Occlusal Contacts

6



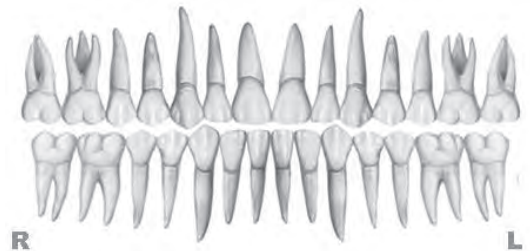
Occlusal Relationships

0



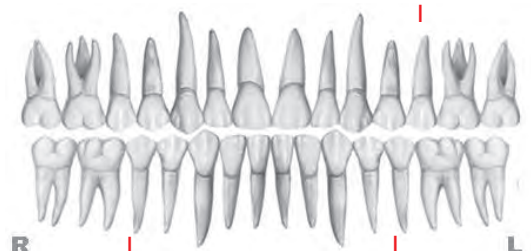
Interproximal Contacts

0



Root Angulation

3

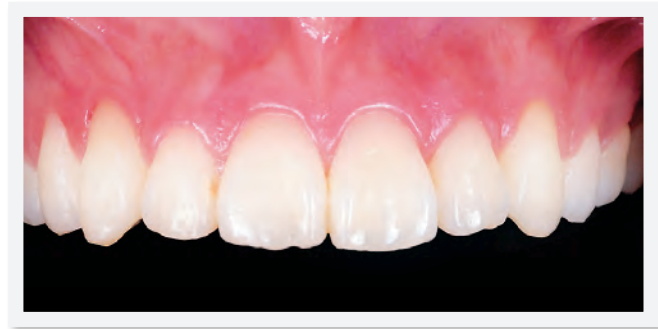
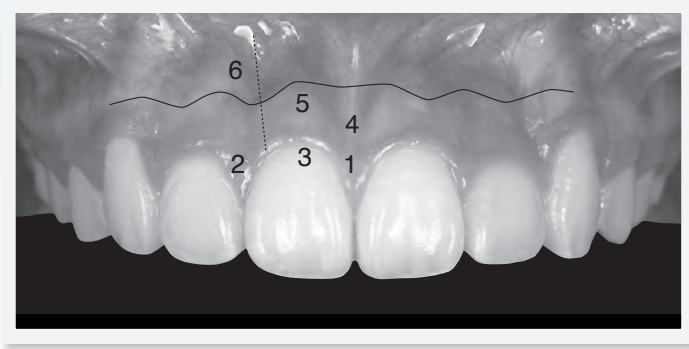
INSTRUCTIONS: Place score beside each deficient tooth and enter total score for each parameter in the white box. Mark extracted teeth with "X". Second molars should be in occlusion.

IBOI Pink & White Esthetic Score (Before Surgical Crown Lengthening)

Total Score: = 5

1. Pink Esthetic Score

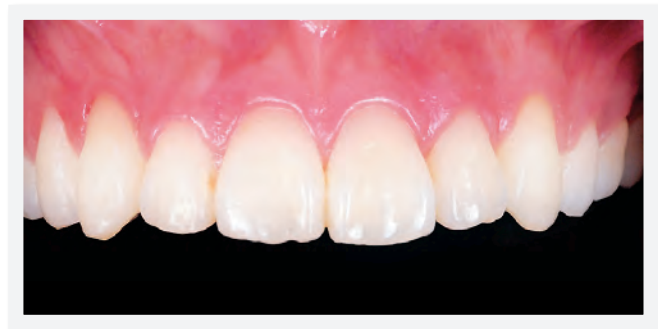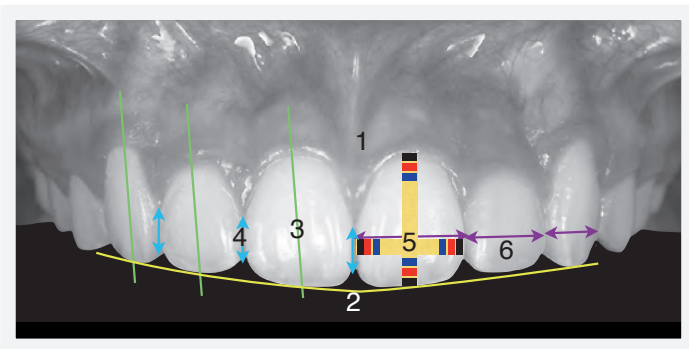


1. Mesial Papilla	0	1	2
2. Distal Papilla	0	1	2
3. Curvature of Gingival Margin	0	1	2
4. Level of Gingival Margin	0	1	2
5. Root Convexity (Torque)	0	1	2
6. Scar Formation	0	1	2

Total = 2

1. M & D Papilla	0	1	2
2. Keratinized Gingiva	0	1	2
3. Curvature of Gingival Margin	0	1	2
4. Level of Gingival Margin	0	1	2
5. Root Convexity (Torque)	0	1	2
6. Scar Formation	0	1	2

2. White Esthetic Score (for Micro-esthetics)



1. Midline	0	1	2
2. Incisor Curve	0	1	2
3. Axial Inclination (5°, 8°, 10°)	0	1	2
4. Contact Area (50%, 40%, 30%)	0	1	2
5. Tooth Proportion (1:0.8)	0	1	2
6. Tooth to Tooth Proportion	0	1	2



Total = 3

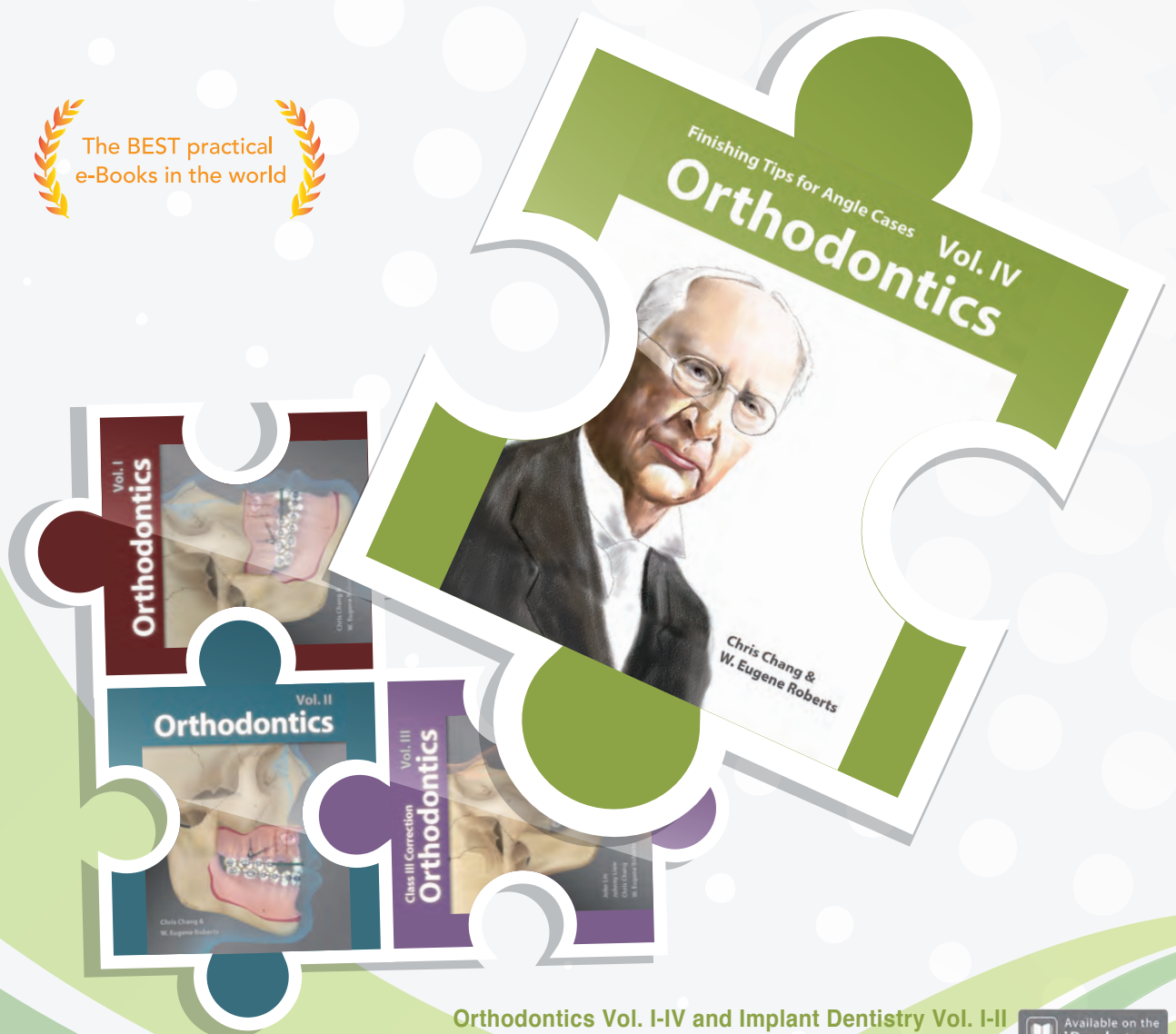
1. Midline	0	1	2
2. Incisor Curve	0	1	2
3. Axial Inclination (5°, 8°, 10°)	0	1	2
4. Contact Area (50%, 40%, 30%)	0	1	2
5. Tooth Proportion (1:0.8)	0	1	2
6. Tooth to Tooth Proportion	0	1	2

Beethoven 3D eBooks

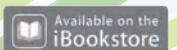
Orthodontics Vol. IV

Chris Chang's Angle Case Reports is a collection of cases submitted for the entrance examination into one of the most prestigious orthodontic group in the world, the Angle Society. This iBook collection documented step by step from start to finish with 3D dental casts, photographs, radiographs, treatment tips and video presentations to enhance the learning experience. Original reviewers' remarks are also included as reference guides on treatment quality. In addition, it includes Chang's recent study on the effect of buccal shelf screws. The preface also provides a fascinating account of Dr. Angle's history by Dr. Eugene Roberts. Written with a clinical focus, Angle Case Reports is recommended for practitioners to improve treatment quality and/or to prepare for board certification.

 The BEST practical e-Books in the world 



Orthodontics Vol. I-IV and Implant Dentistry Vol. I-II are now available on **iBooks Store** in total **52 countries**:



Argentina, Australia, Austria, Belgium, Bolivia, Brazil, Bulgaria, Canada, Chile, China, Colombia, Costa Rica, Cyprus, Czech Republic, Denmark, Dominican Republic, Ecuador, El Salvador, Estonia, Finland, France, Germany, Greece, Guatemala, Honduras, Hungary, Ireland, Italy, Japan, Latvia, Lithuania, Luxembourg, Malta, Mexico, Netherlands, New Zealand, Nicaragua, Norway, Panama, Paraguay, Peru, Poland, Portugal, Romania, Slovakia, Slovenia, Spain, Sweden, Switzerland, United Kingdom, United States, and Venezuela.

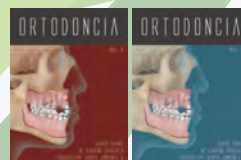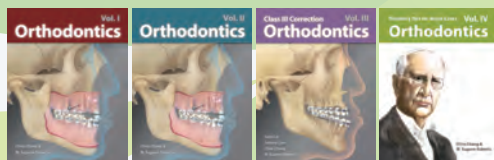
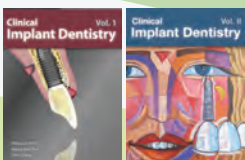
[Implant Dentistry Series]

[Orthodontics Series]

[English]

[Español]

[简体中文]



自2015/10/1 - 12/25止

超值選·輕鬆配

Archwires 「任意搭」買 10 送 6
再送 Ortho Solo + Enlight

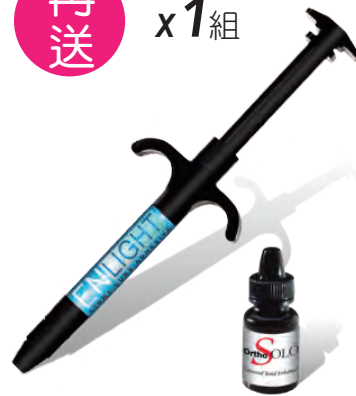買 x10 盒



送 x6 盒



再送 x1 組



(Wire 可任意選搭配 SS除外，照定價購買，以價高者計價)

衛署醫器輸壹字第 010513 / 006857 號
衛署醫器輸字第 010924 / 010954 號

矯正好幫手

傳統矯正器 85折 購買金額滿 12 萬
(Mini 2000、Mini Diamond、Mini-Wick...)

再送 Microetcher IIA x 1 支
新一代噴砂機 (不含安裝費\$1,200)



滿額贈

傳統矯正器 85折 購買金額滿 20 萬
(Mini 2000、Mini Diamond、Mini-Wick...)

再送 Microetcher IIA x 1 支 新一代噴砂機 (不含安裝費\$1,200)

+
MacroCab Dust Cabinet x 1 台 大型集塵器



滿額贈

衛署醫器輸壹字第 010432 號
衛署醫器輸字第 020883 號

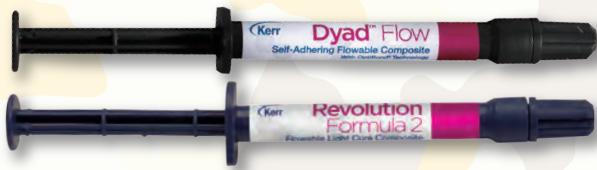- 本文宣品僅供牙科診所及牙醫師參考，禁止張貼或擺置於公眾可瀏覽及取閱之處
- 本優惠專案僅適用於牙醫診所，本公司保留贈品更換之權利，本公司保留更改及終止活動辦法與條款之權利

總代理 湧傑 YONG CHIEH 訂購專線：北區 (02)2778-8315 · 中區 (04)2305-8915 · 南區 (07)226-0030

Composites

樹脂 | 超值選 · 輕鬆配

Flowable Composites



Universal Composites



(Unidose包裝以4g為一單位)

Composites 買3贈1

(樹脂可任選搭配，依照定價購買，以價高者計)

Composites 買10贈6

(樹脂可任選搭配，依照定價購買，以價高者計)

10+6 加贈



Contact Matrix
白齒補牙鐵環套組 / 1盒

Take 1 Advanced 印模材暢銷組



特價NT\$
6,000

Cartridge (50mlx2) 1盒
槍型印模材(Wash / Bite)

Volume (380mlx2) 1盒
機用型印模材(Medium / Tray)

特別加碼

買 + x 5組

NT\$25,000 加購

Volume Mixer
印模材攪拌機 / 1台



買 Maxcem Elite (net wt 10g) X 5 盒
三合一多功能樹脂黏著劑

特價NT\$
20,000



X 5 盒

贈 Microetcher IIA x 1 支
新一代噴砂機 (不含安裝費NT\$1,200)



總代理 湧傑 YONG CHIEH 訂購專線：北區 (02)2778-8315 · 中區 (04)2305-8915 · 南區 (07)226-0030

* 本優惠專案僅適用於牙醫診所 * 本公司保留贈品更換之權利 * 本公司保留更改及終止活動辦法與條款之權利

* 本文宣品僅供牙科診所及牙醫師參考，禁止張貼或擺置於公眾可瀏覽及取閱之處

· 衛署醫器輸字第022220號 · 衛署醫器輸字第022166號 · 衛署醫器輸字第010953號 · 衛署醫器輸字第011616號 · 衛署醫器輸壹字第002179號 · 衛署醫器輸字第021479號 · 衛署醫器輸壹字第009056號 · 衛署醫器輸字第019918號 · 衛署醫器輸字第020883號

Simple Mechanics to Upright Horizontally Impacted Molars with Ramus Screws

Abstract

Simplified mechanics are reported for uprighting horizontally impacted mandibular molars with ramus bone screws. A 27-year-old male presented with a chief complaint of food impaction and problematic occlusion of his posterior teeth. The panoramic radiograph revealed multiple impacted molars: both upper third molars, and all lower second and third molars. Orthodontic treatment was indicated to improve occlusal function by aligning the posterior segments. The treatment plan was to extract the upper second molars and lower third molars, then upright the lower second molars, and allow the upper third molars to spontaneously erupt. The deeply impacted lower second molars were uprighted in only ~4 months with superiorly positioned ramus bone screws. (Int J Orthod Implantol;40:xx-xx)

Key words:

Horizontally impacted second molars, molar uprighting, ramus bone screws

Introduction

Impaction risk is greatest for mandibular and maxillary third molars, followed by maxillary canines and mandibular second molars.¹ Depending on the sample, the prevalence of impacted second molars is up to 2.3%.^{2,3} The etiology of impaction may be ectopic position of the third molar, obstacles in the eruption path, and failure of the tooth eruption mechanism.⁴ This case report demonstrates simple mechanics for managing horizontally impacted second molars in ~4 months. Detailed, step by step procedures are reported.

Case Report

A 27-year-old male presented with bilaterally deeply impacted lower second molars, and a mesially tipped lower left third molar. The other third molars were impacted (Fig. 1).

Treatment Plan Options

Upper Arch

1. No treatment is not a viable option because it fails to address the functional problems, and the impacted third molars may result in root resorption of the adjacent second molars, as well as cyst formation and/or referred pain.⁵
2. Extract the impacted third molars and align the second molars. It may be difficult to extract the third molars without damaging the second molars. Furthermore the extraction site may heal with a soft tissue defect on the distal of the second molars.
3. Remove the second molars and allow for spontaneous eruption of the third molars. After spontaneous eruption of the thirds molars, the buccal segments can be aligned with fixed appliances. Extraction of the erupted second

Dr. Shih-Yung Lin,
IBOI Diplomate (Left)

Dr. Chris Chang,
Founder, Beethoven Orthodontic Center
Publisher, *International Journal of Orthodontics & Implantology* (middle)

W. Eugene Roberts,
Consultant, *International Journal of Orthodontics & Implantology* (right)



molars presents less surgical risk than removing the impacted third molars.

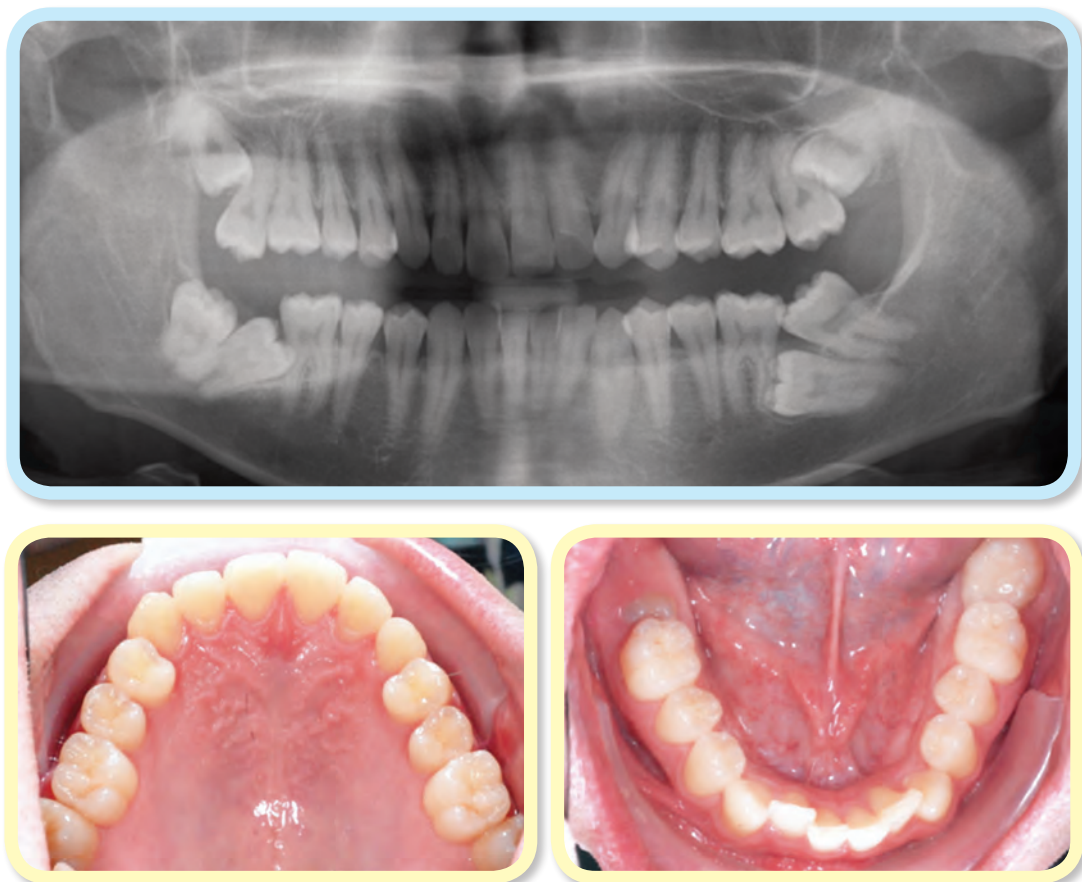Lower Arch

1. Remove all second and third molars, place a subperiosteal membrane for guided bone regeneration, and place implants to restore the second molars. The major concern with this option is the possibility of the inferior alveolar

nerve injury during the extraction process, and healing of the surgical site is unpredictable.

2. Remove the impacted third molars, and then upright the second molars with elastic chains anchored by bone screws placed in the ramus, bilaterally.

After careful discussion of the options with the patient, the decision was made to extract the upper



■ Fig. 1: Pre-treatment panoramic radiograph (above) and occlusal intra-oral photographs (below) document the malocclusion.

second molars and the lower third molars (Fig. 2), and place bilateral ramus bone screws (Fig. 3). Attachments were bonded on the distal surface of each second molar (Fig. 4).

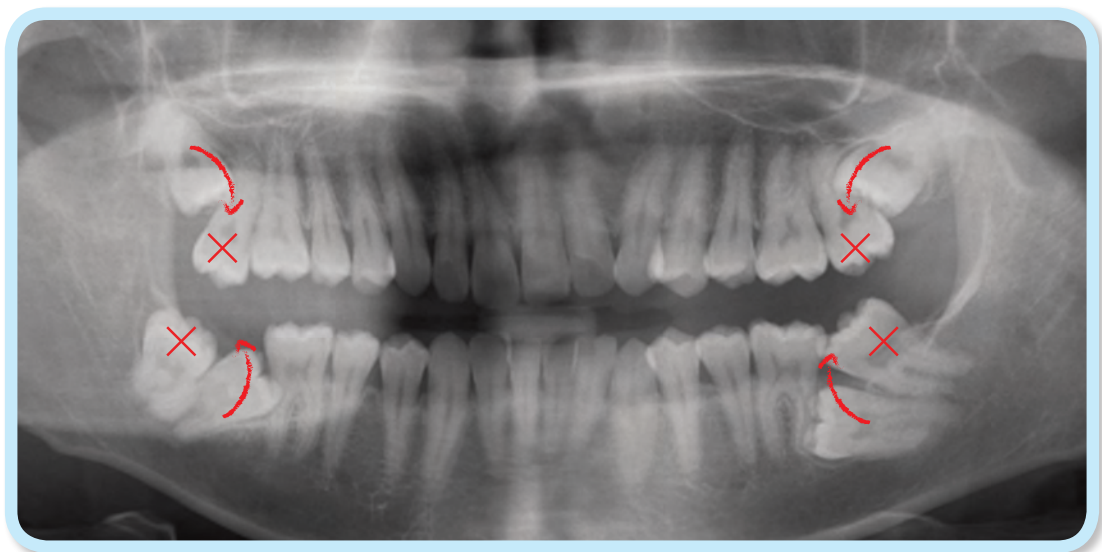
Surgical Procedures

Under local anesthesia, bone screws (2x14mm stainless steel) were inserted in the ramus of the mandible bilaterally (Fig. 4). Then, the upper second and lower third molars were extracted, followed by surgical exposure of the lower second molars. An explorer was used to locate the crowns of impactions. Teeth are smooth and hard, while bone is crunchy and irregular.

Bone superior to the lower second molar crowns was removed down to the level of the cemento-enamel

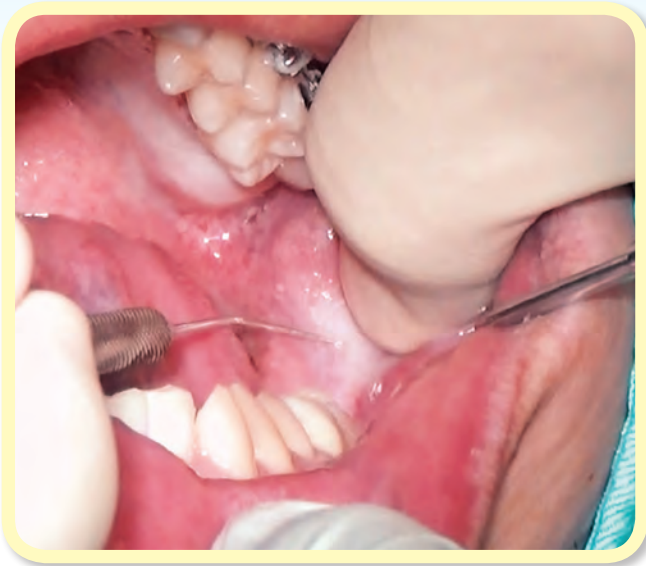junction (CEJ) with a high-speed handpiece. The second molars were surgically luxated to rule out ankylosis. A button was bonded on the distal surface of the lower right second molar, and an eyelet was bonded on the left second molar (Fig. 4).

Elastic chains, anchored by the bone screws, were activated by connecting the opposite end of chain to the attachments bonded on the second molars (Fig. 5). A resin ball was applied to the bone screw head to prevent the elastic chains from being displaced (Fig. 4). To control bleeding, the soft tissue wound was closed with interrupted sutures which were removed after one week. Four months later the second molars were uprighted successfully and routine brackets were bonded on the buccal surface at five months into treatment (Fig. 5).

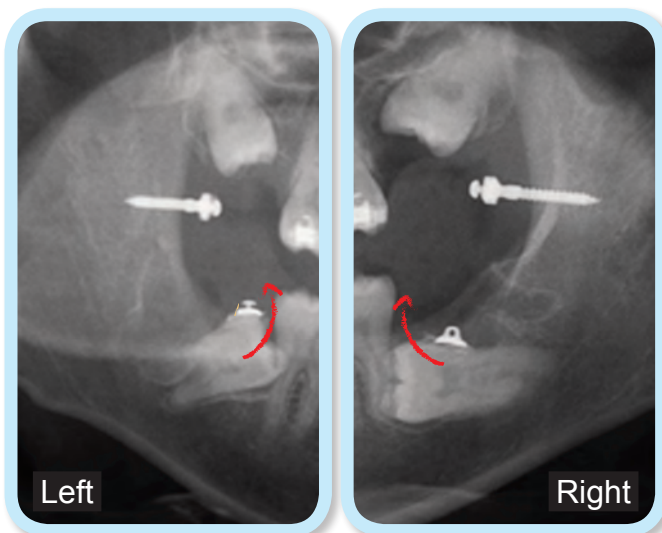


■ Fig. 2:

The treatment plan was to extract the molars marked with an X, upright the lower second molars, and allow the upper third molars to erupt.



■ **Fig. 3:**
Under local anesthesia, the insertion site on the left ramus is marked with an explorer by penetrating the soft tissue to the bone.



■ **Fig. 4:**
The right and left ramus areas are shown in segments of a postoperative panoramic film taken immediately after surgery. A button was bonded on the right side and an eyelet was used on the left side.

Discussion

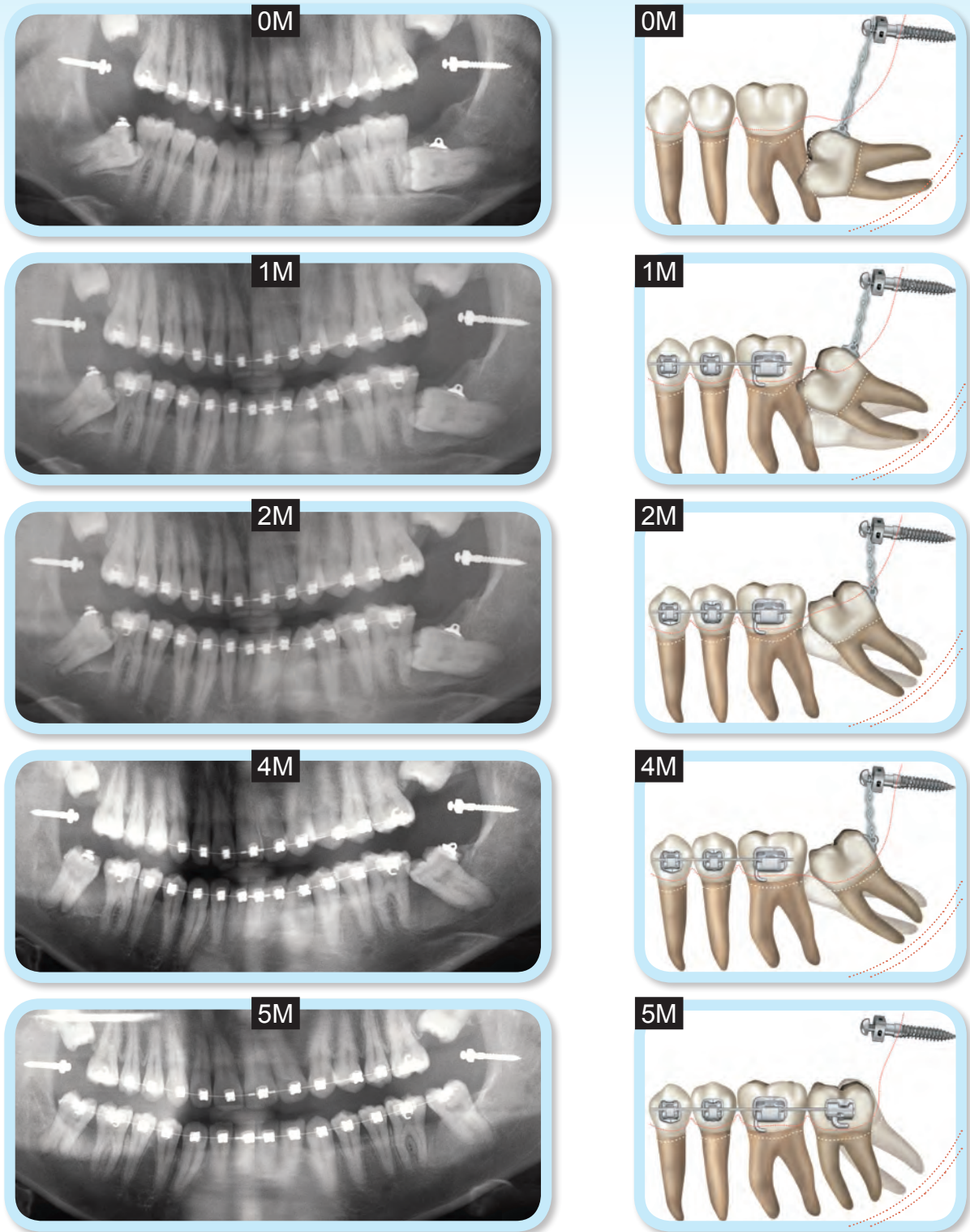
Deciding between extraction or uprighting for impacted teeth is a critical aspect of treatment planning. Factors affecting the decision are severity of the impaction, its position relative to critical anatomical structures (*inferior alveolar nerve and lingual artery etc.*), pre-existing conditions of impacted teeth (*caries, root dilaceration, periodontal health etc.*), and difficulty of the extraction surgery (Fig. 6). If orthodontics is indicated, an efficient mechanics plan is required.

Many methods of uprighting molars have been proposed in the literature.⁶ The mechanical design presented here is simple, effective and expedient. There are two essential tips to ensure routine success with the proposed method.

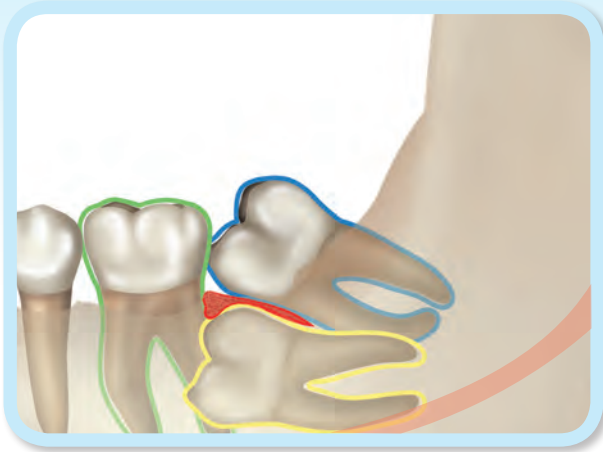
Tips 1. Remove all obstructions to eruption, such as ectopic position of the dental follicle, teeth or pathology in the path of eruption, and failure of the tooth eruption mechanism.⁷ For the present patient, the suspected etiology involves the following (Fig. 6):

- a. impacted third molar putting pressure on the second molar
- b. thick cortical bone blocking the eruption of the second molar
- c. ankylosis of the second molar, and/or
- d. ectopic eruption of the second molar to engage the undercut on the distal of the first molar.

For predictable uprighting and alignment of the second molars, all of the potential etiologic factors



■ Fig. 5: On the left, a series of panoramic films document tooth positions immediately after surgery (0m), then at 1 (1m), 2 (2m), 4 (4m) and 5 months (5m) later. Corresponding drawings documenting the mechanics are shown on the right.



■ Fig. 6:

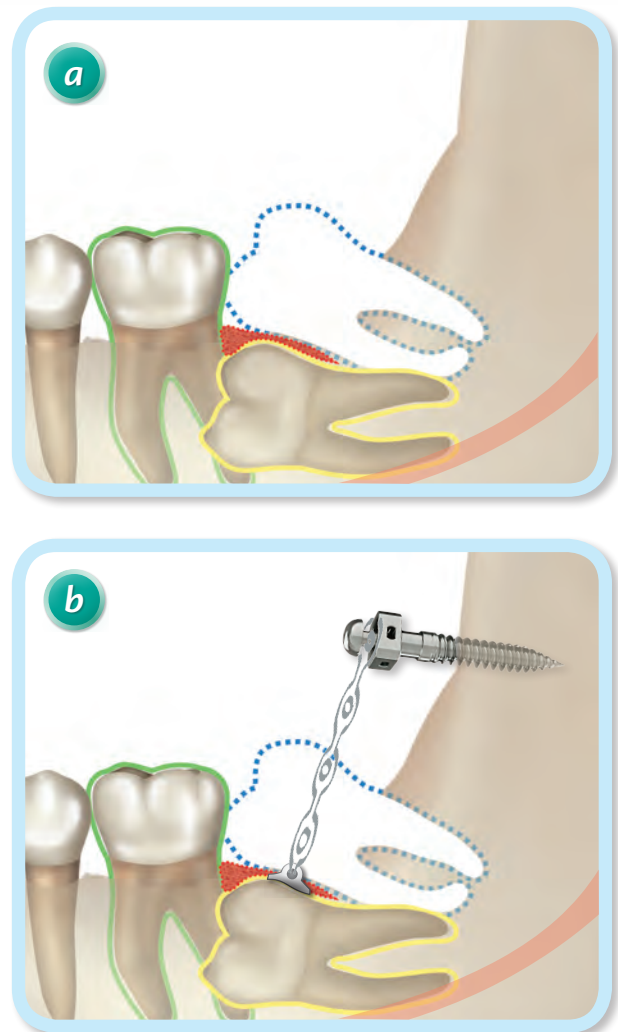
The etiology for an impacted second molar may be a superiorly positioned third molar (blue), dense bone blocking eruption (red), ankylosis of the second molar (yellow), and the undercut of the adjacent first molar (green). The inferior alveolar canal (pink) is very close to the root of the impacted second molar.

were addressed by extracting the third molars and gently luxating the second molars (Fig. 7).

Tips 2. Design an efficient force system for uprighting the impacted teeth.^{8,9} Uprighting a deep horizontal impaction requires occlusal and distal components of force to unlock the impaction from its position against the first molar root. It is wise to avoid bonding a bracket on the first molar until the second molar is at least partially uprighted. This will allow the first molar to move out of the way to help avoid root resorption. Miniscrews can provide favorable anchorage without side effects on the dentition. The dense cortical bone in the ramus is a good site to insert the screw (Fig. 7).

Furthermore, there are several considerations in selecting bonding devices and bonding sites. The most popular bondable attachments for uprighting molars are buttons or eyelets (Fig. 8).

An eyelet is more versatile, but it more difficult to use, compared to a button. In deciding between the two options, the first concern is the line of force. Buttons are well designed for horizontal traction (Fig. 8), but elastic chains are more easily



■ Fig. 7:

- After extraction of the lower third molar (blue), the covering bone (red) was removed with a high-speed handpiece.
- The ramus screw was inserted into the ascending ramus, and an elastic (power) chain with a line of force occlusal to the center of resistance was used to upright the horizontally impacted second molar.

Notice that the adjacent first molar was not bonded and remained "free" until the impacted second was uprighted.

displaced as the direction of traction assumes a more vertical orientation. The second consideration is the convenience of placing and replacing the elastic chains. An eyelet is easily bonded on a tooth with the elastic attached, but a button is

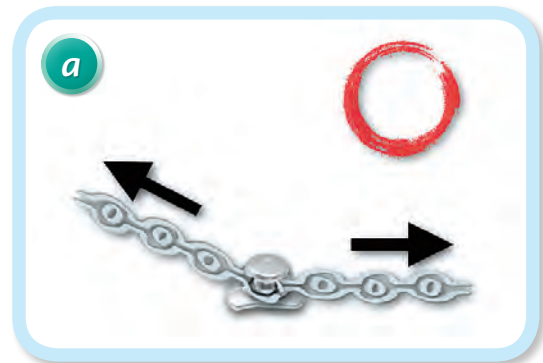
more convenient if the elastic must be changed (Table 1). If the attachment is bonded on the surface of the erupted tooth, and the angle of traction is appropriate (Fig. 9), a button may be the preferred choice. However, if the attachment is bonded on the surface of an unerupted tooth, an eyelet is preferable because there is less chance that the elastic chain will come loose. Flowable resin can be polymerized to secure the elastic chain on either type of attachment.

	Button	Eyelet
Traction direction	Parallel / Slightly angular	Any direction
Replacing elastic	Simple and easy	More complex
Method of operation	Difficult	Easy

■ Table 1: Bondable attachments, buttons and eyelets, are compared relative to clinical efficiency.



■ Fig. 8: Bondable button (above) and eyelet (below) attachments are fitted with elastic chains.

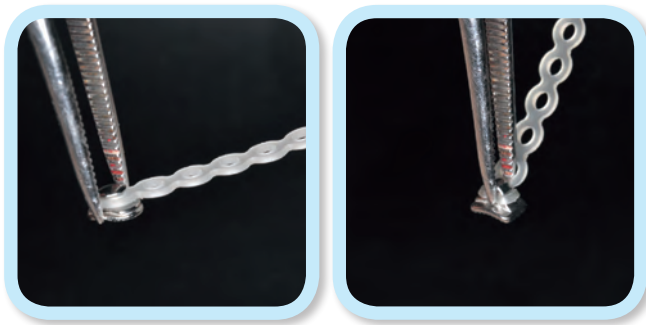

■ Fig. 9:

Safe angle: when the elastic chains are attached at an obtuse angle there is a low probability that they will be displaced from the button.

Non-safe angle: when elastic chains are attached with an acute angle, there is a high probability that they will slip off the button during normal occlusal function.

An additional determinant is the convenience when holding the device with a hemostat or pliers. A button has a smooth, rounded head so it is more difficult to hold. The flat surfaces of an eyelet are more amenable to holding the button for bonding or any other manipulation (Fig. 10).



■ **Fig. 10:** A button with an elastic chain attached (left) is difficult to hold securely. In contrast, the flat surfaces of an eyelet facilitate securely holding it with a hemostat.

Why Ramus Screws?

An efficient, yet simple mechanism is required to upright deeply impacted or mesially tipped molars. Lin⁶ reviewed six different methods of molar uprighting, and concluded that surgical exposure of the deeply impacted molars, followed by traction with elastic chains anchored by ramus screws, was the most efficient. The bone screw recommended is the same one developed for extra-alveolar anchorage in the maxilla and mandible (Fig. 11).

Why use 2 x 14 mm screws?

Previous studies have demonstrated that 2x12 mm extra-alveolar screws are appropriate for the mandibular buccal shelf area, because the soft tissue thickness is only about 1-3 mm.^{10,11} A 2x12 mm screw can usually provide adequate stability and soft tissue clearance when it is inserted in bone about 5 mm. A



■ **Fig. 11:** A 2x14-mm stainless steel bone screw is designed to be inserted in the ramus as a self-drilling fixture.

ramus screw must penetrate thick movable mucosa, as well as the inferior fibers of the temporalis muscle, so the 2x14 mm screw may be needed to provide adequate osseous stability and soft tissue clearance.

Controlling soft tissue inflammation in the anterior ramus area can be a challenge, and it can lead to screw failure. However, a preliminary study found a failure rate of only 5% for ramus screws, which is lower than for mandibular buccal shelf screws (7.2%).^{10,11} Therefore this simple mechanics design is highly recommend to upright impacted second and third molars.

Summary

Six impacted molars considerably compromised the occlusal function of a 27yr male. Upper second molars and lower third molars were extracted, bilaterally. Each horizontally impacted second molar was uprighted with a chain of elastics, attached to the distal surface of the tooth and anchored with a ramus bone screw.

References

1. Aitasalo K, Lehtinen R, Oksala E. An orthopantomographic study of prevalence of impacted teeth. *Int J Oral Surg* 1972;1:117-20.
2. Catherine KL, Claudia ZYW, Dirk B. Orthodontic uprighting of severely impacted mandibular second molars. *Am J Orthod Dentofacial Orthop* 2013;143:116-24.
3. Bondemark L, Tsiopa J. Prevalence of ectopic eruption, impaction, retention and agenesis of the permanent second molar. *Angle Orthod* 2007;77:773-778.
4. Andreasen JO, Kurol J. The Impacted First and Second Molar. In: Andreasen JO, Petersen JK, Laskin DM, authors. *Textbook and Color Atlas of Tooth Impactions*. Copenhagen:

Munksgaard; 1997. p. 199-208.

5. Camila P, Ana C, Yndira G, Abel C. Failure of eruption of first and second permanent molars. *J Clin Pediatr Dent* 2003;27(3):239-246.
6. Lin JJ. The wisdom of managing wisdom teeth-Part III. Methods of molar uprighting. *Int J Ortho Implantol* 2011;24:4-11.
7. Kokich VG, Mathews DA. Impacted Teeth: Surgical and Orthodontic Considerations. *Am J Orthod Dentofacial orthop* 2011;21:38-49.
8. Hsu YL, Chang CH, Roberts WE. Ortho Bone Screw: The dream screw for next generation's orthodontists. *News & Trends in orthodontics* 2011;23:34-49.
9. Lee MC, Chang CH, Roberts WE. Compensated, Asymmetric Class II Malocclusion with Horizontal Impaction of Mandibular Second Molars. *Int J Ortho Implantol* 2014;33:50-62.
10. Chang CH, Roberts WE. A retrospective study of the extra-alveolar screw placement on buccal shelves. *Int J Orthod Implantol* 2013;32:80-89.
11. Chang CH, Roberts WE. Stability of miniscrews on buccal shelves: a retrospective study of 1680 miniscrew insertions by the same orthodontist. *Int J Orthod Implantol* 2013;30:76-78.



2016 貝多芬高爾夫邀請賽

Beethoven Golf Invitational



宗旨

秉持貝多芬齒顎矯正堅持完美與感動之創院精神，藉由高爾夫運動參與，養成健康運動的習慣，並活絡人際互動，推廣高爾夫運動。

日期

練習賽：2015年12月30日
預賽：2015年12月31日
決賽：2016年元旦

地點

東方日星高爾夫俱樂部

資格

23歲以下，限額100名。

報名

12/11日前向新竹市體育會高爾夫委員會報名。
電話：03-5385155；傳真：03-5380951
email: chunhong@mail.ypu.edu.tw



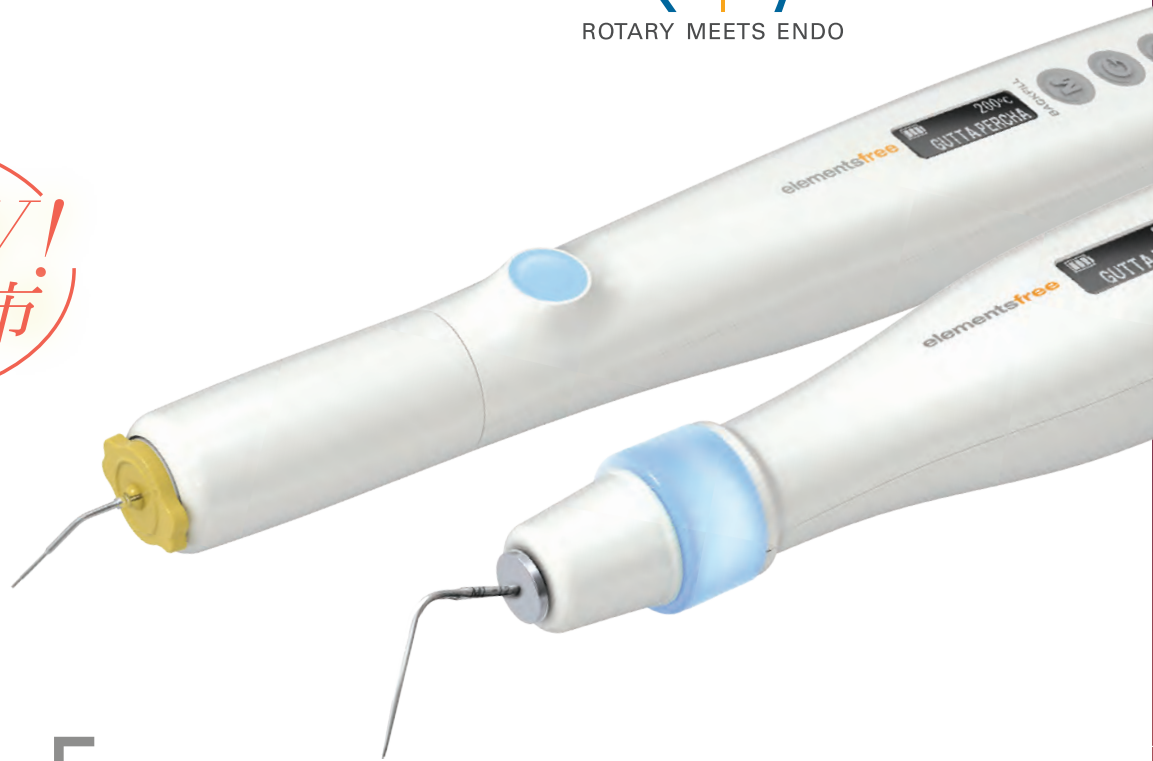主辦單位：貝多芬齒顎矯正中心

承辦單位：新竹市體育會高爾夫委員會

協辦單位：東方日星高爾夫俱樂部、金牛頓藝術科技、安徒生兒童牙醫診所、金牛頓植牙中心、彼德潘兒童青少年牙醫診所


Hsinchu Golf Committee

NEW!
新品上市



elementsfree™ OBTURATION SYSTEM

新品優惠價NT\$148,000/組

自2015/10/1 - 12/25止

買

elementsfree / 1台

含 Heated Plugger .06 / 1支

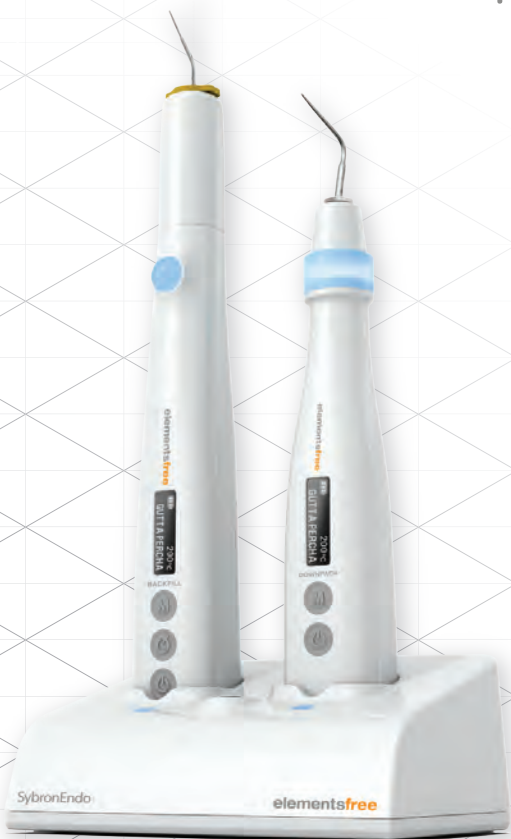23 Gauge Heavy Body G.P Cartridges / 2個

贈

Buchanan 鎳鈦合金手動填壓器械 #1 #2 / 各1支

TFA 馬來膠針 或 TF 馬來膠針 / 任選5盒

子彈型純銀膠針 #23/二盒、#25 / 一盒



總代理 湧傑 YONG CHIEH 訂購專線：北區 (02)2778-8315 · 中區 (04)2305-8915 · 南區 (07)226-0030

* 本優惠專案僅適用於牙醫診所 * 本公司保留贈品更換之權利 * 本公司保留更改及終止活動辦法與條款之權利

* 本文宣品僅供牙科診所及牙醫師參考，禁止張貼或擺置於公眾可瀏覽及取閱之處

· 衛部醫器輸壹字第015275號 · 衛署醫器輸壹字第002755號 · 衛署醫器輸壹字第010742號 · 衛署醫器輸壹字第008363號

Ormco™

Your Practice. Our Priority.



















2015

戴蒙系統鉅作，愛用好評如潮

3大台柱全面回饋

10/1-12/25止

《高CP值好物》Damon 3MX × 《常勝軍推薦》Damon Q × 《指標性美力》Damon Clear

Sale	10人份	20人份	50人份
	<p>贈品</p> <ol style="list-style-type: none"> .014 Damon Copper Ni-Ti 10條 .014x.025 Damon Copper Ni-Ti 10條 .019x.025 Damon Colored TMA-Honeydew 5條 <p>特價NT\$ 90,000</p> 	<p>贈品</p> <ol style="list-style-type: none"> .014 Damon Copper Ni-Ti 20條 .014x.025 Damon Copper Ni-Ti 20條 .019x.025 Damon Colored TMA-Honeydew 10條 D3MX器械 1支 <p>特價NT\$ 180,000</p> 	<p>贈品</p> <ol style="list-style-type: none"> Damon Copper Ni-Ti 100條(任選) Bondable Tube 200顆 (6th四象限各50顆) <p>特價NT\$ 450,000</p> 
	<p>贈品</p> <ol style="list-style-type: none"> .014 Damon Copper Ni-Ti 10條 .014x.025 Damon Copper Ni-Ti 10條 .019x.025 Damon Colored TMA-Honeydew 5條 <p>特價NT\$ 100,000</p> 	<p>贈品</p> <ol style="list-style-type: none"> .014 Damon Copper Ni-Ti 20條 .014x.025 Damon Copper Ni-Ti 20條 .019x.025 Damon Colored TMA-Honeydew 10條 Damon Q 器械 1支 Enlight(光照含氟矯正專用黏著劑) 1支 Ortho Solo(多功能光照黏著基底劑) 1瓶 <p>特價NT\$ 200,000</p> 	<p>贈品</p> <ol style="list-style-type: none"> Damon Copper Ni-Ti 150條(任選) Bondable Tube 120顆 (6th四象限各30顆) <p>特價NT\$ 500,000</p> 
 <p>5+5 3+3 +</p>  <p>54/45</p>	<p>贈品</p> <ol style="list-style-type: none"> .014 Damon Copper Ni-Ti 10條 .014x.025 Damon Copper Ni-Ti 10條 .019x.025 Damon Colored TMA-Honeydew 5條 Enlight(光照含氟矯正專用黏著劑) 1支 <p>特價NT\$ 132,000</p> 	<p>贈品</p> <ol style="list-style-type: none"> .014 Damon Copper Ni-Ti 20條 .014x.025 Damon Copper Ni-Ti 20條 .019x.025 Damon Colored TMA-Honeydew 10條 Enlight(光照含氟矯正專用黏著劑) 1支 Ortho Solo(多功能光照黏著基底劑) 1瓶 <p>特價NT\$ 264,000</p> 	<p>贈品</p> <ol style="list-style-type: none"> Damon Copper Ni-Ti 100條(任選) Clear Debonding Plier 1支 Bondable Tube 40顆 (6th四象限各10顆) .019x.025 Damon Colored TMA-Honeydew 30條 Damon Clear + Q Typodont 1個 <p>特價NT\$ 660,000</p> 
	 <p>SDC ProLign Kit 特價 NT\$ 39,999</p>	 <p>SDC Mini Ortho Kit 加購優惠價 NT\$ 6,500</p>	

湧傑 YONG CHIEH

服務專線：北區 02-27788315 · 中區 04-23058915 · 南區 07-2260030

衛署醫器輸字第 022355 號 衛署醫器輸字第 010954 號 衛署醫器輸字第 010924 號 衛署醫器輸字第 010513 號 衛署醫器輸字第 006858 號 衛署醫器輸字第 006857 號 衛署醫器輸字第 009520 號

* 本文宣品僅供牙科診所及牙醫師參考，禁止張貼或擺置於公眾可瀏覽及取閱之處 * 本優惠專案僅適用於牙醫診所 * 本公司保留贈品更換之權利 * 本公司保留更改及終止活動辦法與條款之權利

In Memoriam: Charles J. Burstone (1928-2015) Burstone Biomechanics: a Living Legacy

Charles Justin Burstone (CJB) is best known for his tenure at the University of Connecticut (UCONN), but the **epicenter for biomechanics** was at Indiana University (IU). CJB contributed substantially to the expression of his passion, and to the subsequent development of the bioengineering group at Indiana University and Purdue University at Indianapolis (IUPUI). Charlie's contributions to orthodontics were profound, and in addition he had broad interests in photography, art and music. He was particularly fond of Wagner's operas.

Family Background: CJB was born April 4, 1928 (*reportedly in Kansas City*) to an Eastern European, immigrant family living in Clayton Township, St. Louis, MO. Dr. Lester Burstone was a Russian dentist, who immigrated from Poland in 1920. He married Rose, an immigrant from Ukraine, who was 13 years his junior. CJB had one older brother, and the family lived over the father's dental office at 6369 Clayton Rd. (*This is <4 miles from the site Angle's First Orthodontia Course in the Olivia Building.*) The senior Dr. Burstone died of an acute MI at the age of 74, but CJB's mother lived to 92. According to CJB, she never understood why "*he did not have a dental office like his father.*" However, like his father, Charlie died of a massive MI, but not until the age 86. The timing of his death fits the online life expectancy for the Burstone name (86.3yr). Charlie would have appreciated that, because he was highly accomplished in statistics, a skill he learned on his own from an IU medical school statistician.

Marvin S. Burstone: CJB's older brother was born in

1922, and graduated with a DDS from Washington University, St. Louis (*Wash U*) in 1946. He specialized in Oral Pathology, and was subsequently appointed to the National Institute of Dental Research (NIDR). Marvin was a brilliant young scientist; he developed the azo-dye coupling reaction for localizing enzymes in histological sections (*histochemistry*). This is the method for in situ detection of alkaline and acid phosphatase in bone sections, in addition to many other applications in dentistry and medicine. Charlie took great pride in the scientific accomplishments of his "*famous*" brother, who died prematurely at the age of 43.

Korea: After earning a DDS in 1950 from Wash U, CJB practiced with his father for a short time, and then entered the US Air Force (1951-53). Deployment to Korea exposed another facet of his unique persona: photo-journalism. Charlie recorded the challenging wartime culture for average Koreans, with both photographs and movies. These historic documents were requested by the Korean government in 2011, to be archived the National Folk Museum. CJB was devoted to Korea and it is fitting that his last lecture was delivered in Seoul, shortly before his death. Charlie died doing what he loved!

The Indiana Years: In 1953, CJB entered the IU Orthodontics Program, chaired by J. William Adams, a former student of Alan Brodie, and a strong Tweed advocate. John Lindquist (*subsequently AAO President and ABO Director*) was the other full-time instructor. John was Charlie's research mentor, and remembers him as by far the smartest student in the program:



W. Eugene Roberts,
Consultant,
International Journal of Orthodontics & Implantology

"He not only mastered orthodontics and cephalometrics research, but became proficient in statistics and mechanical engineering." Other famed clinicians also contributed: Morris Stoner, Rolenzo Haynes, and Hudson Kelley. When CJB graduated in 1955, Tweed Philosophy was his clinical foundation, and soft tissue cephalometrics was his Master of Science (MS) thesis, entitled: The Integumental Profile. Below is a 1980 photograph of many of the Indianapolis orthodontists who were instructors or classmates of CJB. The photo was taken by John Lindquist at a birthday party for Dr. J. Willams Adams.



Indiana University orthodontists of the Burstone Era, clockwise from the left: Drs. Morris Stoner, Frank Hapak, Jack Vorhies, Jim Baldwin, J. William Adams (Dept. Chair), and Hudson Kelley. CJB practiced orthodontics in Dr. Kelley's office.

Dr. James Baldwin was a former West Point Cadet with an MS in Physics from Yale. He was a classmate of CJB, in the following IU class (1956). Jim provided the spark for Charlie's career interest in biomechanics: **applying statics and equilibrium**

to orthodontics. They traveled to Purdue-West Lafayette to discuss the new concepts with the mechanical engineering faculty. Their historic presentation on "biomechanics" was at the 1960 meeting of the Midwest Component of the Angle Society (*Chicago*). After that, Jim and Charlie's paths in biomechanics diverged. Jim was content to apply the principles to continuous arch therapy, but Charlie focused on arch segments, and determinate mechanics. CJB's **Segmented Arch Technique** was published in a classic Angle Orthodontist article in 1966. He moved on to UCONN in 1970, but retained a strong commitment to Indiana.

The Roberts Connection

Dr. W. Eugene Roberts (WER) expected to study with Dr. Burstone at Indiana University, but while WER was in military service, CJB moved to UCONN to form a new biomechanics-oriented program in conjunction with Dr. Sam Weinstein. That was a wonderful opportunity for WER to blend training in bone physiology, under Harold Frost and Web Jee, with the biomechanics of Burstone and Weinstein. As a graduate student, WER was amazed with the depth of Dr. Burstone's intellect. He was brilliant, but they did not always agree in biomechanics because CJB was a physicist and WER was a biologist (*bone physiologist*). They had many interesting discussions over the years. WER quickly came to appreciate Dr. Burstone's almost religious fervor for biomechanics, and attempted to pass on that enthusiasm to his students. In addition to a number of students WER trained during a 1974-88 tenure at the University of the Pacific (UOP), there were 11 PhD-

Orthodontics students trained at Indiana University (IU) from 1988-2008. All of the latter group of students completed a PhD at IU, but a couple of them studied orthodontics elsewhere.

As we approach the 2015 Burstone Biomechanics Symposium, October 22-24, in Indianapolis, WER is currently working with two former students (*Dr. Burstone's Grand-Students*), Chris Chang and Rodrigo Viecilli, on a special application of engineering technology (*finite element analysis*) to a study of skeletal Class III correction. In addition to PhD-Orthodontics training, Chris and Rodrigo have training in surgery and engineering, respectively. Collectively, they have helped propel Dr. Burstone's concepts of determinant mechanics, for explaining the retraction and distal rotation of the lower arch to correct skeletal Class III malocclusion.


The Continuing Influence of Dr. Burstone

After graduating from UCONN in 1974, Dr. Burstone and WER had limited interaction, but CJB was always

prepared to guide the careers of his former students. Charlie's telephone calls were never for small talk, he usually had an opportunity available! Sometimes the conversations were a bit cryptic, because he did not want to appear overbearing, but his guidance was usually pretty clear. In late 1987, CJB announced that the Chair was open at IU, and that would be a great opportunity for WER to have increased interaction in engineering. The move from San Francisco was a bit challenging, but indeed IU was just as Charlie predicted. It opened a range of new opportunities to expand the science of orthodontics.

In 2004, Dr. Burstone called WER to tell him about a student he found in Brazil (*Rodrigo Viecilli*), and sight unseen he should admitted to the IU PhD/Orthodontics Program. The instructions were followed and WER was rewarded with an outstanding addition to orthodontic biomechanics community. Rodrigo is now at Loma Linda University and he is working closely with Chris Chang and WER in defining clinical mechanics. All of this is a continuing legacy of Dr. Charles Burstone.

In 2006, Dr. Burstone called to discuss doing "something



significant for biomechanics at IU." After some discussion, he personally endowed, at the level of \$500,000, the **Burstone Biomechanics Symposium** that will meet every two years at IU, forever! This will be a lively forum for the legacy of Dr. Burstone, indefinitely.

Chang-Burstone Art Connection

Dr. Burstone had many occasions to interaction with his Grand-Student Chris Chang. A notable occasion was the 2009 AAO Meeting in Boston, when Chris's wife Shufen photographed three generations of Burstone era orthodontists: Chris Chang, Charles Burstone, Gene Roberts and Jim Baldwin. Dr. Burstone and Dr. Baldwin were classmates who developed the concepts of biomechanics at IU in the 1950s. Dr. Burstone trained Dr. Roberts, and he in turn trained Chris Chang.

Chris was so impressed with the photograph that he had it painted in oil, and the original is on display in the IU Orthodontics Department. A copy of the painting subsequently appeared on the cover of News and Trends in Orthodontics in January, 2011.



After the sudden death of Dr. Burstone in February, a special memoriam was planned for October 22, 2015, in Indianapolis, immediately prior to the Burstone Biomechanics Symposium. Chris Chang, the "Renaissance Man of IU Orthodontics," prepared a sculpture of Dr. Burstone to be cast in bronze. Miniature busts will be presented to the speakers and former students returning for the Burstone Memoriam October 22.

Conclusion

Dr. Charles Burstone introduced many advanced biomechanics concepts that are applicable to almost

all fixed appliance systems: lingual arch, transpalatal arch, intrusive base arch, T-loops, auxiliary segments etc. The bottom-line was he preferred **statically determinate systems**: "the orthodontist and not the wire should do the thinking." Since much of modern orthodontics emanated with Edward Angle in St. Louis, it is interesting that Dr. Burstone was raised within 4 miles of the original Angle school. Building on the mechanical intuition of Edward Angle, Charles Burstone provided a **scientific** rationale for the biomechanics of our specialty. A quote from his classmate Jim Baldwin was quite telling: "I can't believe he died. He was younger than me. I thought he would go on forever. I guess life is a **finite element**."

Epilogue

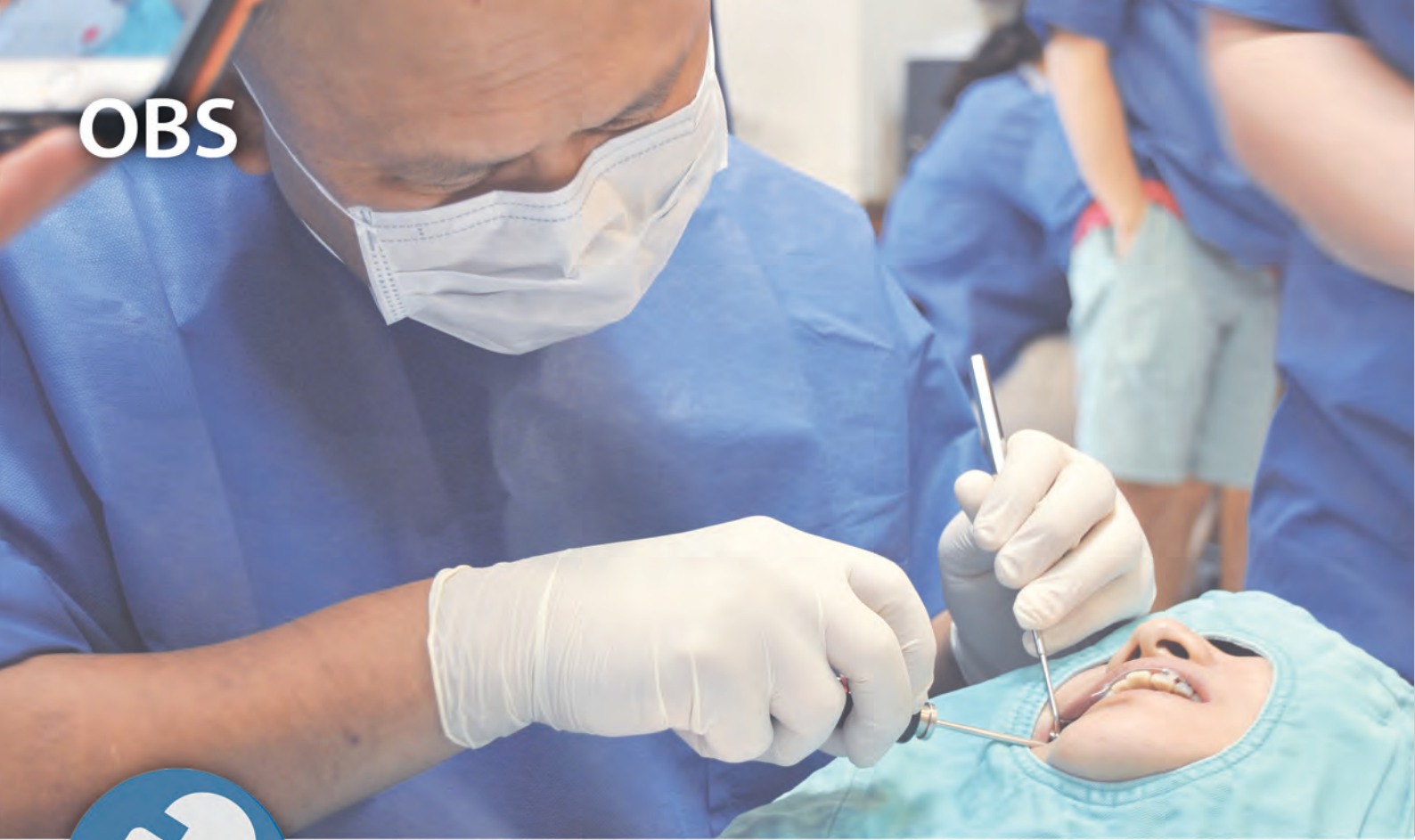It is unfortunate that Dr. Burstone is no longer with us to enjoy the progression of the innovative biomechanics of orthodontics and dentofacial orthopedics. The extra-alveolar (E-A) anchorage concepts, developed by Dr. Chang and his colleagues in Taiwan, are a prominent example of the expanding capacity to treat complex malocclusions conservatively. Indeed, the Burstone Biomechanics Legacy marches on!

Respectfully submitted,

W. Eugene (Gene) Roberts, DDS, PhD
 Professor Emeritus of Orthodontics
 Adj. Professor Mechanical Engineering
 Indiana University & Purdue University
 Indianapolis, IN 46236
 werobert@iu.edu



OBS



OrthoBoneScrew Super Set

Created by Dr. Chris Chang, OrthoBoneScrew(OBS) is made of medical grade, stainless steel and is highly praised by doctors for its simplistic design, low failure rate and excellent quality. Beethoven's OBS super set is your must-have secret weapon to provide a consistent traction force in a minimally invasive approach.



Smooth Mushroom Head

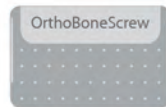
For comfort & retention of elastic chain

4-way Rectangular Holes

For lever arm to solve impacted tooth

Double Neck Design

Easy hygiene control & extra attachment



Screw Type	1.5	1.5x8mm
	2.0	2.0x12mm
	2.7	2.0x14mm with holes



Chris Chang

Founder and Inventor

Newton's A

E-mail: info@newtonsa.com.tw
<http://www.orthobonescrew.com>

Products

Dental Products Essential Kit



Double Retractors

Double Retractors x2, Black Board x2

The double-end design creates an extended handle and allows for firm grasp. The new and improved material is more durable and resilient. The light shape provides the most esthetic aid in intra-oral photography.



Stainless Steel Mirror

Size : L (Recommended), M, S

Strong, durable stainless steel, autoclave-proof, the specially designed size, shape and thickness ensure maximum intra-oral view without sacrificing patient comfort.



Bite Turbo 2.0

Handle x1, BT molds x6, BT longer molds x6, Button molds x6

A simple but power set of tools to correct severe deep bite and cross efficiently. The bite turbos and lingual button molds, made with silicon and filled with flowable resin, can be reused and adjusted depending on treatment progress. The longer one allows you to solve all kinds of deep bite and large horizontal overjet.

2015

DAMON

Study Club

@高雄

STUDY CLUB 訊息 / 講師

STUDY CLUB 內容簡介

主辦單位 高屏澎五校校友聯誼會
臺灣楓城牙醫學會
高醫牙醫南區校友會
中山牙醫高屏澎區校友會

協辦單位 湧傑企業股份有限公司

時間 週三晚上 22:00 pm - 24:00 pm

日期 11/25 <Dr 賴宜姍>
12/30 <Dr 張銘津、張金山>

地點 高雄市三民區九如一路720號
國立科學工藝博物館 103教室

報名 請先電話報名 07-2260030 Ms王
費用每堂500元、一次報名二堂700元

學分 含學分證明每堂2學分，共4學分

賴宜姍

台北醫學大學牙醫學系畢業
四川大學華西口腔醫學院種植學博士
台灣植牙醫學會監事、專科醫師
中華民國顎咬合學會理事、專科醫師
新北市牙醫師公會理事

張銘津

中山醫學大學學士
加拿大英屬哥倫比亞大學進修
美國波士頓大學進修
中山醫學大學醫師、林口長庚醫師
家庭牙醫診所醫師
貝多芬矯正中心醫師

張金山

國立成功大學口腔醫學研究所臨床組碩士
國立成功大學口腔醫學部矯正科 專科訓練
中華民國齒顎矯正學會專科醫師
國立成功大學口腔醫學部矯正科兼任主治醫師
台南家庭牙醫診所齒顎矯正主治醫師

11/25 賴宜姍

DSD的運用

Digital smile design最近在全球造成一股風潮，它有什麼魅力呢？我們利用DSD來模擬矯正治療結果，進行科際間合作，也可以利用DSD和技術支援人員溝通。預作事前準備，與病人先前的溝通進而得到認同，增進醫病關係，是世界潮流新趨勢。

12/30 張銘津，張金山

對GP醫師而言，病人的治療是全方位的，除了一般牙科治療，許多病人有矯正需求，常見除局部intrusion、uprighting、缺牙空間再分配，還有全口治療。看似簡單的案例，臨床上有哪些流程或細節該遵守，可以讓治療快速上手更順利，又有哪些常見錯誤該避免，以免不良副作用讓治療變複雜。本次報告將藉由幾個案例，分享如何讓治療更有效率的Tips，臨床上常見的錯誤及如何修正。

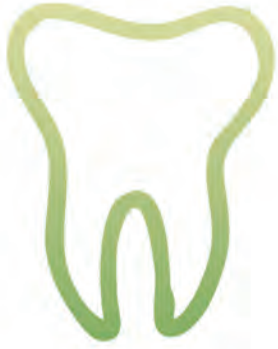Video App

BDE

Beethoven Dental Encyclopedia

The most completed dentist database in the world

BDE offers professional orthodontic and implant video courses. Members can watch the latest dentistry treatment from the comfort of their home. All courses are instructed by Dr. Chris Chang. This step-by-step practical course will make your learning an informative and fun experience. You can also have access to International Journal of Orthodontics and Implantology from the App.



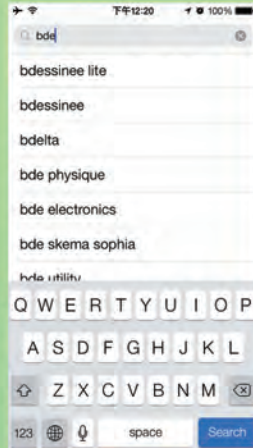
Available on the iPhone
App Store

Go to <http://iaoi.pro>
for more latest videos.

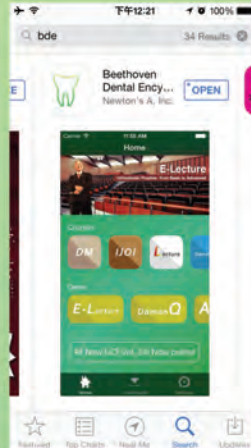E-mail: app@newtonsa.com.tw

TEL : +886-3-5735676

Newton's A



1. Go to App Store, search for "BDE" and install the app.

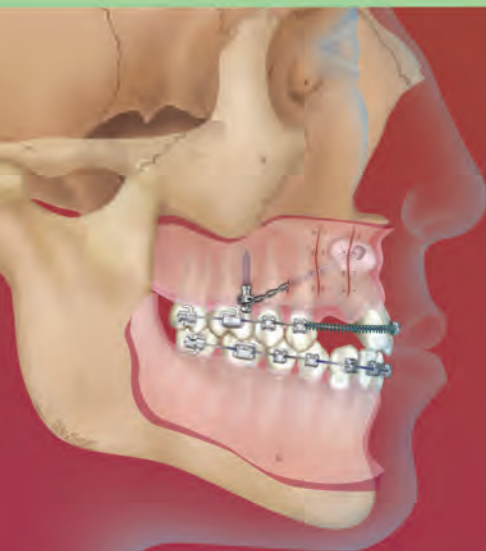

2. Launch the app and enjoy the videos!

With your personal account, you can watch the courses (streaming video) online on your iPad and iPhone without occupying your storage.

You can also download the video to your iPad and iPhone. This allows you to watch your saved files anywhere anytime.

BDE



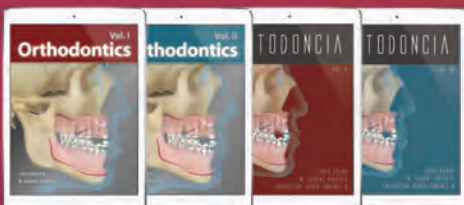The world's best

Dental e-Textbook

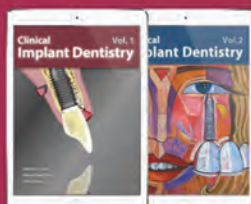
Made by iBooks Author

e-Book

Beethoven Orthodontic and Implant Group has published the International Journal of Orthodontics and Implantology since 2007. This Journal features excellently finished case reports evaluated by objective grading systems. The Orthodontics and Implant Dentistry eBook series is a special selection of exciting cases with interactive functions and multimedia resource. Once opening this book, your understanding of dentistry will never be the same!



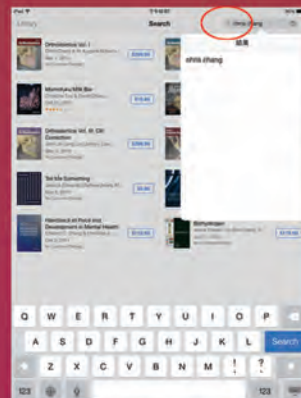
Orthodontics Series



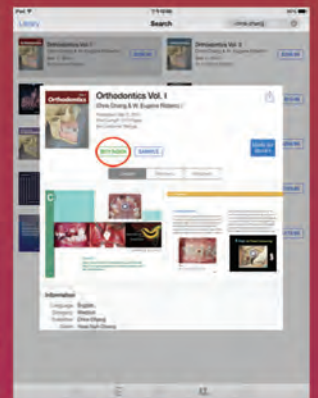Implant Dentistry Series

Available on the
iBookstore

chris chang



1. Search for "chris chang" in iBookstore.



2. Check the price and click "BUY BOOK."



Chris Chang, DDS, PhD

Learn fast,

Save big!

Ortho combo

- Damon Q
- Advanced
- OrthoBoneScrew

-Excellent Finishing

From beginners to advanced clinicians, Dr. Chris Chang will share everything you need to know about the combined use of the latest Damon system and orthodontic bone screws in just 78 sessions.

Voiced version in Chinese

E-Clinic combo

- E-consultation:
Ortho, Pedo, Implant
- Assistant

Want to stand out in the fierce competition of private practice? The combo features the assistant training program you always dream of as well as informative patient consultation materials. All is ready to be used in your clinic today!

Voiced version in Chinese

NEW

Implant combo

- Implant Forum
(Voiced in Chinese)

44 sessions of clinical discussions on the most current and practical topics in implant dentistry, facilitated by Dr. Chris Chang.

Voiced version in Chinese Only

Awesome combo O E

Chinese-version combo O E I

Buy O & E get **E-Lecture**
for **Free**

awesome Packages!!

貝多芬牙醫視訊百科全書

Learn anytime,
anywhere!



矯正研習包

由矯正名師張慧男醫師深入淺出的生動教學，讓您在短短78堂課的課程裡，完全掌握結合最新的矯正系統Damon以及矯正骨釘OBS的實用治療秘訣。無論是矯正新手或是想要持續進修的專科醫師都不可錯過！

- 矯正基礎 Damon Q
- 矯正進階 Advanced
- 矯正植體 OrthoBoneScrew

- 矯正精修 Finishing I (Topic 01-11)
- 矯正精修 Finishing II (Topic 12-22)
- 矯正精修 Finishing III (Topic 23-33)
- 矯正精修 Finishing IV (Topic 34-44)
- 矯正精修 Finishing V (Topic 45-55) **New**



植牙精進包

由矯正名師張慧男醫師主持，邀集國內外植牙講師，整理當前植牙的熱門主題，透過55堂課的專題演講和個案分析，讓您在植牙學習之路上不斷精進！

- 植牙論壇 Implant Forum I (Topic 01-11)
- 植牙論壇 Implant Forum II (Topic 12-22)
- 植牙論壇 Implant Forum III (Topic 23-33)
- 植牙論壇 Implant Forum IV (Topic 34-44)
- 植牙論壇 Implant Forum V (Topic 45-55) **New**



awesome packages

診所行銷包

還在苦於不知如何利用科技行銷診所特色？推廣專業服務？透過系統化的助理訓練課程，囊括「矯正」、「植牙」、「兒童牙科」結合三領域的**案例解說**和**衛教示範**，讓您輕鬆運用iPad科技行銷您的專業診所！

- 衛教示範病例 E-consultation: Ortho, Pedo, Implant
- 助理訓練 Assistant **New**



E化病例衛教電子書

終身會員

享好康

凡2008年起
曾購買任一系列貝多芬視訊課程
皆可享有右側優惠

- **免費更新**課程，包含 E-Consultation矯正衛教篇皆有全新有聲檔可供免費更新。
(不含精修VF、植牙論壇VIF)
- **無聲升有聲**：凡單購無聲視訊課程，皆可付些微差額，升級最新有聲課程。
- 免費安裝矯正植牙國際 **電子期刊**
- **iOS系統健檢**

請洽 **金牛頓** (03)573-5676

<http://www.orthobonescrew.com>

Newton's A

新竹市建中一路25號2樓

B-201209 1020-0000

"From this book we can gain a detailed understanding of how to utilize this ABO system for case review and these challenging clinical cases from start to finish."

Dr. John JJ Lin, Taipei, Taiwan

"I'm very excited about it. I hope I can contribute to this e-book in someway."

Dr. Tom Pitts, Reno, Nevada, USA

"A great idea! The future of textbooks will go this way."

Dr. Javier. Prieto, Segovia, Spain

No other book has orthodontic information with the latest techniques in treatment that can be seen in 3D format using iBooks Author. It's by far the best ever.

Dr. Don Drake, South Dakota, USA

"Chris Chang's genius and inspiration challenges all of us in the profession to strive for excellence, as we see him routinely achieve the impossible."

Dr. Ron Bellohusen, New York, USA


This method of learning is quantum leap forward. My students at Oklahoma University will benefit greatly from Chris Chang's genius.

Dr. Mike Steffen, Oklahoma, USA

"Dr. Chris Chang's innovation eBook is at the cutting edge of Orthodontic Technology... very exciting!"

Dr. Doraida Abramowitz, Florida, USA

"Dr. Chang's technique is absolutely amazing and cutting-edge. Anybody who wants to be a top-tiered orthodontist MUST incorporate Dr. Chris Chang's technique into his/her practice." *Robert S Chen, California, USA*



"Dr. Chris Chang's first interactive digital textbook is ground breaking and truly brilliant!"

Dr. John Freeman, California, USA

"Tremendous educational innovation by a great orthodontist, teacher and friend."

Dr. Keyes Townsend Jr, Colorado, USA

"I am awed by your brilliance in simplifying a complex problem."

Dr. Jerry Watanabe, California, USA

"Just brilliant, amazing! Thank you for the contribution."

Dr. Errol Yim, Hawaii, USA

"Beyond incredible! A more effective way of learning."

Dr. James Morrish Jr, Florida, USA



2015 USC Comprehensive surgical and restorative implant training program in Taiwan. Participants took photo with course director, Dr. Homa Zadeh (Center right) and Dr. Chris Chang (Center left).

ISSN 2079-6862



9 772079 686201